

Technical Tips & Tricks for Reconstructive Microsurgery
HOW I DO IT

Urednik

Branislav J. Đerić

Odgovorni urednik

Prof. dr Uroš Šuvaković

Za izdavača

Dragoljub Kojčić

© Zavod za udžbenike, Beograd, 2018.

Ovo delo ne sme se umnožavati, fotokopirati i na bilo koji drugi način reprodukovati, ni u celini ni u delovima, bez pismenog odobrenja izdavača.

M. BUMBAŠIREVIĆ, MD, PHD
A. GEORGESCU, MD, PHD
P. N. SOUCACOS, MD, FACS

Technical Tips & Tricks for Reconstructive Microsurgery HOW I DO IT



Zavod za udžbenike • Beograd

Preface

The history of Microsurgery spans across most of the last century, with vascular end-to-end or end-to-side anastomoses and autogenous vein grafts introduced by Carrel, Guthrie and Eck between 1800 and 1900. It was the introduction of the operating microscope that led to the revolution in microsurgery. Nylen introduced the idea of magnification using a surgical microscope for fine operative procedures in 1921, which was later adopted by Jacobson and Suarez in 1960 for microvascular anastomoses of vessels with a lumen diameter of 1mm. As microsurgical techniques were perfected, a notable increase in success was seen with replantation surgery, artery and nerve repairs.

In the 1970s, microsurgical composite tissue transfer became a reality, with functioning free muscle transfers, vascularized bone grafts, toe-to-hand transfers, and much more. Because of technological advances, as well as a better understanding of the micro-anatomy, reconstructive microsurgery has reached the stage, today, where anastomosis of vessels as small as 0.3mm is feasible. This type of “Supermicrosurgery” is now applied for perforator flaps, complex digital replantations, lymphatic anastomosis, etc. Among the recent milestones in the history of microsurgery has been the advancement of composite tissue allotransplantation. Today, microsurgical technique has become an integral part of orthopaedics, hand surgery, plastic surgery, neurosurgery, as well as most primary surgical disciplines.

The concept of skills, competency and expertise is widely embraced, but poorly defined in surgery. The development of each surgeon’s microsurgical skills is an ongoing process of refining surgical technique based on experience.

This manual is the compilation of experience from a wide number of authors and expert microsurgeons who share technical tips, tricks and pearls of a full gamut of microsurgical methods. These authors are considered mentors in the field. The experience from renowned experts was commissioned from virtually all countries across three continents, and covers a broad scope of subjects, from basic to complex. The principles of evidence-based medicine are reflected by the authors in each guide which describes “How to Do It”.

The Technical Tips & Tricks presented, reflect the need of both young and experienced surgeons to learn from the pearls of wisdom of experience. The style of this manual is to provide information on the means of “how to employ these techniques” in a straightforward manner. The aim is to help surgeons handle the numerous hurdles they face during microsurgical practice. The value of this type of constructive advice and technical tips and tricks is truly great.

We are pleased to present you a collection of technical experience and skills from across the European family of Microsurgeons on various evolving areas in microsurgery. This pioneer effort is intended to be a dynamic effort and will continue as an online instructional manual. As an online manual, “***Technical Tips & Tricks For Microsurgery How I Do It***”, has the benefit of continuous updating of material, addition of adjuvant information, and much more. This will ensure its use as an expert, but practical guide for both the novice and experienced microsurgeons.

EDITORS

M. Bumbaširević, MD, PhD

Professor Orthopedic
Surgery & Traumatology
School of Medicine,
University of Belgrade, Serbia

A. Georgescu, MD, PhD

Professor Plastic Reconstructive
Surgery, University of
Medicine, Luliu Hatieganu,
Cluj Napoca, Romania

P.N. Soucacos, MD, FACS

Professor Orthopaedic Surgery
Orthopaedic Research &
Education Center,
Attikon University Hospital,
National & Kapodistrian
University, School of Medicine
Athens, Greece

CONTRIBUTORS

Akelina Yelena DVM, MS

Director, Microsurgery Training and Research
Laboratory, Dept. of Orthopedic Surgery,
Columbia University, NY, USA

Alper Akasakal İbrahim

IST-EL Hand Surgery, Microsurgery and
Rehabilitation Group, Istanbul, Turkey

Bavelou Aikaterini, MD

University of Patras, School of Medicine,
University Hospital of Patras, Department of
Orthopaedics, Rio-Patras, Greece

Baytinger Vladimir F.

Scientific Research Institute of Microsurgery,
Russian Federation, Tomsk

Beris Alexandros MD

Professor of Orthopaedics, University of Ioannina

Bularda Andreea

Zetta Clinic Bucharest, Romania

Bumbaširević Marko

Orthopedic and Traumatology University Clinic,
Clinical Center of Serbia, Serbia
Faculty of Medicine, University of Belgrade,
Serbia

Colak Ozlem MD

Okmeydani Training and Research Hospital,
Istanbul

Dailiana Zoe MD, PhD

Professor of Orthopaedic Surgery, Medical
School, University of Thessaly, Panepistimiou st.
3, Biopolis 41110, Larissa, Greece

Demiri Efterpi C.

Department of Plastic Surgery, Aristotle
University of Thessaloniki, Papageorgiou
Hospital, Thessaloniki, GREECE

Dionyssiou Dimitrios

Assistant Professor in Plastic Surgery, Aristotle
University of Thessaloniki, Greece

Djambazova Sinolichka

Clinic for Orthopaedic Surgery, Skopje,
Macedonia

Djordjevic Miroslav L. MD

School of Medicine, University of Belgrade,
Serbia

Georgescu Alexandru Valentin

Professor in Plastic Surgery, University of
Medicine Iuliu Hatieganu, Cluj Napoca,
ROMANIA

Gkiatas Ioannis MD

Orthopaedic Department, University Hospital of
Ioannina

Goubier Jean-Noel

Institute of Peripheral Nerve and Brachial Plexus
Surgery, 92 Boulevard de Courcelles, 75017 Paris,
France

Gravvanis Andreas, MD, PhD, FEBOPRAS

General Hospital of Athens "G. Gennimatas"

Hannu Kuokkanen

Helsinki University Hospital

Higuera Carmen

Hospital Universitario Germans Trias i Pujol,
Barcelona

Ignatiadis Ioannis A. MD

Athens Medical Center, Psychico Clinic, Athens,
Greece

Ilkka Kaartinen

Tampere University Hospital, Finland

Juha Kiiski

Tampere University Hospital, Finland

Kabaka Fatih

IST-EL Hand Surgery, Microsurgery and
Rehabilitation Group, Istanbul, Turkey

Ki Sae Hwi

Dept. of Plastic Surgery, Inha University, School
of the Medicine

Kokkalis Zinon T. MD, PhD

University of Patras, School of Medicine,
University Hospital of Patras, Department of
Orthopaedics, Rio-Patras, Greece

Kontogeorgakos Vasileios A. MD, PhD

Assistant Professor of Orthopaedic Surgery,
Department of Orthopaedic Surgery, ATTIKON
University Hospital, Rimini 1, Xaidari, Athens,
Greece
Faculty of Medicine, National and Kapodistrian
University of Athens, Greece

Kostas-Agnantis Ioannis MD

Orthopaedic Department, University Hospital of
Ioannina

Lahiri Amitabha

Department of Hand and Reconstructive
Microsurgery, National University Hospital,
Singapore

Lešić Aleksandar

Orthopedic and Traumatology University Clinic,
Clinical Center of Serbia, Serbia
Faculty of Medicine, University of Belgrade,
Serbia

Matić Sladana

Orthopedic and Traumatology University Clinic,
Clinical Center of Serbia, Serbia
Faculty of Medicine, University of Belgrade,
Serbia

Mavrogenis Andreas F. MD

First Department of Orthopaedics, National
and Kapodistrian University of Athens, Athens,
Greece

Mersa Berkan

IST-EL Hand Surgery, Microsurgery and
Rehabilitation Group, Istanbul, Turkey

Minna Kääriäinen

Tampere University Hospital, Finland

Minna Laitinen

Tampere University Hospital, Finland

Özalp Taçkın

Department of Orthopaedics and Trauma
Surgery, Celal Bayar University, Manisa, Turkey

Özcelik Bülent

IST-EL Hand Surgery, Microsurgery and
Rehabilitation Group, Istanbul, Turkey

Özkaya Ozay MD

Okmeydani Training and Research Hospital,
Istanbul

Palibrk Tomislav

Orthopedic and Traumatology University Clinic,
Clinical Center of Serbia, Serbia
Faculty of Medicine, University of Belgrade,
Serbia

Panagopoulos Georgios MD

Orthopaedic Surgeon, Department of Orthopaedic
Surgery, ATTIKON University Hospital
Rimini 1, Xaidari, Athens, Greece

Papagelopoulos Panayotis J. MD, PhD

Professor of Orthopaedic Surgery, Department
of Orthopaedic Surgery, ATTIKON University
Hospital, Rimini 1, Xaidari, Athens, Greece
Faculty of Medicine, National and Kapodistrian
University of Athens, Greece

Papanikolau George MD, PhD

General Hospital of Athens "G. Gennimatas"

Pürisa Hüsrev

IST-EL Hand Surgery, Microsurgery and
Rehabilitation Group, Istanbul, Turkey

Raspopović Staniša

Sensors Neuroprosthetics, Lausanne, Switzerland

Sassu Paolo MD, PhD

Hand Surgery Department, Sahlgrenska
University Hospital

Selyaninov Konstantin V.

Scientific Research Institute of Microsurgery,
Russian Federation, Tomsk

Sezer İlker

IST-EL Hand Surgery, Microsurgery and
Rehabilitation Group, Istanbul, Turkey

Stamate Teodor

Professor Emeritus, Head of the Department of
Plastic Surgery and Reconstructive Microsurgery
University of Medicine, "Gr.T.Popa" IASI,
Romania

Stavrianos Spiros

Greek Anticancer Institute

Stoian Alexandru

Zetta Clinic Bucharest, Romania

Varitimidis Sokratis E.

Medical School, University of Thessaly, Larissa,
Greece

Soucacos Panayotis N. MD, PhD

First Department of Orthopaedics, National and
Kapodistrian University of Athens, School of
Medicine, Attikon University Hospital, Athens,
Greece

Teboul Frederic

Institute of Peripheral Nerve and Brachial Plexus
Surgery, 92 Boulevard de Courcelles, 75017 Paris,
France

Toni-Karri Pakarinen

Tampere University Hospital, Finland

Yu Peirong, MD, FACS, Professor

Department of Plastic Surgery, MD Anderson
Cancer Center, Houston, TX, USA

Zamfirescu Dragos

Zetta Clinic Bucharest, Romania

Zuker Ronald M. MD, FRCSC, FACS

Plastic and Reconstructive Surgeon, The Hospital
for Sick Children, Toronto, Canada, Professor of
Surgery The University of Toronto

*Authors are listed by
alphabetical order*

Preface	V
1. How I do the interpositional vein graft using rat femoral vessels <i>Akelina Y</i>	1
2. Complications after free transplantation of tissue complexes on microvascular anastomoses and their prophylaxis <i>Baytinger VF, Selianinov KV</i>	5
3. Free vascularized fibula graft for osteonecrosis of the femoral head. How I do it <i>Beris A, Gkiatas I, Kostas-Agnantis I</i>	7
4. Bionic hand – surgical procedure for electrode implantation <i>Bumbaširević M, Raspopović S, Palibrk T, Matić S, Lešić A</i>	11
5. Homodigital neurovascular island flaps for the reconstruction of fingertip injuries in children <i>Dailiana ZH, Kontogeorgakos VA, Varitimidis SE</i>	15
6. Technical tips on the vascularized lymph node transfer combined with fat-augmented latissimus dorsi flap for simultaneous breast and lymphedema reconstruction <i>Demiri EC</i>	21
7. Anatomical functional reconstruction of secondary lymphoedema with the use of vascularized lymph node flap <i>Dionyssiou D</i>	25
8. Dorsal metacarpal arterial flap <i>Djambazova S</i>	31
9. Female to male gender confirmation surgery: How I do it <i>Djordjević ML</i>	37
10. Male to female gender confirmation surgery: How I do it <i>Djordjević ML</i>	43
11. Muscle-rib flaps <i>Georgescu AV</i>	47
12. Operative technique of the transfer of the Rhomboid Nerve to the Suprascapular Nerve <i>Goubier JN, Teboul F</i>	53
13. Free fibular flap – How I do it <i>Gravvanis A, Papanikolaou G</i>	55
14. Use of perforator vessels as recipient vessels in foot reconstruction <i>Higueras-Suñe C</i>	61
15. Reverse flow anastomosis from end arterial arch for middle phalanx amputations of the fingers <i>Ignatiadis IA, Mavrogenis AF</i>	65

16. Technical tips in distal finger replantations	
<i>Kabakas F, Özcelik B, Mersa B, Sezer I, Pürisa H, Akasakal IA, Özalp T</i>	69
17. Harvesting a toenail flap based on the fibro-osseous hiatus branch	
<i>Ki SH</i>	85
18. Reconstruction of the elbow flexion with modified Oberlin procedure	
<i>Kokkalis ZT, Bavelou A, Soucacos PN</i>	87
19. Vascularized fibula grafts in musculoskeletal oncology	
<i>Kontogeorgakos VA, Panagopoulos G, Dailiana Z, Papagelopoulos PJ</i>	93
20. Reconstruction of a massive sacrectomy defect – technical tips	
<i>Kuokkanen H, Kiiski J, Kääriäinen M, Kaartinen I, Pakarinen TK, Laitinen M</i>	103
21. Hepatic artery anastomosis dealing with limited access and difficult orientation	
<i>Amitabha Lahiri</i>	107
22. Tips and tricks for microsurgical face and scalp reconstruction in elderly patients	
<i>Ozkaya O, Çolak O</i>	111
23. Vascularized joint transfer from the foot	
<i>Sassu P</i>	117
24. Technical tricks in upper limb classical nerves grafting according to lesion level and functional prioritization	
<i>Stamate T</i>	123
25. Tips in management of tongue and floor of mouth cancer	
<i>Stavrianos S</i>	137
26. Microsurgical reconstruction of the trachea and esophagus	
<i>Yu P</i>	139
27. Perforator flaps for head and neck reconstruction	
<i>Yu P</i>	143
28. Reconstruction of the mandible and the fibular flap	
<i>Yu P</i>	149
29. Contralateral C7 transfer in total brachial plexus palsy	
<i>Zamfirescu D, Stoian A, Bularda A</i>	153
30. Distal phalanx replantation	
<i>Zamfirescu D, Stoian A, Bularda A, Bordianu A</i>	157
31. Fibular free flap	
<i>Zamfirescu D, Stoian A, Bularda A</i>	161
32. Improving the results of muscle transplantation for facial reanimation	
<i>Zuker R</i>	165

How I do the interpositional vein graft using rat femoral vessels

1

Yelena Akelina, DVM, MS

Director, Microsurgery Training and Research Laboratory
Dept. of Orthopedic Surgery, Columbia University, NY, USA

Microsurgery is a very difficult and demanding surgical skill that requires a lot of instruction and practice. There are many instructional courses in microsurgery around the world and many different microsurgery instructors who lead these courses. All of them have their own technical tips and tricks of the trade that they share with their students to help them acquire such skills with ease.

I would like to share my technical tips for the completion of the interpositional vein graft utilizing the rat femoral artery and two

autologous veins: the femoral and epigastric.

Quite often in clinical practice, especially in trauma and reconstructive surgery, surgeons will be exposed to situations that require bridging a vascular gap with appropriate grafting, and most of the time they will use the autologous vein graft for such procedures. Small caliber vein grafts are proven to have much better patency rates and biocompatibility than any synthetic materials.

In this article I will take you step by step of the exercise we teach how to perform the inter-

positional vein graft for the femoral artery of the rat. Although different veins can be used for this exercise, we will use two autologous veins from our rat model: the femoral and epigastric.

The femoral vein is slightly larger in diameter than the femoral artery. This has two implications: first, it is easier to work with for beginners, and second, it creates a lumen diameter discrepancy, which is a slight issue that we teach how to overcome.

We also use the epigastric vein as it is more similar in diameter to the femoral artery, which omits the discrepancy issue; however, because it is smaller than the femoral vein, the students will need to finesse their skills even further.

We are going to create a defect in the femoral artery and bridge it with the appropriate length vein graft using only two single clamps and a free flowing graft in the middle.

In real clinical OR situation, when surgeons work on larger size vessels and greater gaps, they need to have a double clamp to approximate the artery and vein first on the proximal anastomosis and then on the distal.

We consider this to be an excellent technical exercise that teaches students not only to perform the grafting procedure, but also to pay attention to many small details that are essential for producing a patent graft. It also teaches students to have a step-by-step surgical planning to avoid missing an important phases of the procedure.

IVG using Femoral Vein

Dissection Steps:

1. Have a wide skin exposure and raise the fat pad more laterally to have a wide-open field.
2. Dissect both the femoral artery and vein, ligating and coagulating any small branches

so that you have the greatest length of free vessel possible to work with.

3. Clamp the artery as proximally and as distally as possible, making sure that both clamps are laying down flat.
4. Excise the mid portion of the artery. If the Murphy's branch is on your transection line, cut it out. If the artery retracts less than 5 mm, you can excise 1 mm of tissue from both sides to create a defect approximately 5-10 mm in length.
5. Immediately after cutting, flush all the blood out with heparinized saline and trim the adventitia from the edge to avoid thrombosis formation. Insert the vasodilator forceps into the arterial ends and gently separate the tongs to slightly enlarge the lumen.
6. Using the small ruler, measure the length of the gap between the edges of the artery to determine the exact length of the graft needed to cover that defect.

Preparing the Graft Steps:

When preparing the graft from the femoral vein, there are a few points to remember:

1. The position of the Murphy's branch should be in the middle of the graft and not on the suture line.
2. The distance between the ligatures should be slightly longer (1-2 mm) than the length of the graft.
3. Place marking stiches in the vein adventitia so that you can align the graft in the proper orientation of the valves and blood flow. This means that the graft will need to be reversed when inserted into the artery such that the distal end of the vein is sutured to the proximal end of the artery (upstream to upstream). Leave one marking stitch longer to facilitate keeping track of the proximal end.

3. Ligate both ends of the vein, ensuring you have at least 1 mm more length than the artery defect on each end.
4. Excise the distal end of the vein first, irrigate with heparinized saline, and trim the adventitia before excising the other end, as it is easier to flush and trim with one end still attached.
5. Excise the proximal end of the vein, and take care not to lose the now free-floating graft. It can easily be washed away; therefore, you should place it on the background and keep an eye on it.

Suturing Steps for IVG:

1. Place the first stay suture at 12 o'clock through the proximal end of the artery to the distal end of the vein. With this stitch in place, it is now easier to trim the adventitia from the other end of the vein.
2. Then place the second stay suture at the 12 o'clock in the distal end of the artery to the proximal end of the vein, using the marking stitches to ensure proper alignment with no twisting of the vein.
3. Any diameter discrepancy can be overcome by connecting the third and fourth stay sutures at 6 o'clock on both sides. Leave some length on each stay suture to grasp for easier manipulation of the vessels.
4. Again, make sure that the marking stitches are aligned to ensure that there is no twisting of the vein.
5. Complete the anterior walls on both anastomoses with 3 middle evenly spaced stitches
6. Finally, flip the clamps to complete the posterior walls.
7. Upon completion of both anastomoses, examine the suture lines for any gaps and put any extra sutures as needed.

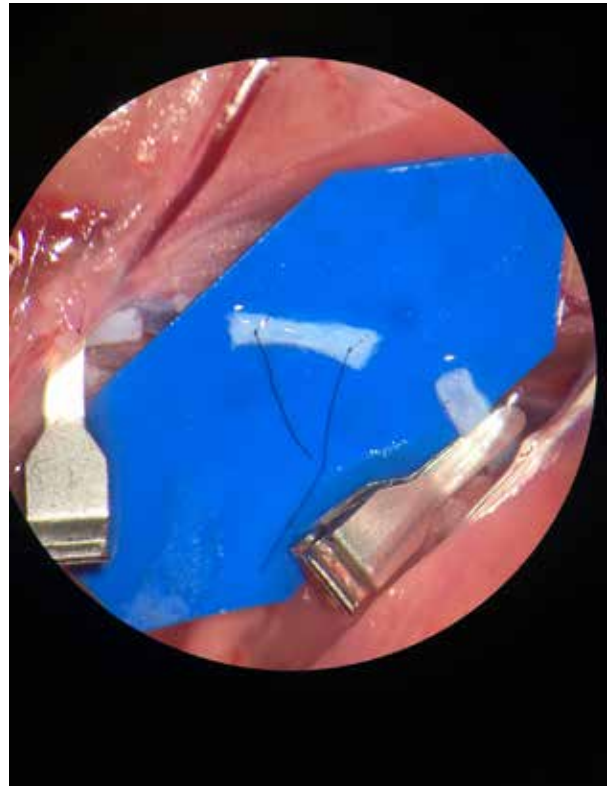


Figure 1: Interpositional vein graft inside the arterial defect

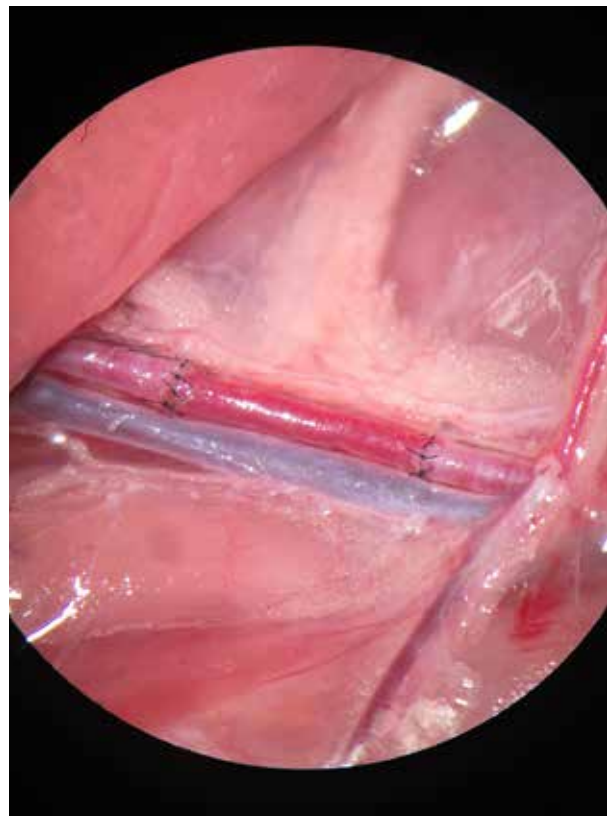


Figure 2: Completed interpositional vein graft

8. Release the distal clamp first and let the retrograde flow open the lumen to show any defects. Then open the proximal clamp. Apply the fat pad for a few minutes for hemostasis and check the patency distally from the distal anastomosis.
9. If there is excessive bleeding, apply a cotton-tipped applicator underneath the anastomosis to partially occlude the vessel to slow down the bleeding and use it as a stage for repair. This technique only works for small vessels and small defects. If there are bigger vessels and greater bleeding you will need to apply single clamps and heparinize the graft. The repair has to be completed quite fast to avoid thrombosis.

IVG using Epigastric Vein

To further develop your skills in grafting, the same exercise can be performed with the

epigastric vein as a graft instead of the femoral vein.

1. Gentle dissection of the epigastric vein from the epigastric artery is required, and a few small branches may be cauterized without ligation.
2. The same technique of placing marking stitches are used and the vein is carefully measured and cut from one side only to irrigate and then cut at the second end.
3. The suturing techniques are the same as those for the femoral vein, and since the diameter of the epigastric vein is very similar to that of the femoral artery, diameter discrepancy should not play a significant role.
4. Gentle handling and using high magnification for every step are crucial while working with the epigastric vein.

We consider the interpositional vein graft exercise to be an excellent training model for future development of basic microsurgical skills for our students.

Complications after free transplantation of tissue complexes on microvascular anastomoses and their prophylaxis

2

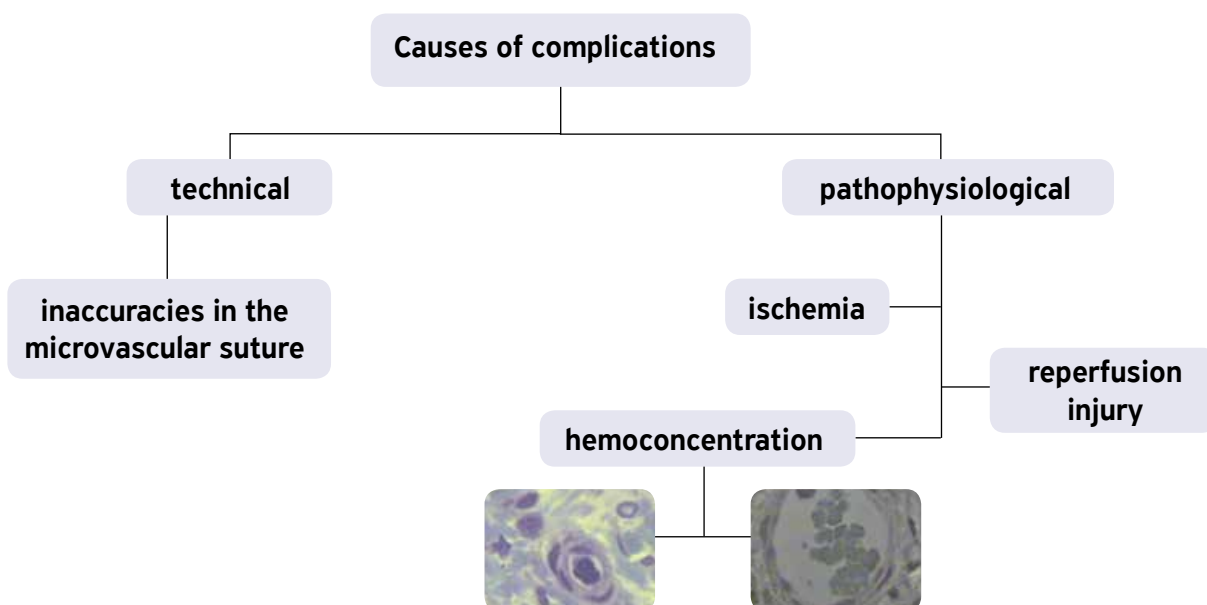
Baytinger V.F, Selianinov K.V.

Scientific Research Institute of Microsurgery, Russian Federation, Tomsk

The complications in the form of ischemic marginal and (or) total necrosis of a free flap are violations of its capillary perfusion against a technically correct or incorrectly performed microsurgical suture. Violations of capillary perfusion in free flaps occur in 5-13% of cases (Afridi N., 2000; C.Y. Pang, P.C. Neligan, 2013), and the frequency of necrosis of flaps according to publications 2012-2017. in 11.3% (P. Gir, 2012; A. T. Laungani, 2017).

The causes of capillary hypoperfusion (against the background of well-founded microvascular anastomoses) are:

1. Primary ischemia for more than 90 minutes, while a flap with a crossed vascular pedicle is in preparation for inclusion in the bloodstream;
2. Denervation of the vascular bed of the transplant up to the arterioles (capillary perfusion regulator):
 - Loss of the main neurogenic component of



the basal tone of arterioles while maintaining myogenic;

- Violation of the opening of arterioles due to the lack of a neurogenic component of the basal tonus in them and a break in the ways of the cardiac synchronizing reflex;
- 3. Disturbance of suction function of denervated venules, arteriolo-venular shunting, interstitial swelling of flap tissues, development of secondary ischemia;
- 4. Absence of lymphatic drainage.

Prevention of complications

1. When preparing the ends of the vessels to perform the microvascular suture, it is necessary to shift the periadvential tissue by no more than 2 mm in the proximal direction in order to minimize disturbances in the regeneration of the vascular wall in the anastomosis area.
2. Slow filling with blood of denervated vessels of a free flap (systolic pressure not

more than 100 mm Hg), by including blood flow not in the main vessels, but in their branches ("end-to-end"), provided identical diameters of the cross-linked vessels.

3. Normovolemic hemodilution with dextrans (maintenance of adequate capillary blood flow) and hydroxyethyl starch 130/0,4 ("Volu-ven") (prevention of interstitial edema of the flap tissue) should be performed 10-15 minutes before the beginning of reperfusion of the flap in the recipient zone.
4. Prohibition of the use of sympathomimetics during surgery for transplanting loose (denervated) flaps (local infiltration anesthesia with adrenaline, preparations for increasing tissue perfusion) due to increased sensitivity of denervated structures to adrenaline, norepinephrine.
5. Prevention of the development of generalized vasospasm by intra- and post-operative warming of the external contour of the patient to 37.5-38.0 °C (for 3 days) and adequate analgesia.

Free Vascularized Fibula Graft for Osteonecrosis of the Femoral Head. How I Do It?

3

Alexandros Beris, MD

Professor of Orthopaedics, University of Ioannina

Ioannis Gkiatas

MD, Resident, Orthopaedic Department, University Hospital of Ioannina

Ioannis Kostas-Agnantis

MD, Consultant, Orthopaedic Department, University Hospital of Ioannina

Introduction

Osteonecrosis of the femoral head consists a multifactorial disease. In young patients and in early stages of the disease, free vascularized fibular graft is recommended and might be a salvaging procedure. The pioneering work of Urbaniak in osteonecrosis of the femoral head treated with free vascularized fibular graft and the more than 2000 operation he has performed and reported, have shown its benefit [1, 2].

The widespread use of hip replacement with the use of small incisions and very early rehabilitation protocol have lessen the need of free vascularized fibula graft for osteonecrosis of the hip. The free vascularized fibular graft has also the disadvantage of the need of two groups of experienced microsurgeons in order to be performed. We still perform this demanding operation in young patients with Steinberg II stage of osteonecrosis and in combination with valgus osteotomy as in treating osteonecrosis of

the femoral head with nonunion of subcapital fracture of the hip.

Positioning of the Patient

The patient is placed in lateral decubitus position draping both the hip and the tibia. The operation is performed by two teams of microsurgeons working simultaneously. The first team is harvesting the fibular graft, whereas the second one prepares the hip area for the placement of the bone graft.

Fibula Harvesting

The harvesting technique of free vascularized fibula graft was described by Gilbert [3] and Urbaniak [4]. Through a lateral incision the middle third of the fibula along with the nutrient vessels is approached in the interval between peroneal muscles and gastrocnemius. These nutrient vessels of the graft are usually placed 12cm underneath the head of the fibula. The length of the fibula graft is calculated intraoperatively. In the proximal part the surgeon should have a clear view of all the three vascular pedicles (anterior tibial, posterior tibial and peroneal), before proceeding to harvesting for possible anatomic variations. Preparation of the fibula follows taking care of the peroneal vessels and the periosteal branches leaving a short muscle cuff around fibula. The distal cut should be approximately 10-12cm proximal of the ankle joint in order to keep the joint stable.

Preparation of the Graft

After the harvesting of the fibula, the graft needs to be prepared in order to be

placed in the femoral tunnel. The periosteum at the end of the fibula to be implanted is everted (*Figure 1*), in order for the cambium layer to be presented and as a result to promote the osteointegration of the graft. Moreover, the end of the fibular graft that inserts into the femoral tunnel is roundly shaped.

Preparation of the hip

Having the patient in the lateral decubitus position, the affected hip is exposed through a curved anterolateral incision. An interval is created between tensor fascia lata and gluteus maximus, followed by dissection between the rectus femoris and the vastus intermedius. The lateral aspect of the proximal femur is exposed and the transverse branch of the lateral circumflex artery, with its two accompanying veins, is dissected underneath the fascia of rectus femoris and prepared for the anastomosis with the peroneal vessel pedicle of the fibula. A K-wire pin is inserted between the first and the second third of the lateral cortex of the proximal femur under fluoroscopic control and it is used as a guide. After that, a cylindrical tunnel is created using progressive reaming. The diameter of the reamed tunnel is approximately 16-17mm, whereas the depth of the ream reaches approximately the 4mm from the articular surface into the subchondral bone. The necrotic bone is removed with the help of an angled spoon and cancellous bone is packed into the created cavity. The femoral canal is transformed from its first circular shape to a triangular shape in order to accommodate the triangular fibular graft without compromising the peroneal vessels.

Insertion of Fibular Graft-Anastomosis

The free vascularized fibular graft is inserted into the reamed femoral canal under fluoroscopic guidance. The graft is stabilized with a titanium K-wire and accurate cutting of the excess of the fibula is performed. After that the vessels are prepared for the end-to-end microanastomoses. In some occasions, both the artery and the vein can be hold with a single vessel clamp. The microsutures are placed in the anterior wall of both vessels and after that, the clamp is reversed in order to place sutures to the posterior wall of the vessels.

Optimal graft placement (The Ioannina Aiming Device)

The appropriate aiming in order for graft to be placed in the center of the damage in the femoral head is of high importance. In the conventional technique, the insertion of the graft is achieved under fluoroscopic guidance. Nevertheless, even with the use of c-arm the guidance of the drill and the graft insertion can be more accurate. Trying to achieve better accuracy concerning the femoral tunnel, Beris and Soucacos published in 2001 their research about the Ioannina Aiming Device concerning a patient specific method, which provides maximum accuracy in the positioning of the fibular graft aiming straight in the center of the necrotic area into the femoral head [5].

Preoperatively a CT scan of the proximal femur is needed starting from the major trochanter to the articular surface of the femoral head. Based on this examination a three-dimensional model of the proximal femur is

created depicting also the necrotic area of the femoral head. After that, with the help of the image analysis, and the CAD-CAM technique the optimal canal is calculated. With the help of a computer the Ioannina Aiming Device is designed based on the lateral surface of the trochanter including a small canal for the guide wire, which is place according to the computed tomography. These data can be printed using a 3 dimensional printer.

Intraoperatively, the Ioannina Aiming Device is used after the preparation of the recipient vessels in the hip area. The lateral surface of the proximal femur is dissected carefully so that the aiming device can be anchored adequately. The periosteum is stripped carefully. The medial surface of the aiming device fits exactly to the lateral surface of the proximal femur. The device is placed and the guiding K-wire is inserted into the femoral head.

In comparison with the fluoroscopic guidance for the femoral tunnel it was found that the accuracy of the patients who were operated with the use of the Ioannina Aiming Device was 85% (*Figure 2*). On the other hand, in the patients with fluoroscopic guidance the accuracy was 55%. Additionally, the operation time was decreased by 17 minutes and the exposure to radiation was also decreased by 70%.

Postoperative care

Non-weight-bearing mobilisation starts on the second postoperative day and continues for six weeks and then weight-bearing increases gradually until full weight-bearing at four to six months. Follow-up clinical and radiographic examinations are performed at three and six months, and yearly thereafter [6].

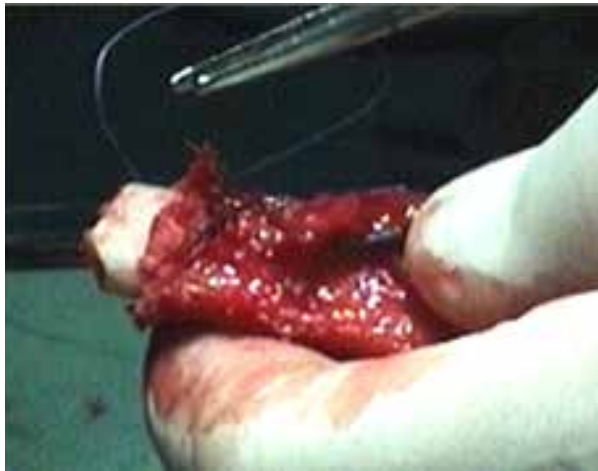
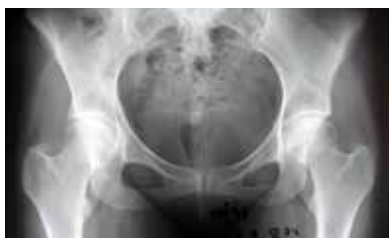
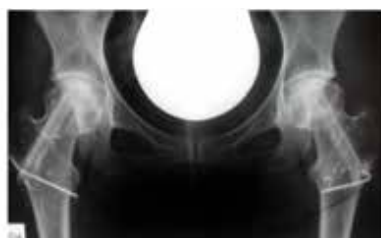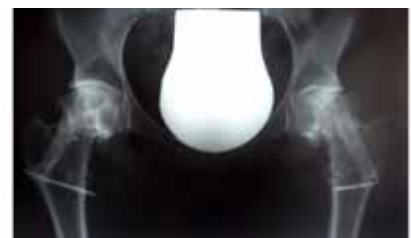Figure 1: Free vascularized fibular graft with eversion of the periosteum and round shaping of the end



A



B



C

Figure 2: Free vascularized fibular graft used for osteonecrosis of both femoral heads. A: Preoperative; B: 9 months postoperative; C: 11 years postoperative

REFERENCES

1. Urbaniak JR, Coogan PG, Gunneson EB, Nunley JA. Treatment of osteonecrosis of the femoral head with free vascularized fibular grafting. A long-term follow-up study of one hundred and three hips. *The Journal of bone and joint surgery American volume*. 1995;77(5):681-94.
2. Urbaniak JR, Harvey EJ. Revascularization of the femoral head in osteonecrosis. *The Journal of the American Academy of Orthopaedic Surgeons*. 1998;6(1):44-54.
3. Gilbert A. Free vascularized bone grafts. *International surgery*. 1981;66(1):27-31.
4. Urbaniak J. Avascular necrosis of the femoral head treated by vascularized fibula graft. *Orthop Trans*. 1985;9:401.
5. Beris AE, Soucacos PN. Optimizing free fibular grafting in femoral head osteonecrosis: the Ioannina aiming device. *Clinical orthopaedics and related research*. 2001(386):64-70.
6. Korompilias AV, Lykissas MG, Beris AE, Urbaniak JR, Soucacos PN. Vascularised fibular graft in the management of femoral head osteonecrosis: twenty years later. *The Journal of bone and joint surgery British volume*. 2009;91(3):287-93. doi:10.1302/0301-620X.91B3.21846.

Bionic hand – surgical procedure for electrode implantation

4

Bumbaširević Marko ^{1,2}, **Raspopović Staniša** ³, **Palibrk Tomislav** ^{1,2},
Matić Slađana ^{1,2}, **Lešić Aleksandar** ^{1,2}

¹ Orthopedic and Traumatology University Clinic, Clinical Center of Serbia, Serbia

² Faculty of Medicine, University of Belgrade, Serbia

³ Sensars Neuroprosthetics, Lausanne, Switzerland

The latest modern technologies and rapid technical progress can provide successful limb replacement, along with sensibility and functional capabilities in arm amputees. Robotic [1-3] and new bionic [4-11] limbs are an important issue and topic in the scientific and orthopaedic communities. Modern bionic prostheses, such as the MIT and John Hopkins Defense Advanced Research Projects Agency (DARPA) project, managed to restore near-natural motor and sensory capabilities to upper- and lower-extremity amputees [12, 13].

Modern bionic limbs are controlled by electric signals from the muscle and nerves above the level of amputation. At present, the limbs are classified in 3 main groups, according to the type of the tissue interfaced:

1. Nerve transferring (targeted muscular reinnervation);
2. Direct muscle interfacing; and
3. Direct nerve interfacing.

In our clinical practice, we used the third type of bionic limbs, with a direct interface between nerves and electrodes. This paper

should help you to avoid mistakes during the implantation procedure and to produce a firm nerve-electrode interface, stable implant and good feedback from the patient [14].

The surgical approach for electrode implantation to the targeted upper extremity nerves is direct. The limb is placed on a table in abduction and external rotation. Nerves that are our focus are the median and ulnar nerves because of their dominance in the hand sensibility.

Skin incision and preparation between muscles and other soft tissues must be gentle to prevent unwanted scar formation and fibrosis. Hemostasis must be meticulous to diminish possible interference with electronic signals transport and to preclude possible edema and infection. Attention should be paid to nerve preparation especially. It is crucial to preserve the epineural sheet along with its gentle vascular structure and to implement a plan for electrode placement. Targeted nerves are usually exposed along their course for about 6-8 cm.

1. At the beginning, after we approach the nerve, a subcutaneous tunnel is formed for cable and connector placement. This is the first thing we do after we perform nerve isolation and preparation. If we do it after electrode placement, there is a possibility that the previously implanted electrodes would be ripped from the nerve. The tunnel is formed and the cable with connector is pulled out through a small skin incision, proximally from the electrode placement, but accessible for approach for clinical trial purposes. After completing that part of the procedure, we can proceed to electrode placement.
2. Electrodes are placed with the help of a straight needle and small filament (8-0 su-

ture) (*Figure 1*). The needle is introduced perpendicularly into the nerve through as much fascicles as possible. We have to be gentle and careful during this process because we don't want to detach the needle from the filament and the electrode.

3. Also during the procedure, due to a discrepancy in size between the needle and the electrode, it can sometimes be difficult to pass the electrode through. We have to move the needle and filament back and forth a couple of times so the electrode can safely find its path through the bundles. We must avoid any use of a passer or dilators, because they can cause a large-size hole to be formed, and the placed electrode will not be in contact with nerve tissue consequently. The electrode must be snuggling the nerve, ensuring that the connections are in contact with the fascicles, so that the impulses could be transferred.
4. The electrode is secured to the epineural sheet using a couple of 8-0 nylon sutures; and needle and filament are removed. To prevent any breakage, the fragile structure of electrodes must always be kept in mind during the implantation process.
5. After the electrodes are placed and fixed to the nerve they are additionally secured with sutures at the entrance point (the place where the electrode enters the nerve-transversal portion of , at the longitudinal portion of electrode and at the place where the longitudinal portion enters the cable. (*Figure 2*) After that we slightly tighten the cable so it does not move much during muscle flexion in the forearm region and we secure it with skin sutures in the form of loop at the cable exit point.
6. Skin is sutured and bandages are applied. Our experience with electrode placement

showed that the most important thing we have to take care about is the fragility of electrodes. They can be easily broken and pulled out from the accompanying needle and filament.

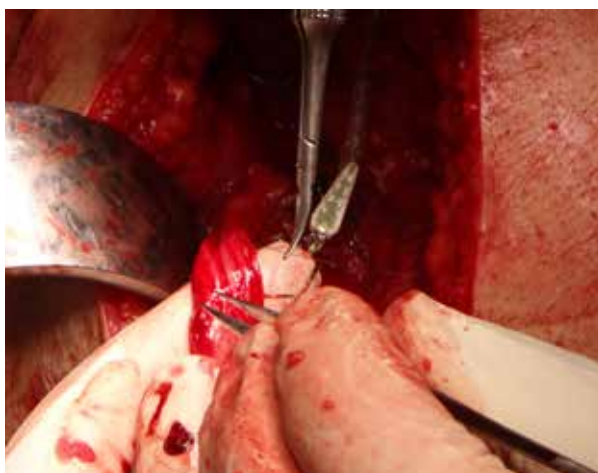


Figure 1: Electrode is introduced perpendicularly into the nerve through as many fascicles as possible. It is attached to the straight needle and a suture.

Careful manipulation is mandatory and cable securing at different levels is a crucial factor in the mechanical stability of the whole system.

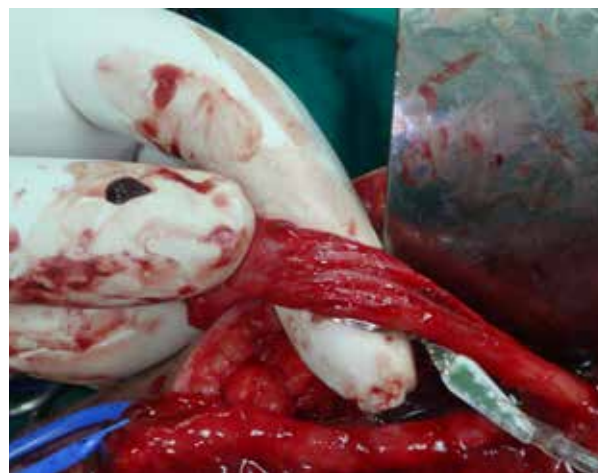

Figure 2: Electrode is secured with suture at different points of the nerve to the epineurial sheet.

REFERENCES

1. Hargrove LJ, Simon AM, Young AJ et al. Robotic leg control with EMG decoding in an amputee with nerve transfers. *N Engl J Med* 2013;369:1237-42.
2. Dhillon GS, Lawrence SM, Hutchinson DT, Horch KW. Residual function in peripheral nerve stumps of amputees: implications for neural control of artificial limbs. *J Hand Surg Am* 2004;29(4):605.
3. Rossini PM, Micera S, Benvenuto A, Carpaneto J, Cavallo G, Citi C, Cipriani C, Denaro I, Denaro V, DiPino G, Ferreri F, Gugliemelli E, Hoffmann P, Raspopovic S, Rigosa J, Rossini L, Tombini M, Dario P. Double nerve interneural interface implant on a human amputee for a robotic hand control. *Clin Neurophysiol* 2010;121:777-83.
4. Farina D, Aszmann O. Bionic Limbs: Clinical Reality and Academic Promises. *Sci Transl. Med.* 2014;257ps12.
5. Raspopovic S, Petrini FM, Zelechowski M and Valle G. Framework for the development of neuroprostheses: from basic understanding by sciatic and median nerves models to bionic legs and hands. *Proceedings IEEE* 2017;105(1): 34-49.
6. Clement RGE, Bugler KE, Oliver CW. Bionic prosthetic hands: A review of present technology and future aspirations. *The Surgeon* 2011;9:336-40.
7. Herr MH, Grabowski AM. Bionic ankle-foot prosthesis normalizes walking gait for persons with leg amputation. *Proc. R. Soc. B.* 2012;279:457-64.
8. Aszmann OC, Roche AD, Salminger S et al. Bionic reconstruction to restore hand function after brachial plexus injury: a case series of three patients. *Lancet* 2015;385:2183-9.
9. Raspopovic S, Capogrosso M, Petrini FM, Bonizzato M, Rigosa J, Di Pino G, Carpaneto J, Controzzi M, Boretius T, Fernandez E, Granata G, Oddo CM, Citi L, Ciancio AL, Cipriani C, Carrozza MC, Jensen W, Gugliemelli E, Stieglitz T, Rossini PM, and Micera S. Restoring natural sensory feedback in real-time bidirectional hand prostheses. *Sci Transl Med* 2014;6(222):222ra19.
10. Tan DW, Schiefer MA, Keith MW et al. A neural interface provides long-term stable natural touch perception. *Sci Transl. Med* 2014;257ra138.
11. Ortiz-Catalan M, Hakansson B, Branemark R. An osseointegrated human-machine gateway for long-term sensory feedback and motor control of artificial limbs. *Sci Transl. Med* 2014;257re6

12. Rouse EJ, Villagaray-Carski NC, Emerson RW and Herr HM. Design and testing of a bionic dancing prosthesis. *PLoS One* 2015; 10(8):e0135148.
13. Tenore FV, Vogelstein RJ. Revolutionizing Prosthetics: Devices for Neural Integration. Johns Hopkins *APL Technical Digest* 2011; 30(3):230-9.
14. Di Pino G, Denaro L, Vadalà G et al. Invasive neural interfaces: the perspective of the surgeon. *J Surg Res.* 2014 May 1; 188(1):77-87. doi: 10.1016/j.jss.2013.12.014. Epub 2013 Dec 20.

Homodigital neurovascular island flaps for the reconstruction of fingertip injuries in children

5

Zoe H. Dailiana Md PhD, Vasileios A. Kontogeorgakos Md,
Sokratis E. Varitimidis Md PhD

Medical School, University of Thessaly, Larissa, Greece

Introduction

Fingertip injuries are common hand injuries, both in children and adults, and may involve the pulp with or without the distal phalanx and the nail. The subsequent loss of sensation after fingertip amputations has greater consequences in children as the brain is deprived all the necessary information for the development of fine pinch activities.

According to Allen's classification, four types of amputations exist: at distal pulp (type

I), distal to the distal phalanx (type II), at nail matrix (type III), and at the base of the distal phalanx (type IV) (Allen MJ, 1980), [1] (*Figure 1A, 2A, 3A*). In all cases the coverage of the fingertip defect with preservation of sensibility and without digital shortening is the main goal of every reconstructive procedure.

Among the different types of flaps described in the literature for the reconstruction of amputated fingertips (Shepard et al., 1983; Foucher et al., 1989; Lanzetta et al., 1995; Varitimidis et al., 2005; O'Brien B, 1968; Fitoussi et

al., 2004), [2, 3, 4, 5, 6, 7] the homodigital neurovascular island flap is adaptable to configuration of defect and provides skin with excellent perfusion and functional sensibility (Foucher et al., 1989; Varitimidis et al., 2005) [3, 5].

Surgical technique

An Allen test for patency of the digital arteries must be performed before the initiation of the procedure. Apart from the injuries to the neurovascular bundle(s), the avulsion injuries and the severe contamination of the injured digit are also contraindications for the procedure.

The procedure is performed with the use of magnifying loupes, under general anesthesia or axillary block in case of adolescents. The tourniquet is applied to the humerus and is inflated to 100 mm Hg above the systolic pressure.

The flap is designed just proximally to the defect (*Figure 2B*) and extends palmarly to mid-axis of the digit and dorsally to the nail ridge, leaving intact the ridge and at least 1 mm of tissue. The dimensions of the flap are analogous to the size of the defect and the lateral side for the elevation of the flap (radial or ulnar) is decided based on the shape of the defect (obliquity) and on the injured digit (the radial side of the index finger and the ulnar side of the small finger should be respected and flaps must be raised from the ulnar side of the index and the radial side of the small finger respectively). The size of the flap varies according to the dimensions of the defect and to the age of the child and ranges from 0.7X0.5 cm to 1.5X1 cm.

It is imperative to include the neurovascular bundle in the flap. The microsurgical dissection of the flap advances from distal to proximal, by dissecting the skin, subcuta-

neous tissue, and neurovascular bundle, en block, from the underlying bone and tendon sheath. The most delicate point is at the proximal junction of the flap with the neurovascular pedicle, where the pedicle must not be cut while the skin and subcutaneous tissue is elevated free.

The dissection of the neurovascular bundle is then continued proximally through a Bruner or semi-Bruner that extends to the proximal phalanx base (*Figures 1B, 2C, 3B*). A careful ligation of the small transverse vincular and articular branches, arising at IP joints level or just distally, is imperative to prevent hematoma formation. The pedicle must be dissected with adequate subcutaneous tissue (*Figures 1B, 2C*). This fatty tissue cuff protects the bundle and includes micro-veins necessary for flap drainage (Eaton RG, 1968) [8].

The island flap is then advanced distally to the deficit. In case of tension to the neurovascular pedicle, either the dissection of the pedicle must be extended proximally or the PIP and DIP joints must be flexed. The advancement ranges from 7 to 15 mm. The flap is then sutured with 4/0 absorbable sutures (*Figure 1C*), while the neurovascular bundle is covered by the skin flaps of the Bruner incision.

Before suturing the skin flaps, the tourniquet must be released and the viability of the flap must be observed. The duration of the procedure, until the release of the tourniquet ranges from 20 to 40 minutes. In case of problematic perfusion, tension to the flap must be alleviated by cutting one or more of the sutures stabilizing the flap to the defect. In addition, the neurovascular bundle must be inspected for potential twisting. Finally, cautious hemostasis must be performed with a fine bipolar cautery.

After suturing of the skin flaps with care for the underlying neurovascular bundle, the

donor site is covered with a skin graft from the hypothenar eminence or from the ulnar surface of the wrist. In case of an avulsed nail, this must be cleaned and re-inserted to the nail bed and in case the nail is absent a replica must be temporarily inserted to protect the contour of the nail bed.

Finally, paraffin gauzes are inserted between the two adjacent fingers and on the donor site of the graft (hypothenar eminence or ulnar wrist) and a steady bulky dressing is applied to the hand. In case of very young children, two layers of stockinette bandage are applied around the hand and distal fingers so as to protect the operated digit from children's curiosity. Usually, the young patients remain hospitalized for 6-8 hours after the procedure and are released the same day.

The dressing is changed weekly and is removed 15-20 days postoperatively, depending on the age and co-operation of the young patient. The child is encouraged to start using his/her hand actively and to play with toys/tablets that include the use of the operated digit. The risk of flexion contracture is minimal in children.

Discussion

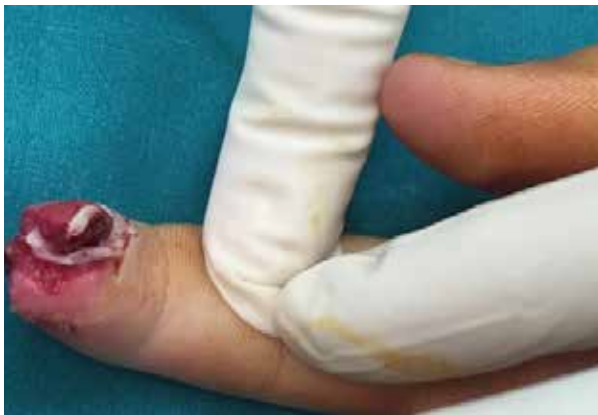In case of complex injuries of the fingers in children, the choice of the most suitable flap for the coverage of the growing fingers depends on the size and location of the defect. Proper treatment of the fingertip injuries is very important to avoid a painful or dystrophic fingertip that will compromise the function of the whole growing hand. Improper treatment may lead to fingertip insensitivity and deformity, including a hook nail (Stevenson TR, 1992) [9]. In case of fingertip ampu-

tations in children, the preservation of a functional length of the digit with adequate joint motion and above all, the functional sensibility of the fingertip is imperative for the normal development of fine pinch activities in children.

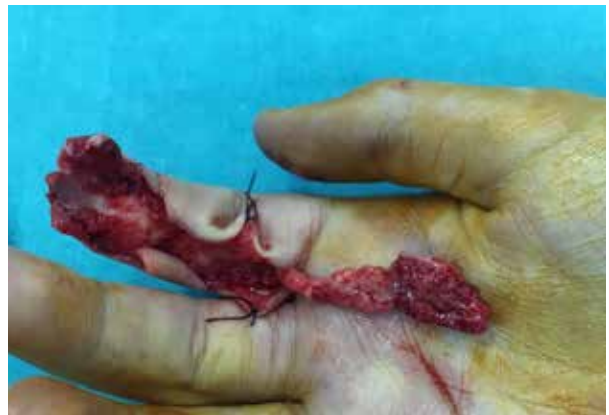Knowledge of the microvascular anatomy of the growing hand, consideration of the very small diameter of digital arteries in children, and familiarity with microsurgical dissection are necessary for a successful outcome. The dissection and distal transfer of the homodigital island flap can be concluded in a single procedure, however these flaps require the transfer or sacrifice of one neurovascular bundle of the donor finger. A meticulous dissection of the pedicle with a fatty tissue cuff protecting the pedicle and providing drainage is also a key-principle (Eaton RG, 1968) [8].

Among the different methods of treatment of fingertip injuries, the revision amputation further shortens the finger, the V-Y advancement flaps (Shepard GH, 1983) [2] are only indicated for limited defects, and the thenar flap (Fitoussi et al., 2004) [7] has the drawbacks of potential stiffness and insensitivity leading to bypass of the insensitive finger. The island neurovascular flaps (Foucher et al., 1989; Varitimidis et al., 2005; Wang et al., 2011; Feng et al., 2017) [3, 10, 11] can be applied in amputated fingertips and amputation stumps and offer a well-padded fingertip (*Figures 1D-E, 3C-D*) with functional sensibility, provided that a careful preoperative planning and a meticulous microsurgical dissection is performed. After reconstruction, the functional sensibility and the painless fingertip not only prevent by-passing of the injured finger but also provide to the brain all the necessary information for the development of fine activities of the growing hand.

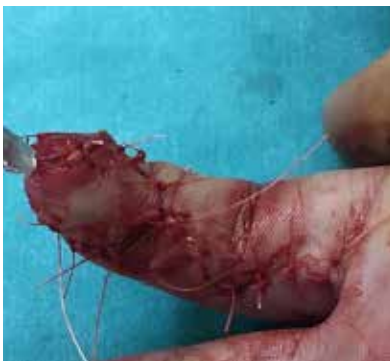Figure 1



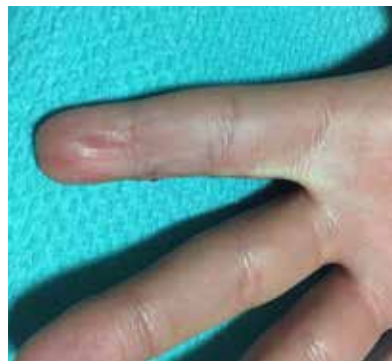A. Allen II amputation of right index in an 11-year old boy



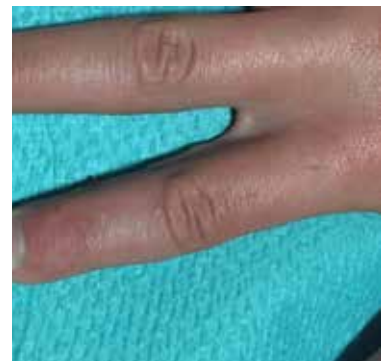B. Ulnar-side homodigital island flap of the right index



C. Coverage of fingertip defect with the homodigital flap

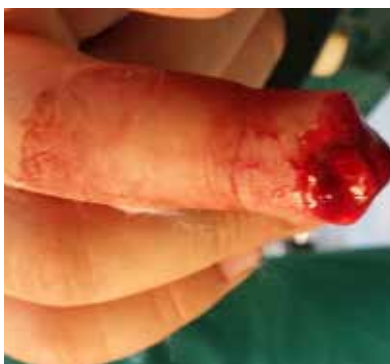

D. Result 10 months post-operatively depicting the well-padded fingertip.

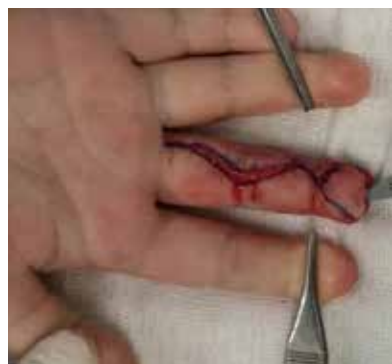

E. Result 10 months post-operatively depicting the absence of hooked nail.

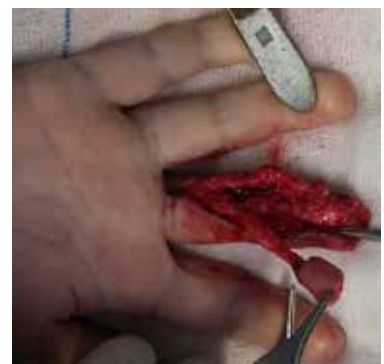Figure 2



A. Allen III amputation of middle finger in an 8-year old boy

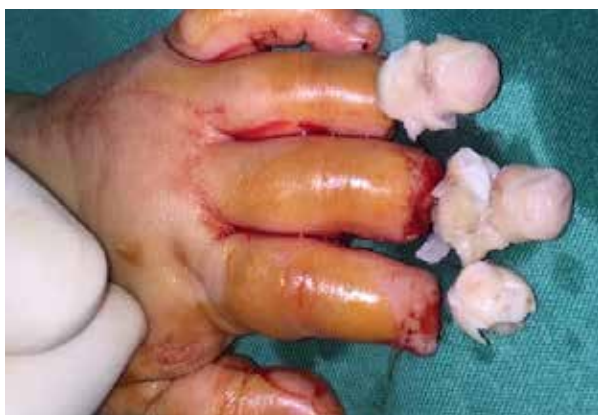

B. The flap is designed just proximally to the defect

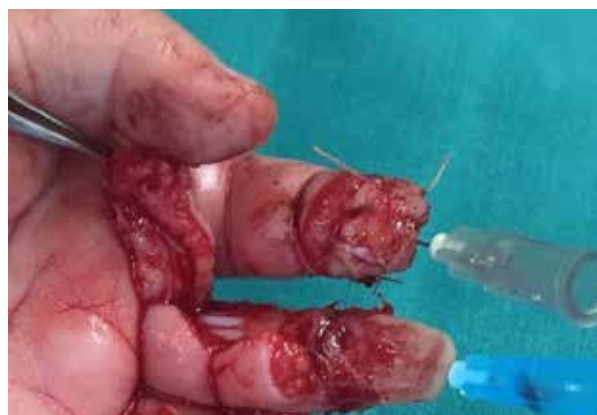

C. The dissection of the neurovascular bundle of the ulnar side is continued proximally through a semi-Bruner incision that extends to the base of the proximal phalanx. A fatty tissue cuff protects the bundle and includes the micro-veins necessary for flap drainage.

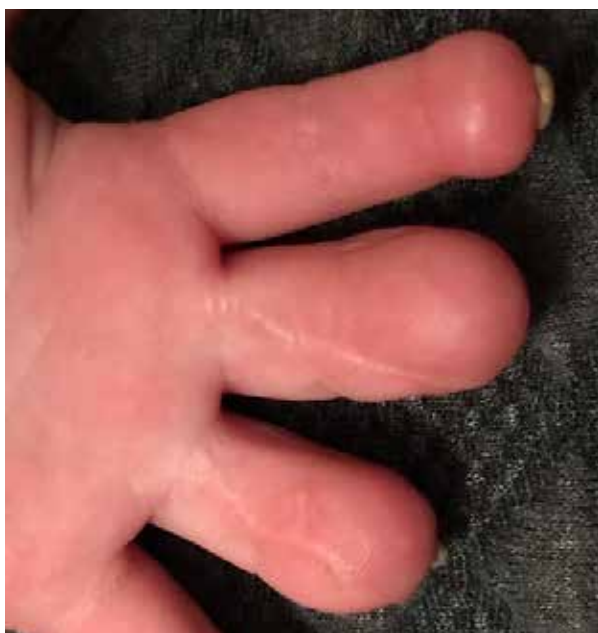Figure 3



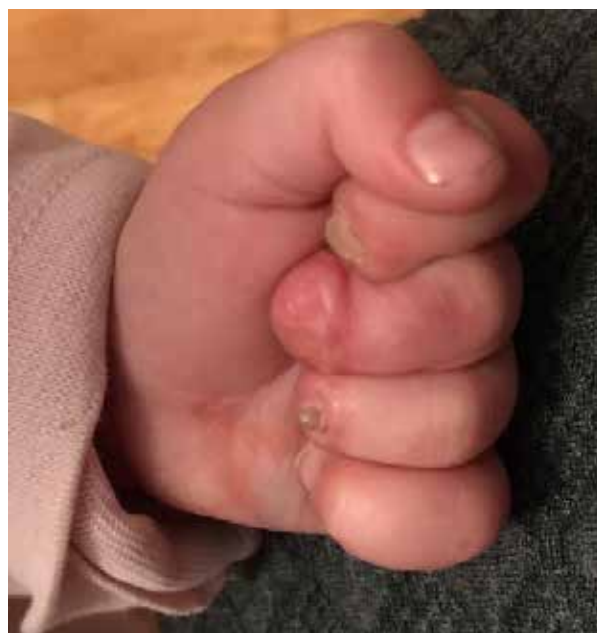A. Multiple avulsion amputations of distal fingers, including amputations of the middle and ring fingers at the DIP joint level, in a 12-month old girl.



B. The middle and ring fingers are reconstructed with the osteosynthesis of the distal phalanx as a free graft and the use of homodigital flaps from the radial side of the fingers



C. Result 2 years post-operatively depicting the coverage of the amputation stumps



D. Result 2 years post-operatively depicting the function of the hand

REFERENCES

1. Allen MJ. Conservative management of fingertip injuries in adults. *Hand* 1980;12(3): 257-265.
2. Shepard GH. The use of lateral V-Y advancement flaps of fingertip reconstruction. *J Hand Surg Am* 1983;8(3):254-259.
3. Foucher G, Smith D, Pempinello C, Braun FM, Citron N. Homodigital neurovascular island flaps for digital pulp loss. *J Hand Surg Br* 1989;14(2):204-208.
4. Lanzetta M, Mastropasqua B, Chollet A, Brisebois N. Versatility of the homodigital triangular neurovascular island flap in fingertip reconstruction. *J Hand Surg Br* 1995;20(6):824-829.
5. Varitimidis SE, Dailiana ZH, Zibis AH, Hantes M, Bargiotas K, Malizos KN. Restoration of function and

- sensitivity utilizing a homodigital neurovascular island flap after amputation injuries of the fingertip. *J Hand Surg Br* 2005;30(4):338-342.
6. O'Brien B. Neurovascular island pedicle flaps for terminal amputations and digital scars. *Br J Plast Surg* 1968;21(3):258-261.
 7. Fitoussi F, Ghorbani A, Jehanno P, Frajman JM, Penneçot GF. Thenar flap for severe fingertip injuries in children. *J Hand Surg Br* 2004;29(2):108-112.
 8. Eaton RG. The digital neurovascular bundle. A microanatomic study of its contents. *Clin Orthop Relat Res* 1968;61:176-185.
 9. Stevenson TR. Fingertip and nailed injuries. *Orthop Clin North Am* 1992;23(1):149-159.
 10. Wang B, Chen L, Lu L, Liu Z, Zhang Z, Song L. The homodigital neurovascular antegrade island flap for fingertip reconstruction in children. *Acta Orthop Belg* 2011;77(5):598-602.
 11. Feng SM, Wang AG, Zhang ZY, Sun QQ, Tao YL, Zhou MM, Hao YJ. Repair and sensory reconstruction of the children's finger pulp defects with perforator pedicled propeller flap in proper digital artery. *Eur Rev Med Pharmacol Sci* 2017;21(16):3533-3537.

Technical tips on the vascularized lymph node transfer combined with fat-augmented latissimus dorsi flap for simultaneous breast and lymphedema reconstruction

6

Efterpi C. DEMIRI

Department of Plastic Surgery, Aristotle University of Thessaloniki,
Papageorgiou Hospital, Thessaloniki, GREECE

Introduction

The combined use of free abdominal and inguinal lymph node flaps actually constitutes the ideal reconstructive option for simultaneous breast and lymphedema reconstruction [1-4]; however, when abdominal flaps are not available, other options, i.e. latissimus dorsi-based reconstructive methods should be considered

The association of the LD flap with autologous lymph node (LN) transfer to treat

mastectomy patients suffering from breast cancer related lymphedema (BCRL) has already been reported as a chimeric pedicled flap [6].

Herein, we describe the technical tips on using a pedicled extended fat-augmented latissimus dorsi (FALD) flap associated with free vascularized groin lymph node transfer for simultaneous breast and arm lymphedema reconstruction, which is -to our knowledge- the first report of this combined procedure.

Surgical Technique

Pre-operative markings include the design of both the LD myocutaneous flap and the inguinal lymph node flap. Using the pinch technique, an oblique skin paddle is drawn on the back, centered on the middle-lower bra strap area; subsequently, the lymph node flap is drawn over the selected groin site according to the selected lymph node technique and based on the results of a pre-operative SPECT-CT investigation [7].

Surgery starts with the lymph node flap dissection, the patient lying in a supine position with the lymphedematous upper arm abducted at right angles to give adequate axillary access. Two to four lymph nodes are included in the lymph node flap which is based on the superficial circumflex iliac or the superficial inferior epigastric vessels. During the lymph node flap harvesting, a second operative team is preparing the lymph-tissue flap recipient axillary area, with meticulous release of axillary contractures and complete scar excision, and followed by the dissection of the recipient lateral thoracic vessels. The LN flap is transplanted in the axillary area; end-to-end arterial and venous microvascular anastomoses are performed for the revascularization. Subsequently, the lymph tissue flap is positioned and sutured to a well vascularized and healthy axillary pocket (*Figure 1*), and covered by a thin colored plastic sheet, its size being slightly larger from the flap's size, which is fixed with four sutures to the surrounding tissues (*Figure 2*); with this maneuver, the lymph node flap not only is protected during the patients' position changes, but also its implantation site will be easily identified during dissection of the LD flap pedicle towards the axillary area.

Meanwhile and after the execution of the

micro-anastomoses, fat harvesting is performed, usually from the abdominal and hip regions, using the tumescent technique with 3mm cannulas for liposuction.

After having completed the lymph node flap transfer, the axillary area is loosely closed, and the patient is changed to a lateral decubitus position for the LD flap dissection; the flap is harvested in an extended fashion, including the sub-fascial fat pads of the back. Simultaneously, complementary liposuction may be performed over the homolateral hip and thigh, if more fat is needed to achieve larger breast volume.

After having completed the elevation of the flap, it is passed through a subcutaneous tunnel to the breast area; the presence of the plastic blue shows the area of the lymph node flap insertion; great attention is required to recognize it and avoid injury to both the flap and the microvascular anastomoses.

During the closure of the back donor site, the harvested fat tissue is prepared for injection using the washing-filtering technique. Lipofilling is now carried out, injecting the fat intramuscularly within the latissimus muscle and subcutaneously within the skin island of the flap, as well as the recipient tissues, pectoralis major muscle and subcutaneous planes of the mastectomy skin flaps. Before final positioning of the fat-augmented LD flap, the plastic sheet which was used to cover the lymph node flap is taken away, suction drains are put in place and wounds are primarily sutured.

Methods - Results

During the last four years, we performed this method in seven post-mastectomy women (mean age 33.1years, BMI 25.3) with

Stage I or II breast cancer related lymphedema; in all cases, free abdominal flaps were not indicated or not available. All patients had preoperative upper and lower limb lymphoscintigraphy for lymphedema evaluation and selection of the donor lymph nodes. Mean operative time was 5.8 hours and mean injected fat volume/session was 245ml (range 170-350ml). At 12-month follow-up, a reduced volume difference between arms was recorded (average 51.7%). Regarding lymphedema treatment outcomes, functional improvement and symptoms relief was reported by all patients. Post-operative lymphoscintigraphy showed radiotracer uptake by the transplanted nodes in three out of five assessed patients.

Discussion

The use of latissimus dorsi-based breast reconstruction has been reported to improve upper limb breast cancer-related lymphedema even without being associated to vascularized lymph node transplantation [8, 9].

However, a combined breast and lymphedema flap reconstruction is well accepted to provide better results regarding lymphedema cure [10]. Although the use of a pedicled chimeric LD flap with the lateral thoracic lymph nodes has also been proposed [6], we believe that the regional nodes may be seriously affected by the previous traumas, i.e. surgery or radiotherapy, and therefore, the benefit of using them to treat ipsilateral breast cancer-related lymphedema might be controversial. On the other hand, according to the combined technique that we described, the free inguinal vascularized lymph node flap may be safely combined with the FALD flap and provide favorable results in both breast and lymphedema reconstruction; besides, the viability and functional status of the transplanted nodes have been shown and well proved by a late postoperative lymphoscintigraphy. In conclusion, this procedure should be considered as an alternative surgical method for simultaneous breast and lymphedema reconstruction,

especially when abdominal tissue transfer is not an option.

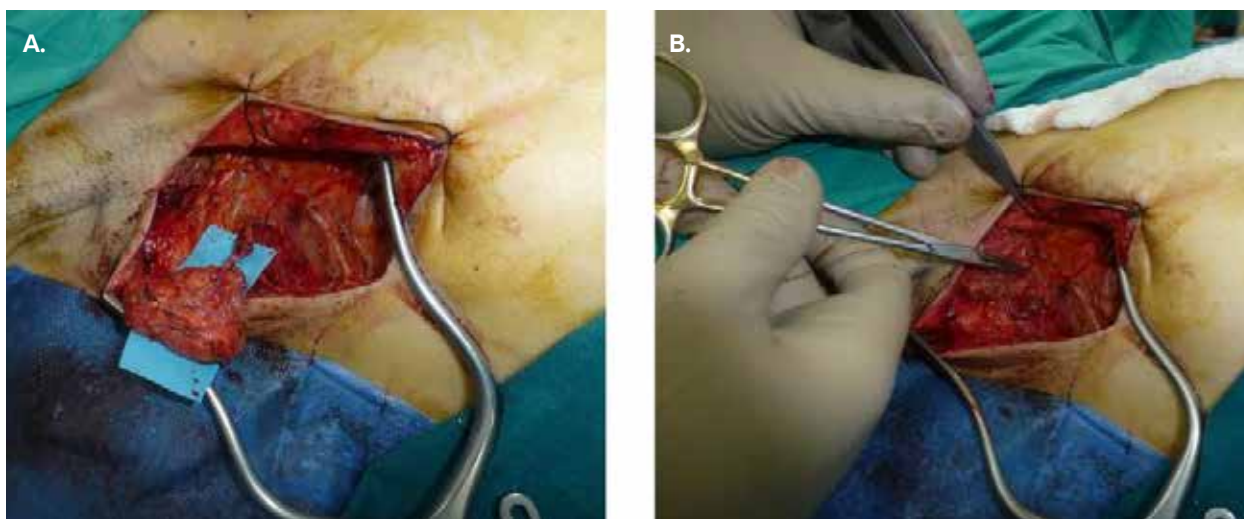


Figure 1: The lymph node flap after transplantation and revascularization to the lateral thoracic vessels (a); fixation of the flap to the axillary region with separate absorbable sutures (b).

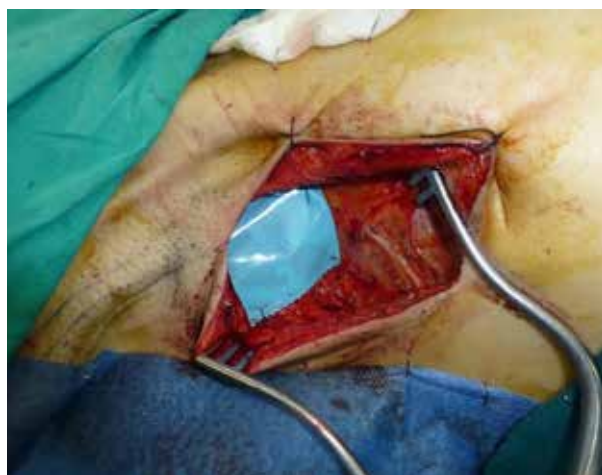

Figure 2: Coverage of the lymph node flap with a blue plastic sheet

REFERENCES

1. Saaristo A, Niemi TS, Viitanen TP, et al. Microvascular breast reconstruction and lymph node transfer postmastectomy lymphedema patients. *Ann Surg* 2012; 255(3): 468-73.
2. Chen R, Mu L, Zhang H, et al. Simultaneous breast reconstruction and treatment of breast cancer-related lymphedema with lymphatic lower abdominal flap. *Ann Plast Surg* 2014; 73 Suppl 1: S12-7.
3. Nguyen AT, Chang EI, Suami H, Chang DW. An algorithmic approach to simultaneous vascularized lymph node transfer with microvascular breast reconstruction. *Ann Surg Oncol* 2015; 22(9): 2919-24.
4. Masia J, Pons G, Nardulli ML. Combined surgical treatment in breast cancer-related lymphedema. *J Reconstr Microsurg* 2016; 32(1): 16-27.
5. Santanelli di Pompeo F, Laporta R, Sorotos M, et al. Latissimus dorsi flap for total autologous immediate breast reconstruction without implants. *Plast Reconstr Surg* 2014; 134: 871e-9e.
6. Vibhakar D, Reddy S, Morgan-Hazelwood W, Chang EI. Chimeric pedicled latissimus dorsi flap with lateral thoracic lymph nodes for breast reconstruction and lymphedema treatment in a hypercoagulant patient. *Plast Reconstr Surg* 2014; 134(3): 494e-5e.
7. Dionyssiou D, Demiri E, Arsos G, et al. The 'Selected Lymph Node' technique to facilitate lymph node flap harvest in the treatment of upper limb lymphoedema. Abstract Book of 26th EURAPS Annual Meeting, Edinburgh, May 2015, p.147.
8. Abbas Khan MA, Mohan A, Hardwicke J, et al. Objective improvement in upper limb lymphedema following ipsilateral latissimus dorsi pedicled flap breast reconstruction- a case series and review of literature. *J Plast Reconstr Aesthet Surg* 2011; 64(5): 680-4.
9. Lee KT, Lim SY, Pyun JK, et al. Improvement of upper extremity lymphedema after delayed breast reconstruction with an extended latissimus dorsi myocutaneous flap. *Arch Plast Surg* 2012; 39(2): 154-7.
10. Engel H, Lin CY, Huang JJ, Cheng MH. Outcomes of lymphedema microsurgery for breast cancer-related lymphedema with or without microvascular breast reconstruction. *Ann Surg* 2017 Jun 7. doi: 10.1097/SLA.0000000000002322. [Epub ahead of print]

Anatomical functional reconstruction of secondary lymphoedema with the use of vascularized lymph node flap

7

Dimitrios Dionyssiou

Assistant Professor in Plastic Surgery,
Aristotle University of Thessaloniki, Greece.

Introduction

Autologous vascularized lymph node transfer (LNT) is a relatively new but well adapted surgical treatment for lymphedema, providing satisfactory results, especially in patients with early stage or mild lymphedema [1, 2].

Multiple donor sites have been described for lymph node harvest; [3, 4, 5] author's first choice for upper limb lymphedema remains the inguinal and for lower limb lymphedema

the lateral thoracic area, followed by the supraclavicular, cervical, and omental.

Although numerous studies confirm the efficacy of LNT in lymphedema treatment, its application still remains a subject of discussion due to the unpredictable positive outcome, and the potential risk of donor site morbidity, such as iatrogenic donor site lymphedema. [2, 3, 6, 7] In our published review article in 2017, we estimated a risk of 1.6% donor side lymphedema according to the updated literature [8].

In an effort to improve the anatomical knowledge of the lymph nodal donor areas, various preoperative examinations have been described, aiming to choose the most suitable lymph node flap, and reduce donor site morbidity [6, 9, 10].

In recent years, a hybrid imaging examination, named SPECT-CT, was introduced to offer compound information of lymphoscintigraphy in CT images in a single gantry. This investigative technique allows imaging amalgamation and provides accurate anatomical and functional information, while scans may be performed without changing the patient's position [11].

Our criteria of choosing the most functional lymph nodes of the inguinal or the lateral thoracic area to harvest, avoiding at the same time a damage to the critical lymph nodes for causing donor side lymphedema, is based in an original detection method, the "Selected Lymph Node" ("SeLyN") technique.

Methodology - Technique

a. Inguinal lymph node flap

The inguinal lymph node flap is mainly used for upper limb, head and neck or contralateral lower limb lymphedema. In selected cases, the flap, in a fashion of pedicle lymph node flap, can provide an excellent solution in the same groin for ipsilateral lower limb lymphedema.

The coronal, sagittal and transverse images of the hybrid SPECT-CT are used to select the most radioactive groin lymph nodes, to be included at the lymph-nodal adipose tissue flap. The lymph node flap must be located proximal of the inguinal crease, more proximal of the sentinel lymph node(s) of

the limb, at the deep adipose tissue, and at the side of the best lymphatic circulation.

Thereafter, the distance between the selected lymph nodes and the midline from the pubic symphysis to the umbilicus represents the horizontal index (i), and the distance between the pubic symphysis and the level of the horizontal index is the vertical index (ii); the depth is between the skin and the selected lymph nodes (iii) (*Figure 1a*).

Using the anatomic landmarks of the anterior superior iliac spine, the umbilicus and the pubis tubercle, the measurements are transferred onto the patient's abdominal wall. Next step is the identification of the femoral artery (FA), the superficial inferior epigastric artery (SIEA), the superficial circumflex iliac artery (SCIA) and its perforator (SCIP), and also the marking of the dominant vascular supply of the flap, using of a handheld Doppler (*Figure 1b*).

Intraoperatively, a lazy "S" 4 cm skin incision is made at the level of the marked "selected lymph nodes", the lower skin flap is lifted first, the vascular pedicle of the flap is identified and a vessel loop is placed around it. Then the pedicle is traced towards its origin at the femoral artery and afterwards towards the "SeLyN" at the deep adipose tissue level; before entering at the lymph nodes in a distance of about 2 cm the flap is elevated around its pedicle (*Figure 1c*). For better outcome, we recommend a flap size more than 25cm² which includes 3-5 lymph nodes. Smaller flaps (<25cm²) can also be effective but not as much the larger. All flaps are raised sharply with scalpel and/or scissors, or in low cautery of bipolar diathermy, while liga-clips can also applied at the donor area for hemostasis, in order to reduce the risk of seroma or haematoma.

A marking of the healthy/functional lymphatics of the arm, is taking place preopera-

tively with the use of NIR fluoroscopy, to indicate the area whereabouts the flap is targeted to provide the lymphangiogenesis. The ideal situation would be a lymph node flap able to bridge the healthy lymphatics of the arm with the deep lymphatic vessels of the axilla. New nanofibrillar collagen scaffolding technology which is under clinical investigation is aiming to bridge the gap between the healthy lymphatic vessels of the arm and the lymph node flap.

At the axillary region a meticulous and “aggressive” scar tissue (from previous surgery and radiotherapy) removal is performed to provide a well vascularized bed and restore the deep lymphatic system of the axilla. A long pedicle of the branches of thoracodorsal or posterior circumflex vessels is prepared to anastomose the transferred lymph node flap in an end-to-end fashion.

The flap usually contains only adipose tissue and lymph nodes without skin paddle; after anastomoses, it is placed and secured with sutures at the area where the lymphatic vessels of the upper proximal arm were identified with the NIR fluoroscopy. If ICG is not detectable at the proximal arm the findings of the preoperative MRI investigation can also be used. The increased endogenous expression and finally secretion of VEGF-C from the vascularized lymphatic flap, will attract endothelial cells and a spontaneous regeneration of functional lymphatic vessels will occur. These newly formed lymphatics play the main role to restore the defect between the distal and proximal damaged lymphatic system [3, 12, 13].

The donor and recipient sites are closed primarily after placing a No 12 suction drain. Patients are explained and advised to protect axilla and avoid compression of the pedicle keeping the arm in 10° abduction for the

first 2 weeks. Individualized manual lymphatic drainage through the implanted flap is strongly recommended to start the second postoperative day and continue for the first six months.

b. Lateral thoracic lymph node flap

In the same manner “SeLyN” technique based on SPECT-CT findings can be used to identify the most functional (radioactive) lymph nodes of the lateral thoracic region. The lateral thoracic lymph node flap (LTLN) is considered a suitable donor site for lower limb, head and neck or contralateral upper limb lymphedema; in very selective cases, the flap can be used as an ipsilateral pedicled vascularized lymph node flap.

The coronal, sagittal and transverse images of the hybrid SPECT-CT are used to select the most radioactive lower axillary – lateral thoracic lymph nodes. The lymph node flap must be located proximal of the sentinel lymph node(s) of the upper limb, at the deep adipose tissue level and outside of the axillary lymph nodes, above the muscle level, and at the side with the best lymphatic circulation.

Thereafter, using the anatomic landmarks of the anterior axillary line, the level of the ribs, and the depth underneath the skin, the template of the selected lymph nodes are transferred and marked on the skin. With the patient lying having the arms extended above and folded behind the head, which is the same position as at the SPECT-CT examination, we identify the long thoracic artery, and the branches of the serratus anterior and latissimus dorsi thoracodorsal artery, using of a handheld Doppler (*Figure 2a,b*).

A lazy “S” 4 cm skin incision is made parallel of the anterior axillary line over the

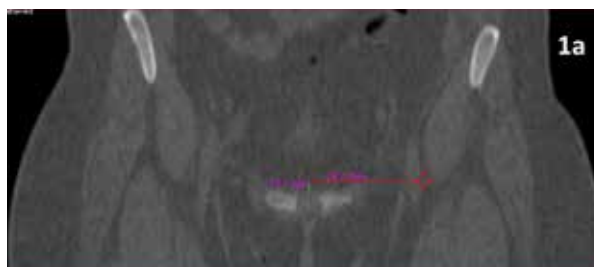
selected lymph nodes. The skin flaps are elevated at the level of the fascia between the superficial and deep subcutaneous adipose tissue, and a pocket about 5X5cm is created centralized around the selected lymph nodes. If possible a 5X5 cm lymph nodal adipose flap is marked, and then the dominant vascular pedicle is identified centrally of the proximal edge of the flap, in respond to preoperative findings of the handheld Doppler and traced towards its origin. After preparing and securing a long pedicle, the flap is elevated at the level of the deep fascia from distal to proximal (*Figure 2c*). A caution should be taken to avoid damage to long thoracic nerve. When flap is fully elevated the pedicle is cut at its longest dimension, and then the free flap is transferred to the lymphedema area.

Pedicle vascularized lymph node flap

In selected cases of early stage breast cancer upper limb lymphedema after sentinel lymph node or sampling lymph nodes excision, and radiotherapy out of the axilla, a SPECT-CT with injections in a crescent fashion around the axilla can identify the potential presence of functional LTLNs. If SPECT-CT indicates that suitable ipsilateral functional lymph nodes exist, and the NIR fluoroscopy demonstrates functional lymphatic vessels up to the proximal arm, then the pedicle vascularized LTLN flap can be used to reinforce the lymphatic circulation of the affected axilla. The technique is aimed to be reinforced by new technology nanopatterned collagen scaffolds, bridging the gap between the flap and the healthy/functional lymphatics of the arm.

In both cases, the donor and recipient sites are closed primarily after placing a No

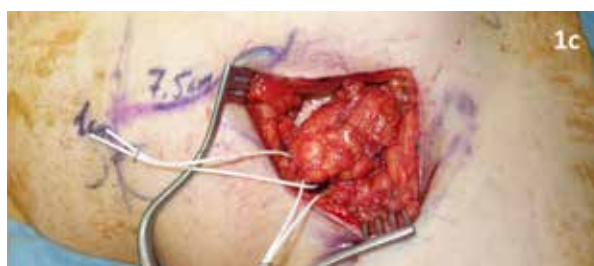Figure 1



1a. SPECT-CT identification of the inguinal selected lymph node

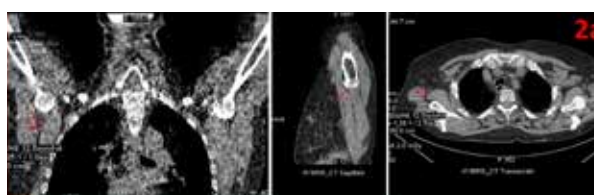

1b. Transferred template onto patient's abdominal wall

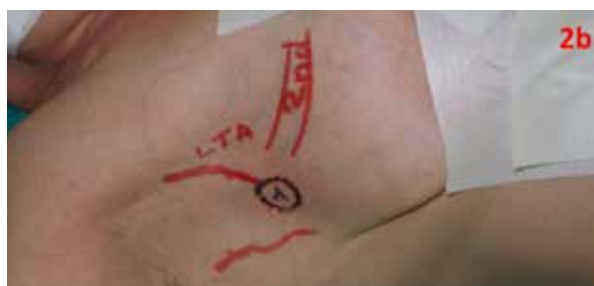

1c. Elevation of the flap according the "SeLyN"

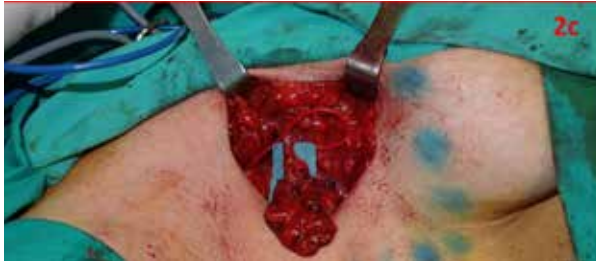Figure 2



2a. SPECT-CT identification of the selected lymph node at the lateral thoracic area



2b. Transferred template onto patient's lateral thoracic zone



2c. Elevation of the flap based on the SPECT-CT findings

12 suction drain. Patients are explained and advised to avoid compression over the operated area for the first 2 weeks. Individualized manual lymphatic drainage through the implanted flap is strongly recommended to start the second postoperative day and continue for the first six months.

REFERENCES

1. Viitanen TP, Visuri MT, Hartiala P, et al. Lymphatic Vessel Function and Lymphatic Growth Factor Secretion after Microvascular Lymph Node Transfer in Lymphedema Patients. *Plast Reconstr Surg Glob Open*. 2013;1:1–9.
2. Dionyssiou D, Demiri E, Tsimponis A, et al. A randomized control study of treating secondary stage II breast cancer-related lymphoedema with free lymph node transfer. *Breast Cancer Res Treat*. 2016;156:73–79.
3. Becker C, Vasile JV, Levine JL, et al. Microlymphatic Surgery for the Treatment of Iatrogenic Lymphedema. *Clin Plastic Surg*. 2012;39:385–398.
4. Patel KM, Chu SY, Huang JJ, Wu CW, Lin CY, Cheng MH. Preplanning Vascularized Lymph Node Transfer with Duplex Ultrasonography: An Evaluation of 3 Donor Sites. *Plast Reconstr Surg Glob Open*. 2014; 2: e193.
5. Sapountzis S, Singhal D, Rashid A, Ciudad P, Meo D, Chen HC. Lymph node flap based on the right transverse cervical artery as a donor site for lymph node transfer. *Ann Plast Surg*. 2014;73:398–401.
6. Becker C, Assouad J, Riquet M, Hidden G. Postmastectomy Lymphedema. Long-term Results Following Microsurgical Lymph Node Transplantation. *Ann Surg* 2006;243:313–315.
7. Vignes S, Blanchard M, Yannoutsos A, Arrault M. Complications of Autologous Lymph-node Transplantation for Limb Lymphoedema. *Eur J Vasc Endovasc Surg*. 2013;45:516–520.
8. Demiri E, Dionyssiou D, Tsimponis A, et al. Donor Site Lymphedema following Lymph Node Transfer for Breast Cancer Related Lymphedema. A Systematic Review of the Literature. *Lymphat Res Biol*. 2017 Oct 31. doi: 10.1089/lrb.2017.0043. [Epub ahead of print].
9. Dayan JH, Dayan E, Kagen A, et al. The use of Magnetic Resonance Angiography in vascularized groin lymph node transfer: An anatomic study. *J Reconstr Microsurg* 2014;30:41–46.
10. Dayan JH, Dayan E, Smith ML. Reverse Lymphatic Mapping: A New Technique for Maximizing Safety in Vascularized Lymph Node Transfer. *Plast Reconstr Surg* 2015;135:277–285.
11. Blum KS, Radtke C, Knapp WH, Pabst R, Gratz KF. SPECT-CT: a valuable method to document the regeneration of lymphatics and autotransplanted lymph node fragments. *Eur J Nucl Med Mol Imaging*. 2007;34:1861–1867.
12. Goldman J, Conley KA, Raehl A, et al. Regulation of lymphatic capillary regeneration by interstitial flow in skin. *Am J Physiol Heart Circ Physiol*. 2007;292:H2176–83.
13. 13) Saaristo AM, Niemi TS, Viitanen TP, Tervala TV, Hartiala P, Suominen EA. Microvascular Breast Reconstruction and Lymph Node Transfer for Postmastectomy Lymphedema Patients. *Ann Surg* 2012;255:468–473.

Dorsal metacarpal arterial flap

8

Sinolichka Djambazova

Clinic for Orthopaedic Surgery, Skopje

Introduction

The dorsal metacarpal artery perforator flap is a versatile solution for resurfacing soft-tissue defects of fingers, dorsum of the hand and web space. The dorsal metacarpal artery flap is classified as a fascio-cutaneous flap. The skin of the dorsum of the proximal phalanx, especially the skin of the index and middle fingers, has been shown to receive axial flow from branches of the first

dorsal metacarpal artery (FDMA) and the second dorsal metacarpal artery (SDMA) vessels that are present in 90% and 97% of hands, respectively. Both these vessels arise from the radial artery or its communications with the dorsal carpal arch, the posterior interosseous artery (PIA), the deep palmar arch, and the ulnar digital artery of the thumb. Use of the dorsal arterial network of the hand to provide skin flaps started with Kuhn and Holevich (Kuhn, 1961; Holevich,

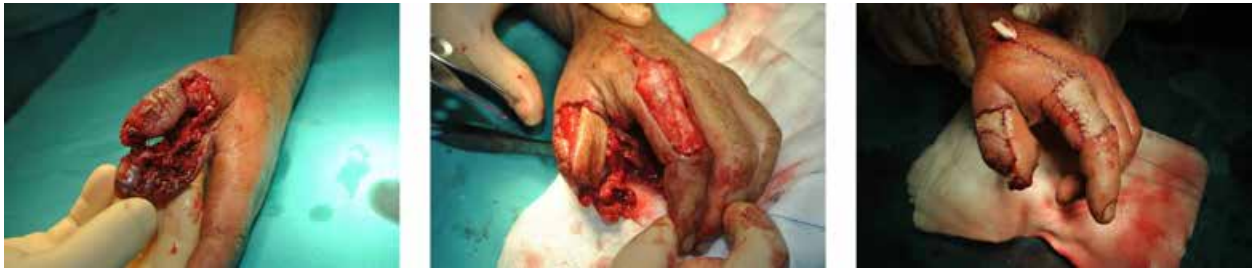1963). Foucher and Braun in 1970 described the first dorsal metacarpal artery flap also known as the kite flap because the flap is raised with the pedicle, which resembles a kite. [1] The kite flap is a skin island flap harvested from the dorsal surface of the adjacent index finger. The constant first dorsal metacarpal artery nourishes the flap. The flap may also incorporate a branch of the superficial radial nerve. This makes the kite flap a good choice for reconstructing all dorsal defects of the thumb and can be used to restore sensibility over thumb pulp defects in a single staged procedure. The disadvantages of this flap may include creating a conspicuous donor-site defect that is closed with a skin graft. Furthermore, when reconstructing the pulp of the thumb, the relatively darker dorsal skin containing hair follicles may produce a less aesthetically pleasing result. In 1987, Earley and Milner first described the proximally based dorsal metacarpal artery flap based on the first and second dorsal metacarpal artery. [2] In 1990, Quaba and Davison introduced another subset of flaps called the distally based dorsal metacarpal artery (DMCA) flap that is not based on the dorsal metacarpal arteries, but rather on a constant palmar-dorsal perforator present in the digital web-space. [3] The DMCA flap became a popular flap for coverage of dorsal finger defects up to the level of the PIP joint. Several flap modifications have been devised since based on the vascular anatomy of the DMCA and the more distal dorso-palmar digital cutaneous perforators in order to increase the span of the flap to reach more distal defects. Primary defect may be simply the wound created by trauma or a wound created by excision of a lesion. However, the skin margins are rarely perfect in a traumatic injury, and generally

the wound margins should be excised back to healthy skin before flap transfer. Similarly, it is important to recreate the original defect in secondary reconstruction, and all scarred skin should be excised so that the flap will be sutured to healthy margins. Because they have qualities identical or similar to the skin lost, local flaps are the most desirable means of providing cover for a defect.

Treatment

The DMCA flap is indicated for large dorsal finger defects or when a one-stage procedure is preferred to allow finger mobilization. The flap can also be used to reconstruct volar defects over the proximal, however this should be discouraged as the transposition of hairy pigmented skin from the dorsal surface of the hand is not an ideal match to the glabrous, lighter-colored skin of the palmar surface of the fingers especially in dark skinned individuals. The flap is usually centered on location of the palmar-dorsal perforator of deep palmar arch.

The boundaries of the flap extends between the distal edge of the extensor retinaculum proximally and the MCP joint distally and the outer borders of the adjoining metacarpals on either side. The flap is harvested from proximal to distal, raising the skin flap above the paratenon of the underlying extensor tendon. The pedicle is traced along the course of the perforator that usually arises immediately distal to the juncture tendinum at the interdigital space. One must not attempt to isolate the perforator as this may lead to its damage and affect flap viability. At this point the tourniquet is released to check flap perfusion. The flap is then rotated and passed through a subcutaneous tun-



nel to reach the defect. The primary defect is closed by primary closure and the fingers and wrist are immobilized in extension. The DMCA flap may be designed as a curved ellipse instead of a straight ellipse. After raising the flap, straightening the curved skin ellipse during flap inset offers additional 8-10 mm length. Another manoeuvre involves dividing and ligating the dorsal metacarpal artery proximal to the perforator. Since a perforator arising from the deep palmar arch directly nourishes this flap. Its attachment with dorsal metacarpal artery can be carefully divided to allow a greater advancement of the flap. The dorsal network communicate with the superficial arch via constant anastomoses. These anastomoses form the basis of the reverse metacarpal flaps which have further enhanced the versatility of this arterial system. The presence of the dorsal metacarpal artery is decreasing from the radial to the ulnar aspect of the hand. The first and second arteries are anatomically constant, making them very safe as a source of pedicle flaps. On the other hand, the third and fourth DMAs are not constant. The fourth dorsal metacarpal artery may be missing in 17-30%. Therefore, Doppler examination prior to flap elevation is mandatory. The second dorsal metacarpal artery flap can be raised as a single lobe flap or can be raised as a bi-lobed flap using the branching vessels in the web space. The arc of rotation of all dorsal metacarpal flaps allow for coverage of proximal defects of adjacent fingers and of smaller defects of the dorsum

of the hand or the wrist area. The second to fourth dorsal metacarpal arteries arise from the dorsal carpal arch. Near their origins they anastomose with the deep palmar arch by proximal perforating arteries and, near their bifurcation, with dorsal perforating branches from the palmar metacarpal arteries which pass between the metacarpal necks. They also anastomose distally at the level of the web spaces with dorsal perforating branches from the palmar digital arteries. The third and fourth dorsal metacarpal arteries are much smaller than the first and second. Cutaneous branches from the dorsal metacarpal arteries supply the dorsal skin as far distally as the proximal interphalangeal joint. At the level of the neck of the second, third and fourth metacarpals, direct cutaneous branch are given off which passes proximally and supplies an area of skin between the two adjacent metacarpals. These anatomical arrangements permit the surgical elevation of flaps of dorsal skin to be based either proximally on the dorsal metacarpal arteries proper, or distally on the direct cutaneous branch. The technique of dissection must take into account the anatomic variations in order to achieve maximum reliability. Thus, the skin covering the dorsal aspect of the MP joint of the index must be included in the island flap, because the terminal branching of the dorsal interosseous artery occurs at this level. The dorsal interosseous artery of the 2nd space may be dominant and terminate in an anastomotic network or it may terminate near the meta-

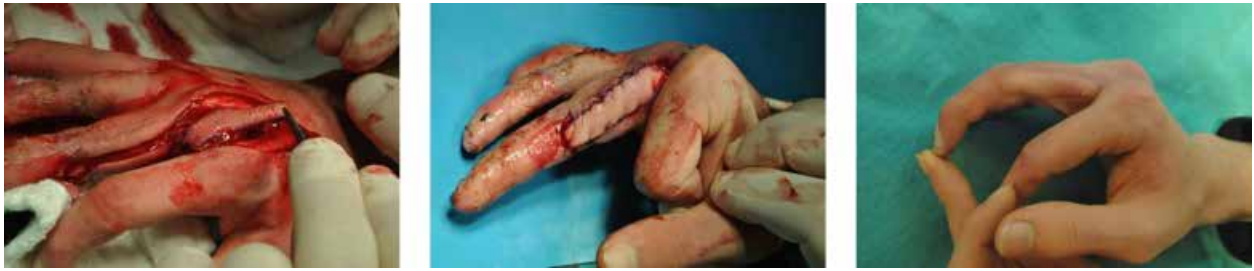carpophalangeal joint. Repairing the transected branch of the radial nerve is necessary, but repairing veins is optional since the deep veins can suffice for venous drainage. At the web space, the second dorsal metacarpal artery has a constant anastomosis with the palmar metacarpal artery, which is doubly significant in flap design. This communicating vessel must be divided if a longer arc of rotation is to be achieved on a proximally based flap, and it also serves as the axial vessel of reversed dorsal metacarpal flaps. The venous drainage of these flaps is excellent, being through either end of the proximal venous arcade, which is of very large caliber. First Dorsal Metacarpal Artery flap is generally designed on the radial side of the distal portion of the second metacarpal or MP joint (or both). The course of the vessel should be run over the first dorsal interosseous muscle from the radial artery as it courses distal to the snuffbox. The flap is elevated distally to proximally. The skin incision is taken to the level of the fascia, and a wide swath of tissue is taken along the course of the artery to prevent damage to the draining veins. No effort is made to isolate the vessels in this flap, or they may well be damaged. If a sensory flap is desired, the branch or branches of the superficial radial nerve to this area of skin may be taken with the pedicle. The fascia is carefully lifted off the first dorsal interosseous muscle to a point near its base to allow rotation of the flap on its pedicle. This flap may be also raised distally based on the perforator near the radial base of the second metacarpal. The arc of rotation of this flap will allow coverage of the index finger to a point near the proximal interphalangeal (PIP) joint. The donor site may be closed primarily (in smaller flaps) or with a skin graft. The second Dorsal Metacarpal Artery Flap is based on the

second dorsal metacarpal artery and venous system in the second interspace. It may be based proximally for coverage of an adjacent dorsal finger or based distally. If it is raised on its proximal pedicle, the rotation point is based near the base of the second metacarpal. The skin on the dorsum of the proximal phalanx can be raised based on these vessels and transferred to the dorsum of the index MP joint for coverage. The dissection proceeds from distally and laterally. The tissue of the second intermetacarpal space is carefully dissected off the interosseous muscle, including the fascia. The dissection is continued proximally, and great care must be taken to prevent damage to the pedicle. The donor site can be closed with a full-thickness skin graft. The second dorsal metacarpal artery flap can be raised as a single lobe flap or can be raised as a bi-lobed flap using the branching vessels in the web space. The arc of rotation of all dorsal metacarpal flaps allows for coverage of proximal defects of adjacent fingers and of smaller defects of the dorsum of the hand or the wrist area.

Conclusion

All flaps survived with good functional results and acceptable cosmetic appearance. Donor site of all dorsal metacarpal flaps were closed directly. Functional and cosmetic results were acceptable.

All flaps survived and the early post-operative periods were uneventful. No donor site complication was encountered with a graft-take of 100%. Donor site morbidity was minimal with an acceptable scar, and tendon gliding under the skin graft was sufficient without producing any deficit in the functions of the index finger. First dorsal



metacarpal artery flap is a good sensate flap for reconstruction of dorsum of the hand, 1st web space and thumb in one stage operation. Donor site graft is acceptable. Second, third and fourth dorsal metacarpal artery flaps has wide range of resurfacing for soft-tissue defects of fingers, web spaces, thumb and distal portion of the dorsum of the hand technique of harvesting is easy and donor site is closed directly in most of cases. Its advantages are simple technique, thin tissue, minimal donor site morbidity, and a good appearance without bulk. Flap transfer to the most distant defects without causing tension to the pedicle is challenging because

of the flap's size limitation. Furthermore, the thin subcutaneous tissue structure while approaching the dorsum of metacarpophalangeal joint, during flap harvest may not allow safe inclusion of such small vessels to the flap. A technical modification during the flap harvest is performed for a more reliable result. With dorsal metacarpal artery flaps, the majority of small-to-medium sized defects of the fingers, thumb and dorsum of the hand can be reconstructed with minimal donor site morbidity and excellent functional and aesthetic results because a tissue defect is replaced with similar tissue type from the immediate anatomic vicinity of the defect.

REFERENCES

1. Hilgenfeldt O.: Operativer D aumenersatz, t ed. Stuttgart, Enke Verlag, 1950.
2. Goffin D., Brunelli F., Galbiatti A., Sammut and Gilbert A.: A new flap based on the distal branches of the radial artery. *Ann. Hand Surg.*, 11: 217-225, 1992.
3. Fouche Gr. and Braun J B.: A new island flap transfer from the dorsum of the index to the thumb. *Plast. Recon. Surg.*, 6 (3): 344-34, 1979.
4. Chen C.L., Chiu H.Y., Lee J.W. and Yang J.T.: Arterialized tendocutaneous venous flap for dorsal finger reconstruction. *Microsurgery*, 15: 886-890, 1994.
5. Vilain R. and Dupuis J.F.: Use of the flag flap for coverage of a small area on a finger or the palm. 20 years experience. *Plast. Recon. Surg.*, 51: 397-401, 1973.
6. Lister G.D.: Skin flaps. In: *Operative Hand Surgery*, 3rd Ed, Churchill Livingstone, New York, 1741-182, 1993.
7. Yousif N., Zhong Y., Sanger J.R., Arria P., Gilbert A. and Matloub H.S.: The versatile metacarpal and reverse metacarpal artery flaps in hand surgery. *J. Hand Surg.*, 21B: 222-22, 1996.
8. Maruyama Y.A.: The reverse dorsal metacarpal flap. *Br. J. Plast. Surg.*, 43: 24-27, 1990.
9. Quaba A.A. and Davison P.M.: The distally based dorsal metacarpal artery flap. *Br. J. Plast. Surg.*, 43: 28-32, 1990.
10. Early M.J. and Milner R.H.: Dorsal metacarpal flaps. *Br. J. Plast. Surg.*, 40: 333-341, 1987.
11. Early M.J.: The second dorsal metacarpal artery neurovascular island flap. *J. Hand Surg.*, 14B: 434-440, 1989.
12. Inoue T., Ueda K., Kurihara T., Harada T. and Harashina T.: A new cutaneous flap: Snuff-box flap. *Br. J. Plast. Surg.*, 252-254, 1993.
13. Williams R.L., Nanchahal J.L., Sykes P.J. and O'Shaughnessy M.: The provision of innervated skin cover for the injured thumb using dorsal metacarpal artery island flaps. *J. Hand Surg.*, 20B: 231-236, 1995.

14. Stice C. and Wood M.B.: Neurovascular island skin flaps in the hand: Functional and sensibility evaluations. *Microsurgery*, 8: 162-167, 1987.
15. Karacalar A. and Ozcan M.: Second dorsal metacarpal artery neurovascular island flap: Clinical applications. *Eur. J. Plast. Surg.*, 18: 153-156, 1995.
16. Onishi K., Maruyama Y. and Yoshitake M.: Transversely designed dorsal Metacarpal V-Y advancement flaps for dorsal hand reconstruction. *Br. J. Plast. Surg.*, 49: 165- 169, 1996.
17. Del Bene M., Petrolati M., Raimond Pi, Tremolada C. and Muset A.: Reversendorsal digital island flap. *Plast. Recon. Surg.*, 93: 552-557, 1994.
18. Mancho C.T.: *The cutaneous arteries of the human body*, Springer Verlag New York, 1983. 78 Vol. 40, No. 1 / Dorsal Metacarpal Artery Flaps
19. Ozcan M., Murat T., Ramaza Kn, Erhahn S. and Selcuk A.: A new flap from the dorsum of the first intermetacarpal area: The first dorsal inter-metacarpal flap. *Proc. EURAPS*, 131-132, 1996.
20. Schools M., Chambo En, Leps P., Millot F., Bahm J. and Lambert F.: The reverse metacarpal flap from the first web. *Europ J. Plast. Surg.*, 16: 26-29, 1993.
21. Marcelo Rosa de Rezende, Rames Mattar Júnior, Álvaro Baik Cho, Oswaldo Hideo Hasegawa and Samuel Ribak: Anatomic study of the dorsal arterial system of the hand *Rev. Hosp. Clin.*, Vol. 59 No. 2, 2004.
22. Loukas M., Holdman D. and Holdman S.: *Folia Morphol (Warsz)*, 64 (2): 78-83, 2005.
23. Caleffi E., Bocchi A., Toschi S. and Ghillani M.: Surgical treatment of post-burn contractures of the hand. *Annals of the MBC*, Vol. 3 - n° 1 - March 1990. 25- David Elliot and Thomas Giesen: Treatment of unfavourable results of flexor tendon surgery: Skin deficiencies. *Indian J. Plast. Surg.*, 16 (46): 325-32, 2013. Volume: 46 Issue: 2 Page: 325-332, 2013.
24. Chao J.D., Huang J.M. and Wiedrich T.A.: Local hand flaps. *J. Am. Soc. Surg.*, 1 (1): 25-44, 2001.
25. Hurren J.S. and Cormack G.C.: The application of the rotation flap to the dorsum of the hand. *Br. J. Plast. Surg.*, 53: 491-4, 2000.
26. Paulo Morais Cardoso, Paulo Santos and Filomena Azevedo: Rotation flap for closure of surgical defect on the dorsum of the hand. *Surg. Cosmet. Dermatol.*, 3 (4): 348- 9, 2011.
27. Quataibah Abdullah Al-Kandari, M.D.: 'X-Plasty' for Post Burn Flexion Contractures of Interphalangeal Joints of All Five Digits of Hand and Adduction Contractures of Axilla. *Egypt, J. Plast. Reconstr. Surg.*, Vol. 32, No. 1, January, 67-69, 2008.
28. Lewis R.C1., Nordyke M.D. and Duncan K.H.: Web space reconstruction with a M-V flap. *J. Hand Surg. Am.* Jan., 13 (1): 40-3, 1988.

Female to male gender confirmation surgery: how i do it

9

Miroslav L. Djordjevic, M.D.,

School of Medicine, University of Belgrade, Serbia

Introduction

The current management of female to male gender confirmation surgery is based on the advances in neophalloplasty, peri-operative care and the knowledge of the female genital anatomy, as well as the changes that occur to this anatomy with preoperative hormonal changes in transgender population. Reconstruction of the neophallus

presents one of the most difficult elements in surgical treatment of female transsexuals.

Metoidioplasty represents a technique for creating a neophallus from hormonally hypertrophied clitoris, in female to male transsexuals. As a one-stage procedure, our approach includes lengthening and straightening of the clitoris to make a neophallus, urethral reconstruction to enable voiding

while standing, and scrotal reconstruction with insertion of testicular implants.

Phalloplasty is one of the most difficult surgical procedures in genital reconstructive surgery and general agreement for the ideal technique includes: cosmetically acceptable result for patient and partner, voiding while standing, penetrative sexual intercourse, erogenous and tactile sensitivity, and minimal scarring of donor area. Musculocutaneous latissimus dorsi (MLD) free flap presents one of the good options for neophalloplasty in female to male transsexuals who require an adult-sized phallus. It enables urethral reconstruction using various flaps (vaginal, labial, clitoral flaps) and grafts (buccal mucosa graft) and insertion of either semirigid or inflatable penile prosthesis.

Description of the procedure

1. Metoidioplasty

Patient is placed in gynecological position, prepped and draped in standard sterile surgical fashion. Foley urinary catheter is introduced and suprapubic tube is placed into the bladder for urine drainage. Vaginectomy is done by colpocleisis, and small part of anterior wall near urethral meatus is preserved to be used as a flap for upcoming urethral reconstruction. Vaginal space is closed by anterior-to-posterior approximation using 1-vicryl interrupted sutures.

Circular incision is made at the border between the inner and outer layer of the clitoral prepuce, and carried out around the urethral plate and native urethral meatus. Clitoral degloving is performed to expose clitoral body and dorsal fundiform and suspensory ligaments. Clitoral ligaments are completely de-

attached from the pubic bone to advance and lengthen the clitoris. Ventrally, the short urethral plate is dissected from the clitoral body, including bulbar part around the native meatus to enable its good mobility for urethral reconstruction. Since the urethral plate is short, causing ventral curvature of the clitoris, it is divided at the level of glanular corona to achieve complete straightening and lengthening of the clitoris.

Reconstruction of the urethra starts with reconstruction of its bulbar part. A well-vascularized periurethral flap is harvested from the anterior vaginal wall, with the base close to the urethral meatus, and joined with the proximal part of the divided urethral plate with interrupted sutures, forming the bulbar part of the neourethra. Further urethral lengthening is done by combined buccal mucosa graft and vascularized genital flaps (labia minora skin flap or clitoral skin flap).

Buccal mucosa graft is harvested from the left inner cheek. Ellipse-shaped graft of appropriate size is marked, keeping the margin away from Stenson's duct and at least 1 cm away from the vermillion border. Size of the graft depends on the distance between the tip of the glans and native urethral meatus. Graft is harvested superficially to the buccinator muscle and de-fated with scissors while it is stretched over the index finger. The graft is fixed to the ends of divided urethral plate to cover the gap, and additionally quilted to the corporeal bodies for better survival of the graft, with 5-0 monocryl interrupted sutures. A good vascularized skin flap is harvested from labia minora. Its dissection starts from the vaginal vestibulum and goes upward to the clitoral glans. The lateral margin of the flap is designed along the border between the inner and outer labial surface. Pedicle of the flap is additionally mobilized

and lengthened from the subcutaneous tissue of the labia majora to enable suturing with buccal mucosa graft without tension. The margins of labia minora flap are finally joined to the margins of buccal mucosa graft by two lateral 5-0 monocryl running sutures. Neourethra is additionally covered with one layer of well-vascularized genital tissue preventing superposition of the sutures and fistula formation.

The glans is then opened in the midline and both glans wings are dissected extensively to enable glans approximation without tension and advancement of the neourethra with new meatus at the tip of the glans. A perforated 14Fr silicone tube is placed into the new urethra to be used for buccal mucosa moisturizing and to maintain lumen of the neourethra. Available clitoral and labia minora skin is used to cover the shaft of the neophallus.

Both labia majora are joined in the midline to create the scrotum. Incision is made at the top of each labia majora and subcutaneous pockets are created for testicular prosthesis. Appropriate size silicone testicular implants are inserted, irrigated with antibiotic solution, and the pockets are closed in two layers, finalizing the scrotoplasty. Self-adhering wrap is placed around the neophallus, and compressive dressing is applied on the scrotal and perineal region.

2. Phalloplasty

Patient is placed in gynecological position, prepped and draped in standard sterile surgical fashion. Vaginectomy, as well clitoral lengthening and straightening is done at the same way as in metoidioplasty. Reconstruction of the urethra is done by using all vascularized genital hairless tissue: both labia minora, clitoral skin and urethral plate.

A well-vascularized peri-urethral flap is harvested from the anterior vaginal wall, with the base close to the urethral meatus, and joined with the proximal part of the urethral plate with interrupted sutures, forming the bulbar part of the neourethra. Both labia minora and available clitoral skin are dissected with long pedicle and used for further urethral tubularization, creating neourethra approximately 15 cm long. In this way, new urethral opening is placed as far as possible into the neophallus. Both labia majora are joined in the midline to create the one-sac scrotum and silicone testicular implants are inserted. Skin incision ("Y" shape) is made at the midline at the mons pubis region for further fixation of the neophallus. Inguinal incision is made, and the superficial femoral artery, saphenous vein and the ilioinguinal nerve are identified, dissected and mobilized. Finally, wide tunnel is created between the incisions of mons pubis and inguinal region by sharp and blunt dissection.

The patient is placed in the lateral decubitus position to provide access to thoracic donor area. Flap design starts with marking the anterior and superior muscle margin. The projection of the thoracodorsal artery is defined and the flap is marked with the base positioned over its hilum and extending 5–7.5 cm on either side of the artery. The flap dimensions are created according to the adult penile size: 11–13 cm wide and 13–17 cm long. Flap harvesting starts with an incision of the anterior skin margin down to the deep fascia, along the plane between latissimus dorsi and serratus anterior muscles, using sharp and blunt dissection. The flap is divided inferiorly and medially, cauterizing the large posterior perforators of the intercostals vessels, and then lifted to expose the neurovascular pedicle (thoracodorsal artery, vein

and nerve). The pedicle, surrounded by fatty tissue, is identified and dissected proximally up to the axillary vessels. The thoracodorsal nerve is identified and isolated proximally for 3-4 cm, preserving its vascularization. The latissimus muscle is fixed to the margins of the skin at several points with interrupted absorbable sutures to prevent layer separation during further dissection. The flap is tubularized creating the neophallus while still perfusing on its vascular pedicle. The circular terminal part is rotated back over the distal body and sutured to create a neoglans.

The constructed neophallus is de-attached from the axillar region and wound margins of the donor site are undermined, approximated and closed directly, using 2-0 vicryl mattress stitches. If significant tension is present that may compromise healing of the donor site, a split thickness skin graft is used for defect covering. Donor and recipient areas are covered with sterile dressing in standard fashion, with compression applied only to the donor site.

The neophallus is transferred to the recipient area and its' pedicle is transferred through previously created tunnel to recipient vessels. Microsurgical anastomoses are created between the thoracodorsal and femoral artery (latero-terminal), and the thoracodorsal and saphenous vein (termino-terminal) using operative loupes, with 7-0 prolene interrupted suture. The epineural micro-neurorrhaphy is done between the ilioinguinal and thoracodorsal nerve. Inguinal incision is closed with skin stapler device. The neophallic base is fixed to the skin at the recipient site, using 3-0 vicryl mattress stitches. Clitoral glans is fixed under the base of the neophallus.

Second stage includes insertion of penile prosthesis and further urethral lengthening. The infrapubic or/and the penoscrotal ap-

proaches can be used for penile prosthesis implantation into the neophallus. In case of infrapubic approach, a longitudinal or transverse incision is made below the pubis, just above the base of the neophallus. Otherwise, a vertical or a transverse incision is made ventrally at the penoscrotal junction, and all layers are opened longitudinally allowing good visualization of all structures, especially the urethra. Hegar dilators are then used to create the space for insertion of the semi-rigid or inflatable prosthesis. After implantation, the prosthesis is covered with vascular grafts imitating tunica albuginea to prevent protrusion through the glans. The prosthesis is additionally fixed to the periosteum of the inferior pubic rami. The pump of the inflatable prosthesis is inserted into the scrotum using a small incision above the scrotum. The incisions are closed with absorbable sutures.

Buccal mucosa graft is used for neophallic urethral reconstruction. It is harvested from the inner cheek using standardized procedure. Buccal mucosa grafts are placed on the ventral side of the neophallus to create distal urethral plate, and fixed to the surface with 4-0 vicryl interrupted U-sutures. Before tubularization, buccal mucosa grafts are treated with hydratant cream for moisturizing and softening. The final stage of urethral reconstruction should be performed when the formed urethral plate has matured enough to be supple and more easily mobilized for tubularization. New formed distal urethral plate is mobilized and tubularized with absorbable running suture, over the Foley catheter. Proximally, it is anastomosed with proximal neourethra with interrupted stitches, and distally new meatus is formed, closer to the glans as possible. Surrounding vascularized tissue is mobilized to cover and support the neourethra.

Conclusions

Finally, metoidioplasty or phalloplasty, that is the question? The choice lies in satisfying the patient's desires and understand-

ing their needs. Transgender surgeon plays a very important role in explaining the pros and cons of each procedure, considering each individual as unique case and presenting the best surgical option.

REFERENCES

1. Djordjevic ML, Stanojevic D, Bizic M, et al. Metoidioplasty as a single stage sex reassignment surgery in female transsexuals: Belgrade Experience. *J Sex Med.* 2009;6:1306-13.
2. Djordjevic ML, Bizic M, Stanojevic D, et al. Urethral lengthening in metoidioplasty (female to male sex reassignment surgery) by combined buccal mucosa graft and labia minora flap. *Urology*, 2009;74:349-53
3. Djordjevic ML, Bizic MR. Comparison of two different methods for urethral lengthening in female to male (metoidioplasty) surgery. *J Sex Med.* 2013;10:1431-8.
4. Stojanovic B, Djordjevic ML. Anatomy of the clitoris and its impact on neophalloplasty (metoidioplasty) in female transgenders. *Clin Anat.* 2015; 28:368-75.
5. Djordjevic ML, Bumbasirevic MZ, Vukovic PM, et al. Musculocutaneous latissimus dorsi free transfer flap for total phalloplasty in children. *J Ped Urol* 2006; 2:333-9.
6. Perovic SV, Djinoic R, Bumbasirevic M, Djordjevic M, Vukovic P. Total phalloplasty using a musculocutaneous latissimus dorsi flap. *BJU Int.* 2007;100:899-905.
7. Djordjevic ML. Primary and secondary reconstruction of the neophallus urethra. In: Brandes SB and Morey AF, Eds. *Advanced male urethral and genital reconstructive surgery*, 2nd Edition. New York: Humana Press; 2014:493-505.

Male to female gender confirmation surgery: how i do it

10

Miroslav L. Djordjevic, M.D.,

School of Medicine, University of Belgrade, Serbia

Introduction

Vaginal absence has a devastating impact on a biological woman or male-to-female transgenders. Thus, in such cases, it is essential to (re)create a normal functioning neovagina with a satisfactory sexual function and esthetical appearance. Vaginal reconstruction is inevitable in the case of vaginal agenesis, disorders of sexual development, transsexualism, defects resulting

from genital cancer surgeries and trauma. There are many reports on different surgical procedures, their outcomes following post-operative complications and anatomical and functional results. Some popular methods include split and full-thickness skin grafts, bladder or buccal mucosa grafts, penile or penoscrotal skin flaps, local genital flaps, and intestinal flaps. Skin grafts are used frequently due to their simplicity and fewer complications.

In transsexual patients, with preserved penis and scrotum, use of penile and penoscrotal skin flaps remains the method of choice. However, these methods have certain disadvantages, such as scarring, shrinkage, insufficient vaginal cavity, intravaginal hair growth, as well as a need for lubrication during intercourse and permanent dilation. The debate on surgical management of this condition, with the very large number of techniques that have been described continues and there is still considerable controversy over the choice of the best technique.

The aesthetic, sensational, and functional results of vaginoplasty vary greatly. Surgeons vary considerably in their techniques and skills, patients' skin varies in elasticity and healing ability, previous surgery in the area can impact results, and surgery can be complicated by problems such as infections, blood loss, or nerve damage. However, in the best cases, when recovery from surgery is complete, it is often very difficult for anyone, including gynecologists, to detect women who have undergone vaginoplasty. Supporters of colovaginoplasty argue that this method is better than use of skin grafts because the colon is already mucosal, whereas skin is not. In our center for transgender surgery, inverted penile skin flap technique still remains the first choice for vaginoplasty in transsexuals.

Description of the procedure

In order to form the new vagina, several subprocedures have to be performed: orchiectomy, removal of corpora cavernosa, creation of neovaginal cavity, vaginoplasty, lining of the cavity with urethral orifice and vaginal introitus, clitoroplasty and labioplasty. After the usual bilateral orchidectomy, the

penis is dissected into its anatomical components, i.e. the corpora cavernosa, the glans cap with the urethra and the neurovascular bundle, and the vascularized penile skin. This principle, so-called the penile disassembly technique, presents the main advantage since it allows the ideal use of all penile components (except the corpora cavernosa) in the construction of the new vulva, clitoris and vagina. The glans, with neurovascular bundle dorsally and urethra ventrally, is lifted from the tips of the corpora cavernosa together with Buck's fascia, thus completely preserving these components. As the glans cap is divided into two, the dorsal part of the glans is reduced by excising the central ventral tissue, leaving the sides of the glans intact. This part is used to create the neoclitoris. The other, ventral half of the glans, which remains attached to the urethra, is used to form the neocervix at the base of the new vagina. The penile disassembly also provides ideal exposure of the corpora cavernosa for their removal at the level of attachment to the pubic rami. Short remnants of the corpora cavernosa (erectile tissue) are also destroyed to prevent any postoperative erection that could hinder sexual intercourse. The vascularized urethral flap is essential for the present vaginoplasty; it is of adequate length and is therefore never the limiting factor. The corpus spongiosum of the urethra is completely preserved and ensures an excellent blood supply. The bulbospongiosus muscle is removed from the bulbous part of the urethra; the dissection of the bulbar urethra must be precise to avoid injury to the fascial sheath. The urethra is then spatulated, including the bulbar part, and used to create the mucosal anterior part of the neovagina. Also, the urethral flap allows for a wider neovagina, especially the introitus.

Any bleeding in the bulbar urethra is controlled with haemostatic sutures. The extensive use of electrocautery is not recommended as the urethral flap vascularization could be compromised. A female type urethra is then formed and the neoclitoris fixed above the new urethral meatus. In reconstructing the new vagina, the skin of the penile body and prepuce (if present) are fashioned into a vascularized island tube flap. As it is important to obtain a long vascularized pedicle for the tube, the incision is made at <2 cm above the base of the mobilized penile skin. Only here does the existing loose subcutaneous tissue permit the formation of a long vascularized pedicle. A hole is made at the base of the pedicle to transpose the urethral flap and neoclitoris. On the dorsal side of the skin tube flap only the skin is incised whereas the vascularized subcutaneous tissue remains intact. The urethral flap, which is transposed through the pedicle hole, is embedded into the skin tube and sutured. The bottom of the tube is closed with the distal part of the urethra and/or the remaining ventral half of the glans cap after the de-epithelialization of its inner side. The tube, consisting of skin and urethral flap, is inverted, thus forming the new vagina.

The space for the new vagina is created in the perineum; two tunnels are made on both sides on the tendineus center; this and the recto-urethral muscle are cut, allowing access to the deep and wide perineal cavity between the urethra, bladder and rectum. Particular care should be taken to avoid injuring the rectum. Prolapse of the urethral part of the vagina is completely avoided with vaginal fixation to the sacrospinous ligament, as is an exaggerated posterior vaginal fourchette. Engorgement of the bulbar urethra during sexual arousal is moderate and does

not present a barrier to intercourse. Contrary to transvaginal sacrospinous ligament fixation for treating vaginal prolapse in true females, there are significant difficulties in using this procedure in male transsexuals. Good exposure and direct visualization of the sacrospinous ligament is crucial to prevent injury to the rectum, pudendal nerve, internal pudendal artery and vein; extensive experience of male pelvic surgery is required. Transposing the vagina to the fixed side has no clinical consequences in male transsexuals, as the distance between the sacrospinous ligaments is shorter than in females. Using the ischial spine as a prominent landmark, sacrospinous ligament is palpated as it passes from the ischial spine to the lower part of the sacrum. After exposing the ligament, a long-handled Deschamps ligature carrier pre-loaded with 2/0 delayed absorbable suture is used to pierce the ligament medially to the ischial spine. Care must be taken not to place the suture close to the ischial spine, to prevent injury of the pudendal nerve and internal pudendal vessels. Also, the suture must not be placed behind the ligament, to prevent injury to the pudendal artery, as its course is variable and may be at any distance from the ischial spine. Both ends of the suture are brought out; one is passed through the skin part while the other is passed through the urethral part of the distal third of the neovagina and the fixation stitches are tied firmly. The right sacrospinous ligament was used in all cases; no bilateral fixations were performed. It is technically easier for a right-handed surgeon to use the right ligament. Vaginopexy to the sacrospinous ligament is performed and the neovagina placed deep in the perineal cavity. This provides a good placement of the neovagina and ensures that a prolapse is avoided.

Vulvoplasty involves the creation of the labia minora and majora. The remaining part of the base of the penile skin is used to form the labia minora, which are sutured to the de-epithelialized area of the neoclitoris; thus the neoclitoris is hooded with labia minora. Excessive scrotal skin is removed and the remaining part used to form the labia majora.

A peri-vaginal Jackson-Pratt drain is left in for 3 days. The neovagina is packed for 7 days and an indwelling Foley catheter is kept in place for 7-10 days. Antibiotics (cephalosporins, metronidazole) are administered for the first 5-7 days postoperatively. Vaginal packings (a condom filled with soft material, petrolatum gauzes) are placed in the neovaginal cavity for 48 hours to a week after surgery and followed by vaginal stenting at night for 6 weeks. At discharge from hospital, patients are instructed to irrigate the neovagina once a day for two months and

to dilate the introitus of the neovagina on a daily basis with a vaginal dilator set.

Conclusions

Reconstruction of female genitalia in male transgender patients generally presents a safe and reasonable choice with acceptable complications and satisfactory results. Although a consensus on the ideal method of vaginoplasty may never be reached, efforts should be made on selecting the optimal method of long-term follow up for these patients. Despite the fact that penile skin flap inversion vaginoplasty is largely standardized as a primary option, new refinements are needed to satisfy specific patients requests related to the functioning of the neovagina as well as the best possible aesthetic outcomes.

REFERENCES

1. Perovic SV, Stanojevic DS, Djordjevic ML. Vaginoplasty in male transsexuals using penile skin and urethral flap. *BJU Int* 86:843-50, 2000
2. Vujovic S, Popovic S, Sbutega-Milosevic G, Djordjevic M, Gooren L. Transsexualism in Serbia: a twenty-year follow-up study. *J Sex Med* 6(4):1018-23, 2009
3. Stanojevic DS, Djordjevic ML, Milosevic A, et al. Sacrospinous ligament fixation for neovaginal prolapse prevention in male-to-female surgery. *Urology* 70(4):767-71, 2007
4. Djordjevic ML, Stanojevic DS, Bizic MR. Rectosigmoid vaginoplasty: clinical experience and outcomes in 86 cases. *J Sex Med* 8(12):3487-94, 2011
5. Labus LD, Djordjevic ML, Stanojevic DS, Bizic MR, Stojanovic BZ, Cavic TM. Rectosigmoid vaginoplasty in patients with vaginal agenesis: sexual and psychosocial outcomes. *Sexual Health* 8(3):427-30, 2011

Alexandru Valentin Georgescu

Professor in Plastic Surgery
University of Medicine Iuliu Hatieganu
Cluj Napoca, ROMANIA

Introduction

The most frequent etiology of limbs' bone defects is represented by comminuted open fractures and their complications, i.e. non-union, osteomyelitis, but also by oncological resections¹. One of the possibilities to solve such cases, especially when associated with big soft tissue defects, is the vascularised rib (R) as part of a composite muscle-bone flap including either the latissimus dorsi (LD), serratus anterior (SA), or both of them [1-10].

Due to the common blood supply through the thoracodorsal artery, both the LD and SA can be included in the flap, what provides a huge amount of tissue and is very useful for large and/or deep complex defects [10-12].

Due to its dimensions, the SA-R flap is a very good option for metacarpal and metatarsal reconstruction^{9,13}. Even if the cross-sectional area of the rib is not enough for the reconstruction of big bones, the use of two ribs segments can solve the problem [10,11,14].

Both the LD-rib and SA-rib flap can be transferred free or pedicled. The pedicled variant can be successfully used for the reconstruction of the upper half of the humerus. The free variant can be used in the reconstruction of bone defects all over the body, but the main indication remains the metacarpal bone defects.

The main drawbacks by using these flaps are related to rib curvature and strength, and to some possible complications, i.e. opening of the pleural cavity and scapula alata.

Anatomy and surface markings

According with the classification of Mathes and Nahai [15], this flap is an osteo-muscular or osteo-musculo-cutaneous flap of type V – latissimus dorsi, or of type III – serratus anterior.

The thoracodorsal artery (TDA) (*Figure 1*) originates from the subscapular artery, and after a mean distance of about 8.5 cm (range 6-11.5 cm) enters, together with the thoracodorsal vein and nerve, into the deep aspect of the LD muscle. In the great majority of cases, the artery bifurcates into the muscle in a medial branch, which runs parallel to the upper margin of the muscle, and a lateral branch, which runs parallel to the lateral margin of the muscle. Both these branches give within the muscle, in its medial part (at about 8-10 cm from the midline), smaller branches which realize large caliber anastomoses with perforators from the lumbar and, more important, intercostal arteries (ICA). Before entering the LD muscle, the TDA gives up to three branches to the SA muscle, which vascularize mainly its lower three-four slips. The TDA has a caliber of 2-3mm, and the toracodorsal vein a caliber up to 3.5mm.

The ribs are blood supplied both through the nutrient vessels from the posterior ICA and the periosteal blood supply coming from the TDA through the SA muscle.

For both LD-R and SA-R flaps, the first step is to identify and mark the lateral border of the LD muscle: for it to become visible, patient is asked to place the hand on the iliac crest and push inward toward the midline (*Figure 2*); this will be the incision line.

Technique of harvesting

Positioning

The positioning of the patient is in lateral decubitus, with the arm abducted 90° and the forearm flexed 90°.

Raising the flap

There are some differences between LD-R (*Figure 3*) and SA-R harvesting (*Figure 4*).

Step 1

A 10-12 cm incision to the LD fascia is made on the previously marked line, and the lateral border of the muscle is identified (*Figure 3 a, b*).

Step 2

LD - the skin is undermined, and so the entire superficial aspect of muscle is uncovered.

SA - both the thoracic skin anterior, and the LD posterior are undermined.

Step 3

LD - the muscle undermining begins in the middle part of the lateral border, and continues initially towards caudal and medial. During the dissection attention must be paid to

the identification of the intercostals muscular perforators which penetrate the LD at about 8-10 cm from the midline. The perforator with the larger diameter will be chosen as vascular pedicle of the rib which will be harvested (8th, 9th, or 10th). Now, the distal and medial part of the muscle are transected, and the dissection is continued proximally until the identification of the TDA and its branches for LD and SA, the last one being tied off and transected. The TDA is dissected as long as needed.

SA - the TDA branch for SA is identified and dissected to the level of the muscle slips that would be harvested, paying attention to preserve its motor nerve. These slips have to be carefully isolated from the surrounding tissues to preserve the musculo-periosteal connections.

Step 4

LD - the rib to be harvested is prepared by doing an incision 1-2 mm parallel with both its sides, as long a segment as needed, and a transversal transperiosteal incision at both ends of the segment. The upper and lower borders of the rib segment are carefully identified in order to preserve the pleura and the perforator vessel, and the deep aspect of the rib is undermined subperiosteally, so to leave the periosteum in contact with the parietal pleura. Then the rib is resected, and its periosteum is secured with some stitches to the muscle, to avoid the damage of the perforator vessel.

SA - the muscle slips and the rib are measured, prepared and resected following the same maneuvers as for the LD. It is better to leave in place the slip/s insertion onto the scapula and a small part of the muscle (about 3-4 cm).

Step 5

The LD muscle segment or the SA slip/s to be harvested are prepared, and then re-

sected with as long a vascular pedicle as needed.

Step 6

LD - a drainage tube is placed close to the rib gap and under the skin, and the donor site is directly sutured.

SA - a drainage tube is placed in the remaining space after harvesting the rib segment, in contact with the parietal pleura, and, to prevent the winged scapula, the remaining posterior portions of the used slips are sutured to the periosteum of the superjacent and subjacent ribs. A second drainage tube is placed under the skin, and the donor site is directly sutured.

Step 7

For LD, the flap is applied to the defect. First, the rib segment is placed into the bone defect and the bone fixation is done according with the bone and type of defect. Then, the muscular component is secured to the recipient site with some stitches, and the flap is revascularized by microsurgical anastomosis. The muscle can be immediately grafted with intermediate split-skin grafts, but it is better to delay this procedure for 3-4 days.

For SA, idem as for the LD, but with only one difference: because the vascular pedicle of the flap lies on the superficial aspect of the muscle, this one must be skin grafted immediately.

N.B. - In large defects, because of the common source of vascularization, it is possible to use both the LD and SA muscle flaps including one or more rib segments, as a composite flap. In these cases the rib is better to be part of the SA muscular component. The harvesting of such a composite flap respects the same steps as above.

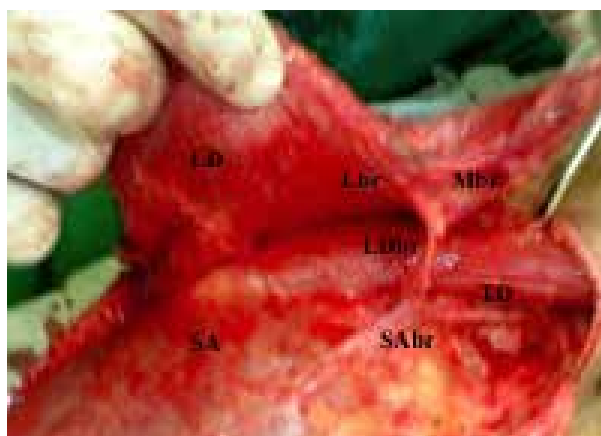- Adding a skin component to the flap should be avoided, especially in the forearm and hand, because of the final bulky appearance.

Some tips and tricks

- Ensure a good haemostasis to prevent the postoperative haematoma of the donor site.
- Well identify and preserve the LD and SA motor nerves.

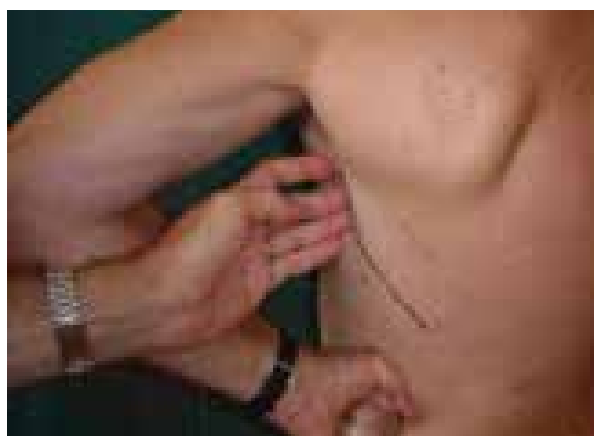- Ensure meticulous subperiosteal dissection of the deep aspect of the rib. If the pleura is opened, it can be sutured, and a drainage tube under negative pressure is placed in the pleural cavity.
- Secure the rib to the muscle with some stitches.
- Prevent the winged scapula by suturing the preserved SA muscular stump to the superjacent and subjacent ribs.

Figure 1



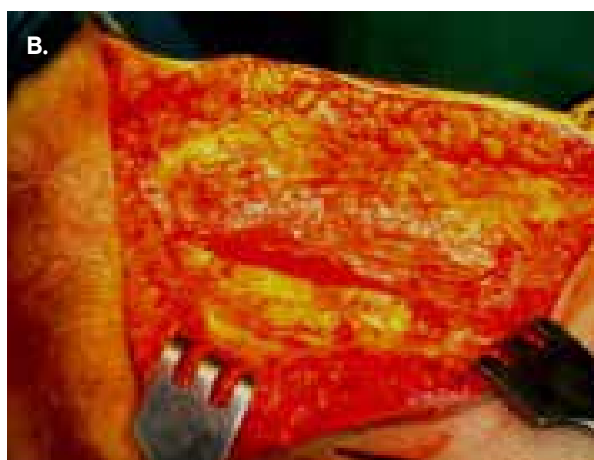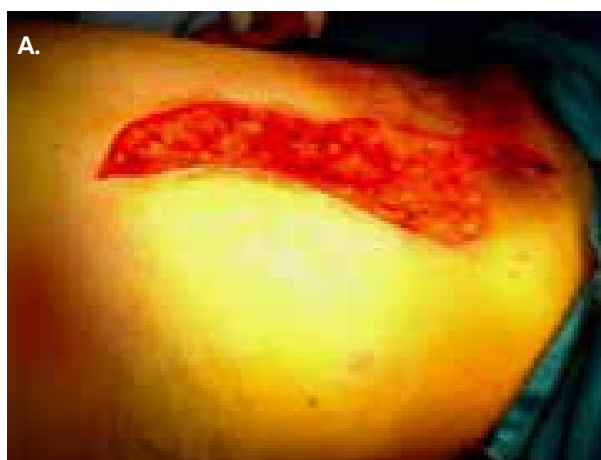1. Thoracodorsal artery and its branches: LD-latissimus dorsi, SA-serratus anterior, TDA-thoracodorsal artery, LDbr-TDA' branch for LD, Mbr-medial branch of the TDA, Lbr-lateral branch of the TDA, SAbr-TDA' branch for SA

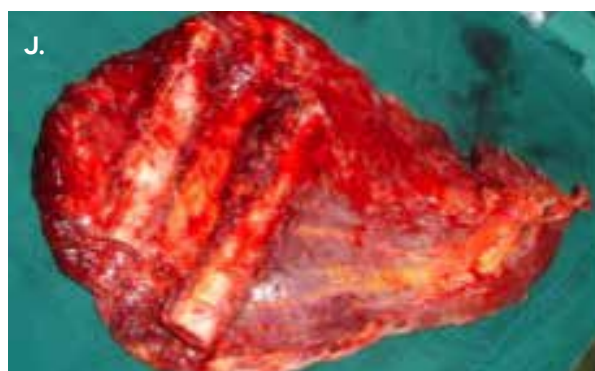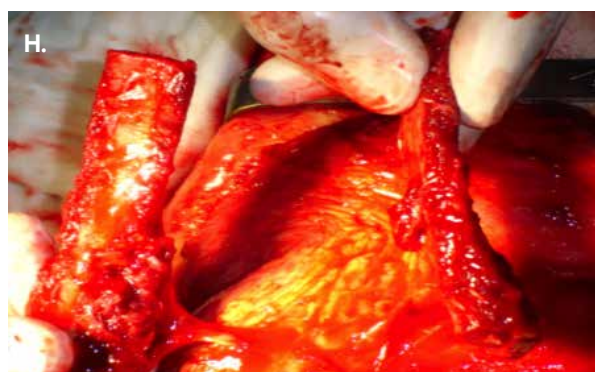
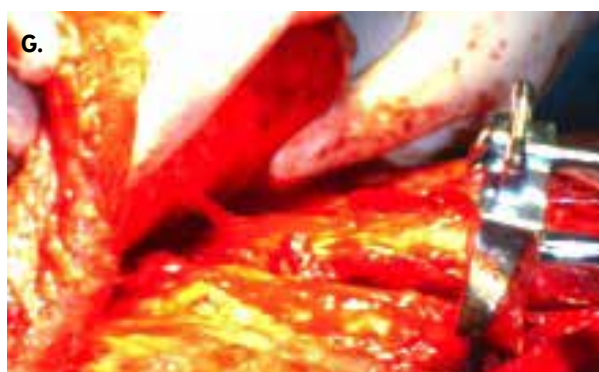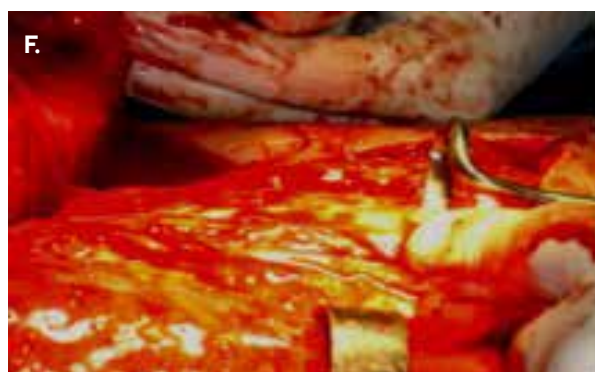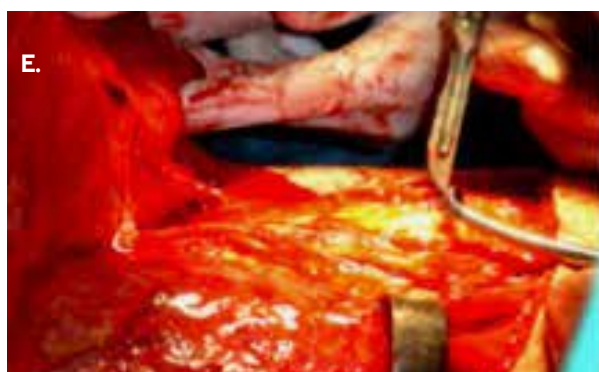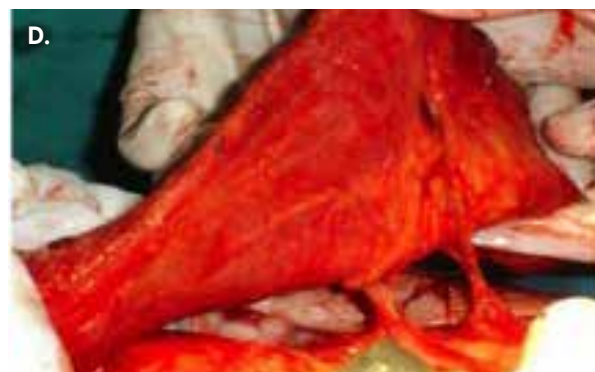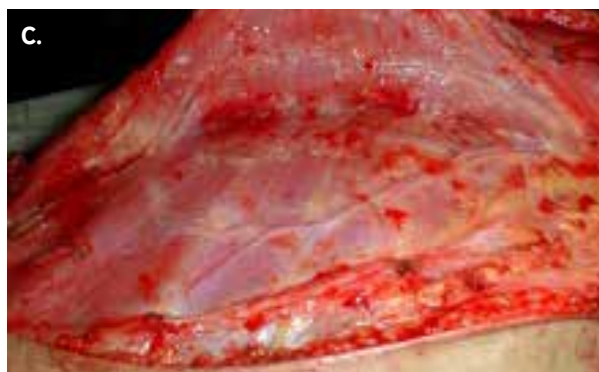Figure 2



2. Preoperative marking: Identification of the lateral border of LD and marking the line of incision.

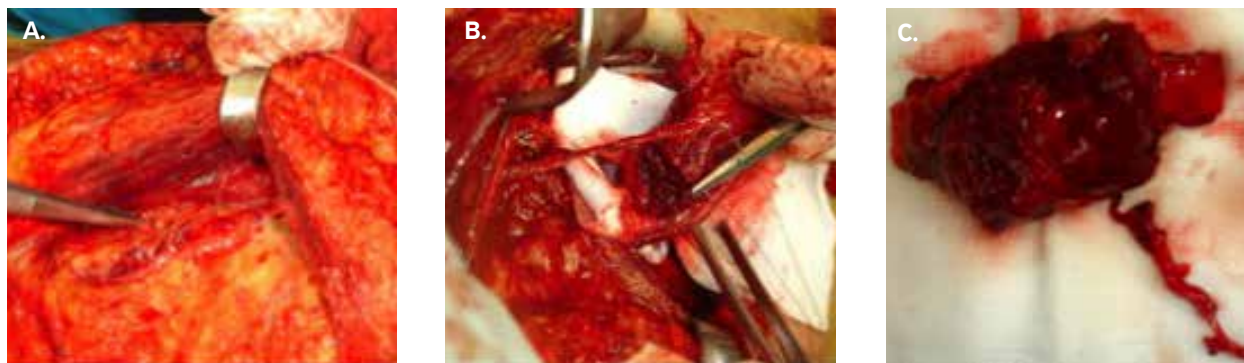
Figure 3





3. The harvesting of LD-rib flap: **A.** Skin incision. **B.** Identification of the lateral border of the muscle and skin undermining. **C.** Muscle undermining. **D.** Identification and isolation of the main musculo-periostal perforators. **E.** The rib to be harvested is prepared by doing an incision 1-2 mm parallel with both its sides, as long a segment as needed, and a transversal transperiostal incision at both ends of the segment. **F.** Subperiostal undermining of the deep aspect of the rib. **G.** Resection of the rib. **H.** Two harvested rib segments: the musculo-periostal perforators are shown. **I.** The rib donor site defect, with the remaining deep periosteum in contact with the parietal pleura. **J.** The flap ready for free tissue transfer.

Figure 4



4. The harvesting of SA-rib flap: **A.** The LD only is undermined, and the first step is the identification of the TDA branch for the SA. **B.** The harvested rib segment is secured with some stitches to the SA, to prevent the damage of the musculo-periosteal connections. **C.** The flap ready for free tissue transfer.

REFERENCES

1. Lin C-H, Yazar S. Revisiting the serratus anterior rib flap for composite tibial defects. *Plast Reconstr Surg* 2004;114:1871–1877
2. Guelinckx PJ, Sinsel NK. The “Eve” procedure: the transfer of vascularized seventh rib, fascia, cartilage, and serratus muscle to reconstruct difficult defects. *Plast Reconstr Surg* 1996;97:527–535
3. Lin C-H, Wei F-C, Levin LS, Su J-I, Fan K-F, Yeh W-L, Hsu D-T. Free composite serratus anterior and rib flaps for tibial composite bone and soft-tissue defect. *Plast Reconstr Surg* 1997;99:1656–1665
4. Thomas WO, Harris CN, Moline S, Harper LL, Parker JA. Versatility of the microvascular serratus anterior muscle vascularized rib flap (SARIB) for multifaceted requirement reconstructions. *Ann Plast Surg* 1998;40:23–27
5. Hui KCW, Zhang F, Lineaweaver WC, Moon W, Buncke GM, Buncke HJ. Serratus anterior-rib composite flap: anatomic studies and clinical application to hand reconstruction. *Ann Plast Surg* 1999;42:132–136
6. Brenner P, Zwipp H, Rammelt S. Vascularized double barrel ribs combined with free serratus anterior muscle transfer for homologous restoration of the hindfoot after calcanectomy. *J Trauma* 2000;49:331–335
7. Chang DW, Miller MJ. A subperiosteal approach to harvesting the free serratus anterior and rib myo-osseous composite flap. *Plast Reconstr Surg* 2001;108:1300–1304
8. Pelissier P, Pistre V, Casoli V, Martin D, Baudet J. Reconstruction of short lower leg stumps with the osteomusculocutaneous latissimus dorsi-rib flap. *Plast Reconstr Surg* 2002;109:1013–1017
9. Georgescu AV, Ivan O. Serratus anterior-rib free flap in limb bone reconstruction. *Microsurgery* 2003;23:217–225
10. Georgescu AV, Ignatiadis I, Matei I, Capota I, Ardelean F, Olariu R. Long-term results after muscle-rib flap transfer for reconstruction of composite limb defects. *Microsurgery* 2011;31:218–222
11. Lin C-H, Wei F-C, Levin LS, Su J-I, Fan K-F, Yeh W-L, Hsu D-T. Free composite serratus anterior and rib flaps for tibial composite bone and soft-tissue defect. *Plast Reconstr Surg* 1997;99:1656–1665
12. Georgescu AV, Ivan O. Emergency free flaps. *Microsurgery* 2003;23:206–216
13. Hui KCW, Zhang F, Lineaweaver WC, Moon W, Buncke GM, Buncke HJ. Serratus anterior-rib composite flap: anatomic studies and clinical application to hand reconstruction. *Ann Plast Surg* 1999;42:132–136
14. Bruck JC, Bier J, Kistler D. The serratus anterior osteocutaneous free flap. *J Reconstr Microsurg* 1990;6:209–213
15. Mathes SJ, Nahai F. *Clinical Atlas of Muscle and Musculocutaneous Flaps*. St. Louis: Mosby; 1979

Operative technique of the transfer of the Rhomboid Nerve to the Suprascapular Nerve

12

J-N. Goubier*, F. Teboul*

Institute of Peripheral Nerve and Brachial Plexus Surgery, 92 Boulevard de Courcelles, 75017 Paris, France

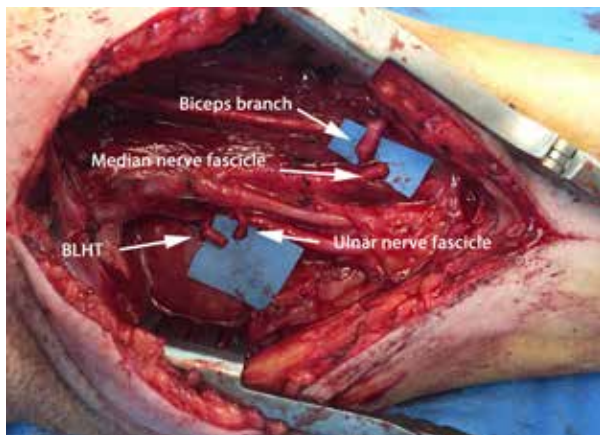
Technique [1,2]: The patient is positioned in lateral decubitus. A posterior approach along the spine of the scapula is performed. The trapezius is detached close to its scapular insertion in order to access the supraspinatus fossa. Then, the deep aspect of the supraspinatus muscle is recliné in order to access the suprascapular notch. At this level, the SSN is located, then freed by sectioning the transverse ligament of scapula, to obtain the maximal length to facilitate the subsequent suture.

The levator scapulae muscle is detached from the medial border of the scapula, and then retracted to expose the deep aspect of the dorsal scapular nerve. Once exposed, the branches to the levator scapulae muscle and the rhomboid muscle are isolated. Electrical stimulation of the rhomboid nerve, starting with low intensity (0.02mA) is performed to confirm normal innervation. The branch for the rhomboid muscle is freed the furthest possible in the muscle and in the dorsal scapular nerve in order to obtain the

maximum length. The branch is then sectioned close to the muscle and is brought into contact with the SSN (*Figure 1*). Then, the rhomboid and SSN are sutured under microscopy, with 3 separate 11-0 nylon sutures supplemented with fibrin glue. The trapezius muscle is reinserted to the spine

of scapula. The skin is closed without a suction drain. The upper limb is immobilized in a splint for three weeks. Then, rehabilitation is started with passive motion of the upper limb. Once the first contractions occurred, electrical stimulation of re-innervated muscles is performed.

Figure 1



REFERENCES

1. Goubier JN, Teboul F. Transfer of the rhomboid nerve to the suprascapular nerve: An anatomical feasibility study. *Chir Main.* 2015;34:182-5.
2. Goubier JN, Teboul F. Rhomboid nerve transfer to the suprascapular nerve for shoulder reanimation in brachial plexus palsy: A clinical report. *Hand Surg Rehabil.* 2016;35:363-6.

Free fibular flap: how i do it

13

Andreas GRAVVANIS, MD, PhD, FEBOPRAS

George PAPANIKOLAOU, MD, PhD

General Hospital of Athens "G. Gennimatas"

Introduction

The vascularized free fibular flap (FFF) was first performed by Taylor (1975) and then introduced in mandibular reconstruction by Hidalgo (1989). Nowadays, the free fibula has become a workhorse in microsurgery and is the most commonly used free flap in head and neck reconstruction for segmental large bone and soft tissue defects as well as in both the upper and lower extremities due to trauma, tumor ablation, and osteo-

radionecrosis. The tubular shape and dense cortical structure of fibula renders it valuable for midface/maxillary reconstruction as well as after extensive oromandibular resections.

Anatomic Considerations

The fibula is a long, compact and tubed bone. In cross-section the shaft of the fibula has four surfaces (lateral, medial, posterior, and a narrow anterior surface), and three

margins (anterior, posterior, and medial/intraosseous margin). The upper part is quadrilateral and the lower part triangular in shape. It gives origin to the muscles of the lateral, anterior and posterior tibial compartments. It contributes to stabilizing the knee through the fibular head, and of the ankle with the lateral malleolus.

The vascular supply of fibula is given by the peroneal artery and its paired venae comitantes. The artery has a large diameter of 1.5mm to 4mm, and the accompanied venae are usually similar in size to the artery. The peroneal artery arises from the tibioperoneal trunk about 5-7cm below the head of the fibula and are in close proximity to the fibula as it course along the entire length of the bone. The length of the pedicle is usually short, but can be increased significantly by subperiosteal dissection from the proximal fibula. In its course, the peroneal artery gives off a nutrient artery about 12-14cm below the head of the fibula and as proceeds distally gives origin to a rich periosteal blood network. This periosteal blood supply is critical for the bone viability when the fibula is shaped by performing the osteotomies. Therefore, as much periosteum as possible, as well as a cuff of muscle must be preserved around the fibula. Several septocutaneous perforators pass through the posterior crural intermuscular septum to supply the lateral skin of the leg. Moreover, different musculocutaneous perforators can be identified during the flap harvesting and they must be kept intact in case of insufficiency or injury of the septocutaneous branches if an osseocutaneous flap is planned.

The peroneal osseous flap is insensate, but several nerves must be preserved during the raising of the flap. Firstly, the sural nerve that innervates the lateral leg is vulnerable

during the elevation of the posterior part of the skin flap as it course in close proximity to the lesser saphenous vein. Subsequently, the superficial peroneal nerve must be kept intact during the elevation of the anterior part of the skin flap. The common peroneal nerve winds from posteriorly around the lateral surface of the neck of the fibula and attention must be given during the proximal dissection of the pedicle at the head of the fibula. Finally, either the deep peroneal nerve or the tibial nerve are vulnerable during the dissection of the peroneal vascular pedicle.

Technical Assessment

The FFF has been established as the method of choice for osseous mandibular reconstruction and is preferable to non-vascularized bone grafts or pedicled osseocutaneous flaps, as it is associated with higher rates of bone survival and provides well vascularized tissue, reliable wound healing, and earlier rehabilitation with reduced risk of plate exposure. Mandibular defects larger than 40mm in length are best reconstructed with vascularized bone graft, and FFF appears as the gold standard of treatment.

The fibular flap provides an adequate length of bone (up to 25cm long) and can be modeled to simultaneously reproduce the recipient defect, especially for long or lateral mandibular defects involving the ramus and body. It is a thick bicortical bone, allowing for secure fixation of osteosynthesis plates, reliable prosthetic rehabilitation, and osseointegration of dental implants. This flap has a long vascular pedicle (up to 8cm long) of large caliber that can be made longer by stripping the periosteum off the

bone in the proximal portion of the fibula. Moreover, the fibular flap can be harvested as osseocutaneous flap with one or more skin paddles (chimeric flap) for mucosal and skin lining, or as osseomyocutaneous flap including the flexor hallucis longus, and a part of the tibial posterior or the soleus muscle. In addition, it presents a segmental blood supply and can tolerate osteotomies as close as 1-cm apart without compromising flap viability. Furthermore, fibular bone is less affected by postoperative radiotherapy due to its strength and thickness.

Nevertheless, the FFF presents some drawbacks, involving mainly the donor site morbidity such as delayed wound healing and skin graft, nerve injury, and ankle instability. Preoperative vascular problems (peripheral vascular disease, venous insufficiency, congenital absence of lower leg vessels, etc), poor skin quality (obesity, ischemia), and previous lower limb trauma can preclude the use of the fibular flap and complicate the preoperative plan limiting the reconstructive options. Since the simple osseous fibular flap lacks of skin paddle it is impossible to monitor its viability, and the microsurgeon must be confident either with the vascular anastomosis or the inseting of the flap to the recipient site.

In some patients, the limited height of the fibula bone may present a prosthetic problem, especially in young patients with ameloblastomas who have undergone partial resection and retain dentition on the healthy side. In these cases, to reach the occlusal plane, the flap can be positioned ideally for prosthetic rehabilitation with its upper border at the level of the residual alveolar crest, but this position has negative effects on the profile of the lower border. Thus, the ideal solution is the use of a dou-

ble-barrel flap to increase the height of the reconstructed mandible.

Preoperative Workout

Normal vascular anatomy and arterial competence were ensured by preoperative evaluation of the lower extremities. History of intermittent claudication, deep vein thrombosis, and lower limb trauma must be considered. The anterior and posterior tibial pulses are palpated in order to exclude the presence of peripheral vascular disease. In case of no palpable pulses we perform preoperative Computed Tomography Angiography (CTA) or Digital Subtraction Angiography (DSA), which can give us information about the vascular anatomy of the lower leg. Moreover, with the CTA we can have information about the perforator's anatomy and proceed more accurately to the design of chimeric flaps. The portable doppler ultrasound will also help us to locate the septocutaneous perforators.

In case of mandibular reconstruction we routinely perform preoperative panoramic radiographs and computed tomography scanning. Furthermore, in secondary reconstructions, a 3-dimensional stereolithographic model with the aid of Computer Aided Design/Computer Aided Manufacturing (CAD/CAM) technology is produced. The model is used as a guide to precontour a reconstruction plate that is sterilized and used intraoperatively to facilitate fibular flap shaping.

The type (simple or composite) and dimensions of the fibular flap are dependent upon the recipient's needs. According to my experience the most frequently used flap is the osseocutaneous fibular flap followed by

the osseous fibular flap. Finally, informed consent must be taken from all the patients.

Intraoperative Details

Flap design

I usually use the ipsilateral fibula for mandible reconstruction with an intraoral defect and when the vascular anastomosis has to be performed at the ipsilateral neck vessels. This is mainly due to the fact that the anterolateral surface of the fibula has to be the anterior surface of the “neomandible” for secure fixation. Moreover, the flexibility of the septum allows us to use the same donor leg either when we have to use the contralateral neck vessels for the vascular anastomosis.

The head of the fibula and lateral malleolus are marked. Then, we palpate and draw the posterior border of fibula bone that corresponds to the posterior intermuscular septum where the septocutaneous perforators run through (axis of the flap). The use of handheld doppler will guide us to locate and mark the perforators on patient's skin. The skin paddle is outlined over the dominant perforators, usually around the junction of the middle and distal thirds of the lateral leg. The skin flap width should be limited to 4-5cm in case that we plan direct closure of the donor site. Afterwards, we mark the distal and proximal osteotomy sites preserving 5-7cm of the distal fibula and 5cm of the proximal fibula for ankle and knee stability respectively.

Patient setup

In case of maxillary and mandibular reconstruction a 2-team approach is used. The patient is placed in a supine position with the knee bent and a bump under the ipsi-

lateral hip to lessen the need for excessive internal rotation of the lower leg. A tourniquet is placed around the thigh and the leg from the knee down is prepped and draped. The leg is elevated 60° and exsanguination is performed. The tourniquet is inflated to at least 100mmHg above the patient's systolic blood pressure and a maximum ischemia time of 90-120min is respected.

Harvesting of the free fibula flap

If no skin paddle is needed, the incision is made along the axis of the osseous flap and the dissection proceeds to fibula as described below. Otherwise, the harvesting of the flap begins making an incision along the anterior margin of the skin flap. The anterior skin flap is elevated cutting through the investing deep fascia toward the posterior intermuscular septum in order to identify the perforators running through this septum. Attention must be given to avoid injury of the superficial peroneal nerve in the lower third of the leg. If no perforators are visible, muscular perforator must be preserved and harvested. The dissection continues from the septum down to the lateral-posterior border of the fibula. Afterwards, the posterior margin of the skin flap is incised taking care to identify and preserve the sural nerve and lesser saphenous vein in order to minimize donor site morbidity. The posterior part of the skin flap, along with the deep fascia, is elevated towards the posterior septum down to the lateral-posterior border of fibula, tracing the perforators that again come into view. Now posterior septum with the perforators running through it are freed and attached to the bone. Check and mark their position on the skin and deep fascia with ink. The skin incision is extended proximally and distally to expose the entire length of the fibula.

The dissection is then carried on laterally to detach the peroneus longus and brevis muscles from the lateral aspect of the fibula. Then, incise the anterior intermuscular septum and release the extensor digitorum longus and the deeper extensor hallucis longus muscles from the anterior surface of the fibula. In the anterior compartment identify and preserve the anterior tibial vessels and the deep peroneal nerve. Posteriorly, the soleus muscle is separated from the fibula in the same way.

At this stage, perform early osteotomies (proximal and distal) of the fibula. A subperiosteal dissection is carried on with delicate dissector such as a Freer's elevator and a right angle retractor is placed to encircle the bone. Osteotomies are performed using an oscillating microsaw. The early osteotomies facilitate the further dissection.

Subsequently, using bone clamps to retract the fibula, the interosseous membrane is divided sharply and the fibula is fully mobilized antero-laterally. Behind the interosseous membrane the peroneal vessels are identified running posterior to the posterior border of the fibula bone, in the muscular sheath of the flexor hallucis longus. Trace the peroneal vessels from distal to proximal, ligating and cutting their distal part adjacent to the distal osteotomy. Retracting the bone laterally, proceed from distally to proximally in order to detach the tibialis posterior muscle and the flexor hallucis longus muscle from the posterior surface of the fibula leaving a minimal muscle cuff to the bone. Ligate all the muscular branches and separate them from the posterior tibial vessels and tibial nerve (occasionally they run very close).

Once the flap is completely free, the peroneal vascular pedicle is inspected and carefully dissected further toward the tibiope-

roneal vascular trunk. Finally the artery is separated from the accompanying veins. At this point, the tourniquet is usually deflated to perform meticulous hemostasis and ensure good blood flow to the foot. When the recipient site is prepared, the vascular pedicle is ligated using ligaclips and cut, paying attention not to injury the posterior tibial artery and tibial nerve. Finally, the wound closure is performed and one drain is placed with its free part distally in order to avoid injury of the ligated vessels proximally.

Shaping of the fibula bone

The vascular pedicle is elongated by subperiosteal dissection of the proximal fibula and using the distal fibula for the reconstruction.

In immediate reconstructions, the affected mandible is exposed, the osteotomy is marked out, and a locking screw reconstruction plate is adapted to the mandible. The plate is contoured according to the shape of the resection specimen and is used to model the fibula flap.

In secondary reconstruction, as previously mentioned, a 3D stereolithographic model with the aid of CAD/CAM technology is produced. The model is used as a guide to precontour a reconstruction plate that is sterilized and used intraoperatively to facilitate flap shaping.

Usually, we draw a V-shaped paper template that is transferred to the fibula to plan the V-shaped osteotomies.

Postoperative Care

All patients are hospitalized in the intensive care unit for 24 hours and then in the department for about 5 days. During the

postoperative period, the flap is monitored with portable color duplex.

The donor site is splinted with the ankle at 90o and the lower leg should be elevated during the first week to avoid edema. The patient is allowed to ambulate at about a week after surgery.

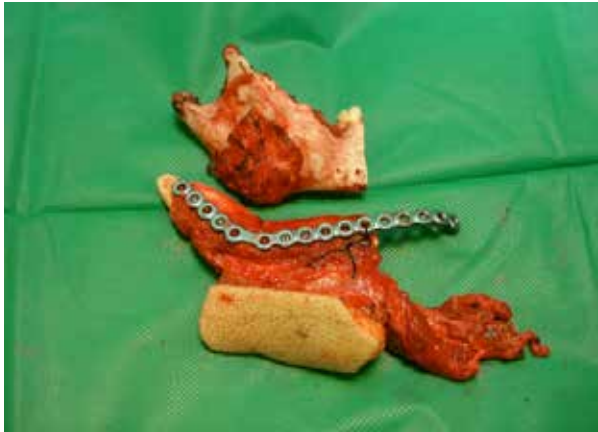

Figure 1: Condyle-ramus-body segment along with oral mucosa were resected and subsequently reconstructed with free osseocutaneous fibula flap.

Conclusion

The free fibula transfer provides satisfactory functional and aesthetic reconstruction particularly for composite midface and mandibular defects. In experienced hands, success of transplantation reaches almost that of 100%.

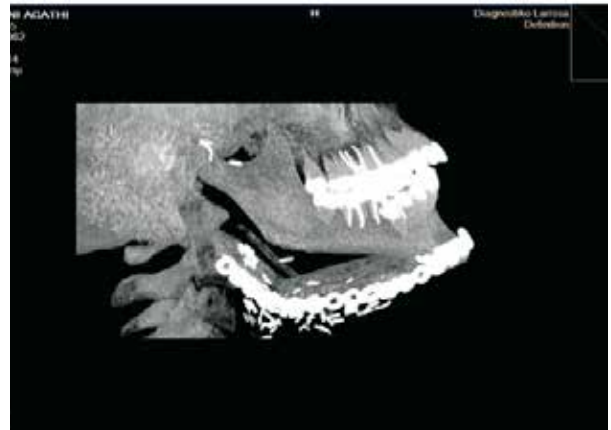


Figure 2: Patient's CT scan 3 years following the reconstruction: The free fibula flap incorporated fully and provided a smooth jaw contour.

Use of perforator vessels as recipient vessels in foot reconstruction

14

Carmen Higuera

Hospital Universitario Germans Trias i Pujol, Barcelona

Evolution in Microsurgery has played a crucial role in limb salvage in the last 20 years. The presence of vasculopathies rises as we go distally towards the foot and reconstruction options are frequently limited.

Supermicrosurgery overcomes the limits of conventional microsurgery and leads to the next step in the evolution of lower extremity. It is defined by Dr Koshima as microsurgical anastomosis of vessels of a diameter less than 0.8mm.

We started using this technique in 2015 for foot reconstruction. The main reasons

were diabetic ulcers but also tumors, trauma and ischemic reasons.

Surgical Technique

Preoperative angio CT is obtained to evaluate vascular status and hand Doppler is used to mark potential recipient perforators and perforators of the flap.

Two team approach is used, one team begins by elevating the flap and the other team does the debridement and search for recipient

ent vessels. We do the debridement with a scalpel in order not to damage the nearest vessels. The searching of the vessels is done under microscope and the dissection continues until suitable vessels are found, ideally pulsatile vessels.

First we check the recipient vessels with transit-time flow measurement and transect them and if a good flow is seen, then transect the pedicle.

SCIP flap is our flap of choice for distal foot reconstruction. The reasons are minimal donor site morbidity and that we can achieve very good contour of the foot. Elevate the flap with a superficial vein.

It's important the matching of the recipient and donor vessel because if we anastomose the flap to a main vessel, it can be too much flow and venous congestion will occur. We always do 2 veins.

It is important to dilate the vessels and to minimize manipulation of the vessels to avoid spasm. We use 10/0 or 11/0.

Although a good pulse and bleeding are the signs of a suitable vessel, don't be afraid of the low blood flow, when a patient awakes and the blood tension raises, the flap will start bleeding.

There is a low capacity of adaptation, play with postural changes in the postoperative time.

We irrigate with low weight heparine and local lidocaine.

We use TTFM to measure the flow in the recipient vessel and postmicroanastomosis

Transit-time flow measurement (TTFM) uses ultrasound technology and is widely used in cardiac surgery. Some reports indicate the beginning of a new application of this technology in microsurgery. In cardiac surgery, values and uses are well established, but there are no guides available for micro-

surgery. In addition to TTFM, imaging by echography of small vessels is available, and could give more information and guide in microsurgery.

We are trying to determine whether there are values of flow and pulsatility index that could predict some outcomes like anastomosis patency, adequacy of the arterial and venous outflow, need of secondary vein, etc. The association of eco imaging provides us some extra information, it's also still uncertain the real value of the data, but we expect that this new application of technology will result in a better understanding and prediction of microsurgery outcomes. With this aim we are using MiraQ vascular device (Medistim[®]) with TTFM 1.5mm and 2mm probes and eco imaging device.

Many measurements are done:

1. Nutrient arteries/veins of the flap in situ.
 2. Receptor vessels. TTFM + Echography.
 3. Flap perforators.
- Once the anastomosis is done
4. Artery pre and post anastomosis.
 5. Vein pre and post anastomosis.
 6. Echography of the anastomosis.

This could seem like time consuming, but TTFM takes 7 seconds, and echography takes no more than 5 minutes once you get used to it.

Some difficulties are found when the flow or the vessels are very small, but in these cases, we find very helpful the use of imaging.

Our preliminary results showed that it is very useful in certain situations:

1. To determine the flow direction in small receptor arteries. In two lower extremity reconstruction the expected direction of the artery flow wasn't the real direction, so the application of both TTFM and imaging, confirmed the real direction of the

flow before cutting the artery and the vessel trimming and anastomosis was performed in the proper artery end.

2. To choose concomitant vein. Many times, we choose the secondary vein according to size, using TTFM we make sure it's the one with higher outflow.
3. To examine recipient vessel. Echography avoids atherosclerotic and turbulent flow zones if main vessels are used.
4. To check the anastomosis patency. Traditional squeezing patency test is useful for veins, but not for elastic arteries. With TTFM we make sure that the blood is going through the anastomosis, and we are able to quantify it. We find it very useful, especially in flaps which clinical assessment is difficult like buried flaps and muscular flaps.
5. To determine laminar flow in the anasto-

mosis. After performing the anastomosis, we do an echography in the anastomosis with colour Doppler and speed measurement. Cut values are still not available, but if turbulent flow or low speed is detected, we look for possible reasons and many times, redo the anastomosis. If there is a posterior wall stitch, deformation of the vessel wall can be observed by echography.

We are working hard to be able to report cut values in which every microsurgeon in the world could determine the quality of his anastomosis, the adequacy of the inflow and out, and to provide robust data supporting the use of echography, but while these happen, we are glad to report some advantages of this technology and hope that this can help our colleagues facing the same challenges that we face.

Reverse flow anastomosis from end arterial arch for middle phalanx amputations of the fingers

15

Ioannis A. Ignatiadis, MD¹, Andreas F. Mavrogenis, MD²

¹ Athens Medical Center, Psychico Clinic, Athens, Greece

² First Department of Orthopaedics, National and Kapodistrian University of Athens, Athens, Greece

Introduction

The main blood supply of the fingers is obtained by the 2 palmar digital arteries. These form an end arterial arch at the palmar fingertip area for vascularization of the pulp that corresponds to the middle of the distal phalanx (*Figure 1A*). Additionally, the 2 palmar digital arteries form another 2 arterial arches, each of them supplying communicant branches that meet at the distal third of the middle and the proximal pha-

langes. Based on the above vascular anatomy of the fingers, various microsurgical techniques have been described for repair of amputations of the distal, middle phalanx and the fingertip. [1, 2, 3, 4] The aim of these techniques is to avoid using vascular grafts or to shorten the stump bones for achieving a successful replantation when vessels (veins and arteries) are not intact, or their length are not enough for revascularization/replantation. Some of these techniques include the Fosters' fingertip re-

plantation transferring artery from a neighbor finger, [5] replantation using a single artery, [6] venous arterialization, [7] one of the comitant veins for bridging the digital artery, [8] atypical arteriole anastomosis with reversed flow venous anastomosis, [9] using a single artery bifurcation, [10] or replantations using other reversed flow or super microsurgery techniques [11].

Guillotine type or minimal crush injuries, grade I or grade II avulsion injuries and partial (incomplete) amputations where a part of dorsal skin including one or more veins of the fingers are considered ideal cases for replantation using a reverse flow anastomosis procedure. Severe crush or mangled fingers are not appropriate for this technique, and in complete amputations an additional procedure for ensuring a venous return is necessary. After an amputation at the middle phalanx (*Figure 1B*) of the finger, the 2 stumps include the 2 ends of 2 sectioned arteries each, leaving 4 ends of 2 sectioned arteries (*Figures 1B, 2A*). The distal end arterial arch as well the proximal to the section first arterial arches are maintained intact; therefore, if the compatibility of these arches is not compromised, the 2 arteries communicate between them in both the proximal and distal amputated parts.

Operative technique

At the palmar aspect of the distal stump (finger pulp), one of the 2 digital arteries is dissected and harvested (*Figures 1C, 2B*). This artery forms the end arterial arch from distal to proximal, maintaining the proximal connection with the contralateral artery which lies quite closed to the level

of the stump. Care is taken to avoid titling at the pivot site where the artery has to be reversed (*Figures 1C, 2B*). The harvested artery has to override the amputation level and to be anastomosed with the sectioned end of one of the arteries of the proximal stump (*Figures 1D*), allowing restoration of the blood supply by a reverse arterial flow. The cut ends of the remaining 3 arteries are ligated at both the distal and proximal stumps (*Figure 1D*).

Advantages and benefits of the described technique

The above described reverse flow anastomosis technique ensures rapid revascularization of the amputated stump, in a short operative time for partial amputations of the fingers. Only one arterial anastomosis is necessary, in contrast to similar procedures using vascular grafts where two level anastomoses should be performed that jeopardize compatibility of the graft and success of the anastomosis. In comparison with alternative procedures such as bone shortening of the amputated stumps to ensure an end to end arterial anastomosis, this technique is considered superior because length of the finger is maintained and is quite safe for the finger healing.

Additional techniques for vein repair

In cases of complete amputations, except for the standard procedure using vein grafts for bridging the veins, a vein from a neighboring finger can be harvested, similar to Fosters arterial transfer technique; 5 when

harvested up to the interdigital space, this vein graft is longer than the veins at the stumps of the amputated finger.

Digital nerve repair

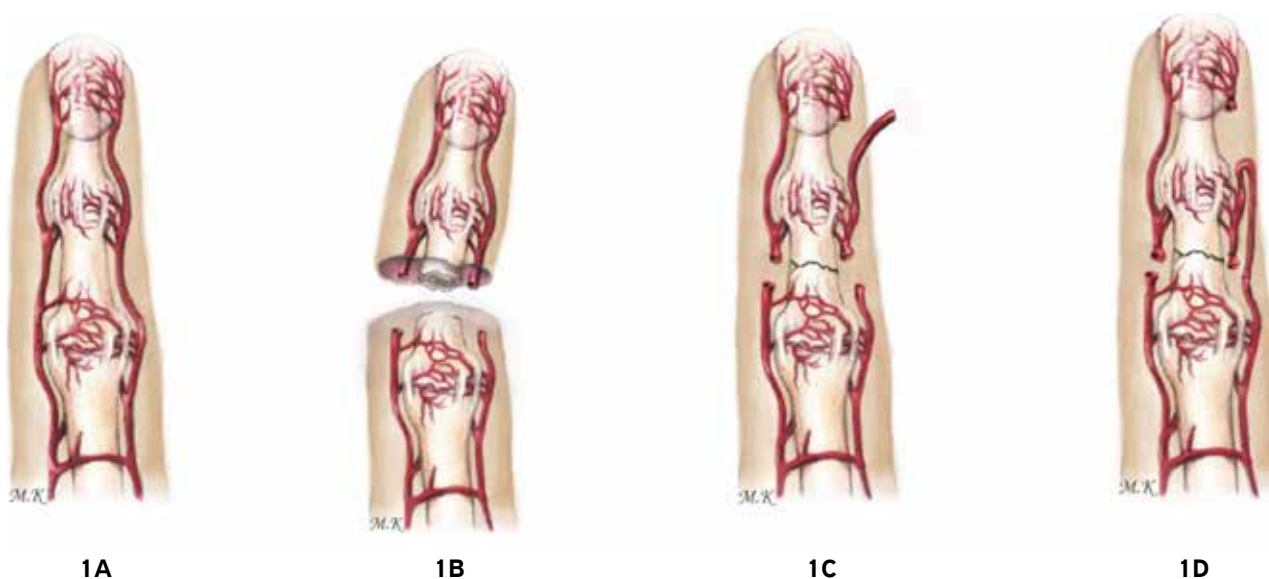
Digital nerves are usually more elastic and easier to dissect for achieving a successful tension free end-to-end repair. Moreover, if necessary, bridging of the nerve defect after the above described technique can be performed more easily using a nerve autograft harvested from the medial antebrachial cutaneous nerve. If not feasible,

bridging of the nerve defect could be performed at a second stage.

Conclusion

In conclusion, the reverse flow anastomosis technique is a successful microsurgical technique for optimal replantation of partial amputations of the fingers. Healing of the replantation is safer because only one microsurgical arterial anastomosis is required, and length of finger is maintained because bone shortening is not necessary.

Figure 1



1A. The normal digit blood supply.

1B. Amputation of the finger before the distal stump artery division and its harvesting.

1C. Harvesting and reversion of the artery of the distal stump

1D. Reversed flow anastomosis of the arteries, ligatures of the remaining free arterial stumps.

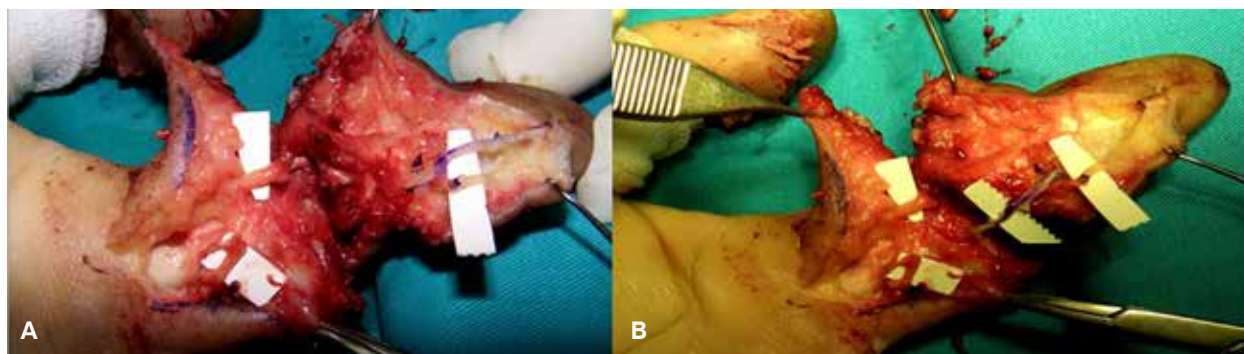


Figure 2: Clinical case: index finger partial amputation and repair technique.

A 48-year-old man with an incomplete amputation at the distal third of the middle phalanx of the index finger, only the dorsal skin was maintained intact containing 1 or 2 dorsal veins.

2A. In the index finger of the Figure 2, all arteries and nerves were found damaged.

2B. After bone fixation with 2 Kirschner wires, all arteries from both proximal and distal stumps were dissected, and the radial digital artery at the distal stump was harvested, proximally reversed, and the radial digital artery anastomosed to the ulnar artery at the proximal stump. The ulnar distal artery was selected as the recipient vessel for anastomosis with the reversed radial digital artery because this artery was found in better condition and was a little larger than the radial one which normally corresponded to the radial distal artery (as in the design of the figures 1A-D).

REFERENCES

1. Cao X, Cai J, Liu W. Avulsive amputations of the thumb: comparison of replantation techniques. *Microsurgery*. 1996;17(1):17-20.
2. Kayalar M, Güntürk ÖB, Kaplan İ, Sügün TS, Ademoğlu Y. Techniques and survival incidence for revascularization of degloved fingers. *J Hand Surg Eur Vol*. 2017;42(9):946-951.
3. Power KT, Giannas J, McGrouther DA. Distal revascularisation/replantation using the reversed radial artery. *J Plast Reconstr Aesthet Surg*. 2009 Dec;62(12):1688-91.
4. Schoofs M, Bovet JL, Amarante J, Baudet J. Late revascularization for partial amputation of the thumb. *Ann Chir Main*. 1983;2(4):362-4.
5. Xu JH, Gao ZJ, Yao JM, Tan WQ, Dawreeawo J. Foster replantation of fingertip using neighbouring digital artery in a young child. *J Plast Reconstr Aesthet Surg*. 2010;63(6):e532-4.
6. Buntic RF, Brooks D. Standardized protocol for artery-only fingertip replantation. *J Hand Surg Am*. 2010;35(9):1491-6.
7. Tian L, Tian F, Tian F, Li X, Ji X, Wei J. Replantation of completely amputated thumbs with venous arterialization. *J Hand Surg Am*. 2007;32(7):1048-52.
8. al Qattan MM, Boyd JB. Use of a vena comitans as a vein graft in digital replantation. *Microsurgery*. 1994;15(2):149.
9. Yabe T, Muraoka M, Motomura H, Ozawa T. Fingertip replantation using a single volar arteriovenous anastomosis and drainage with a transverse tip incision. *J Hand Surg Am*. 2001;26(6):1120-4.
10. Hsu CC, Lin YT, Moran SL, Lin CH, Wei FC, Lin CH. Arterial and venous revascularization with bifurcation of a single central artery: a reliable strategy for Tamai Zone I replantation. *Plast Reconstr Surg*. 2010;126(6):2043-51.
11. Koshima I. Atypical arteriole anastomoses for fingertip replantations under digital block. *J Plast Reconstr Aesthet Surg*. 2008;61(1):84-7.

Technical tips in distal finger replantations

16

**Fatih KABAĞAŞ¹, Bülent ÖZÇELİK¹, Berkan MERSA¹, İlker Sezer¹,
Hüsrev Pürisa¹, İbrahim Alper Akasakal¹, Taçkın ÖZALP²**

¹ IST-EL Hand Surgery, Microsurgery and Rehabilitation Group, Istanbul, Turkey

² Department of Orthopaedics and Trauma Surgery, Celal Bayar University, Manisa, Turkey

Distal finger replantation is a challenge in microsurgery. Replantations distal to the flexor digitorum superficialis were initially termed as distal finger replantations [1] but today what is meant by a distal replantation is replantation through or distal to the distal interphalangeal joint [2].

Although controversy exists for the benefits of distal finger replantations, the results are superior to stump revision and other reconstruction methods both func-

tionally and cosmetically. The main advantages of distal finger replantation may be summarized as: it is a single stage procedure providing a good soft tissue coverage, good sensibility without painful neuroma, good range of motion in the affected joints, preservation of nail and finger length, cosmetically pleasing and satisfying the patient [3]. Longer operation times, longer hospital stays, longer time off work, and higher costs are main drawbacks of this operation [4].

Technical difficulties are another important drawback. The vessel sizes are so small that needs patience and skill for repair. Vessel diameters range between 0.8 to 0.3 mm [5,6]. It's difficult to find and tag these small vessels for repair. These fragile, thin vessels need delicate manipulation and have no tolerance to tightness in repair. Moreover, a good exposure and a comfortable space are needed to perform the fine anastomoses which is usually not the situation. Experience is so important for a successful result. However, there are problems in transmission of experience. Replantation is an emergency surgery and learned in the operating rooms after long hours and generally without supervision of senior surgeons. Every new resident has to experience the technical difficulties and find his way to solve the problems [2].

Depending on experience every surgeon has his own technical problems and his original solutions for the peculiar problems.

The aim of this chapter is to present our solutions and technical tips while performing distal finger replantation.

Management in the emergency room

Digital block anesthesia in the emergency room will relieve the patient and if performed with a long acting bupivacaine this can last until the end of operation. We usually perform distal finger replantations with local anesthesia and find it safe. This will help both the patient and the surgeon while inspecting the injury and informing the patients about the operation and possible outcomes (*Figure 1a*).

The X-rays of the amputated part and stump also photographs of the amputated part and stump should be taken at emergency, this will

help in planning the surgery and will give idea about bone and joint condition. Infrequently there may be a more distal or proximal fracture and foreign bodies may be detected (*Figure 1b*).

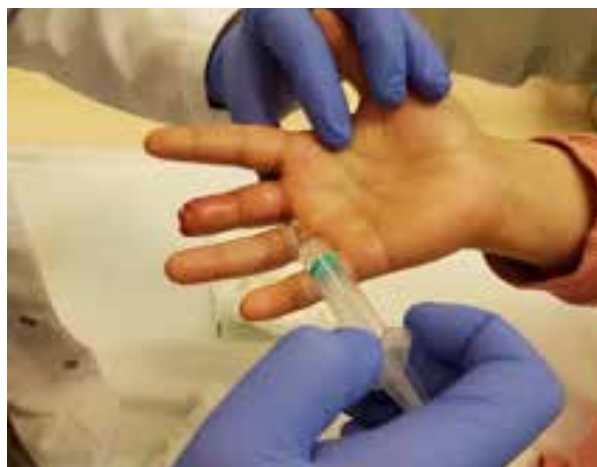

Figure 1: a) Digital block anesthesia.

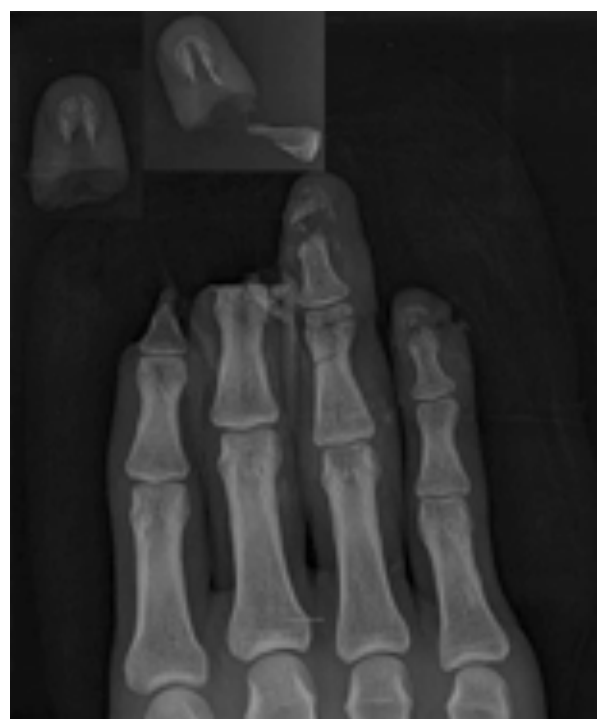

Figure 1: b) Fractures within the amputated segments

Preparation to replantation

If a decision is made to replantation with an informed consent of the patient than the surgeon should carry the amputated part

to the operation room by himself without waiting (*Figure 2*).



Figure 2: The amputated segment is carried by the surgeon.

This will save time. While the patient's paperwork and preparation for operation is performed, in emergency room the surgeon will be in the operating room preparing and tagging the amputated part. Most importantly this manoeuvre will prevent loss of amputated parts during transport (*Figure 3*).

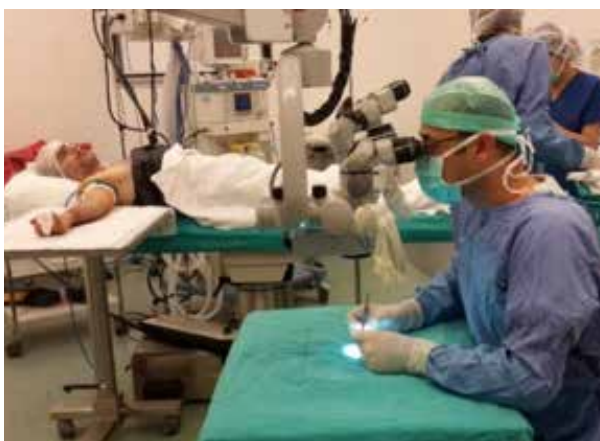

Figure 3: While the patient is taken to operating room and prepared for the operation, the surgeon will be already finishing with preparation and tagging of the amputated part.

Patient considerations

We should keep in mind that; patient's comfort during operation equals surgeon's

comfort. The patient should go to toilet before operation because not rarely the patients need urination during the critical moments of the operation and we do not want to use urinary catheters. The operation room must be heated for optimal vasodilation and comfort of the patient.

The silicone headpieces used during general anesthesia is uncomfortable for the locally anesthetized patient. We use a normal pillow as used in the patient's room during operation (*Figure 4*).

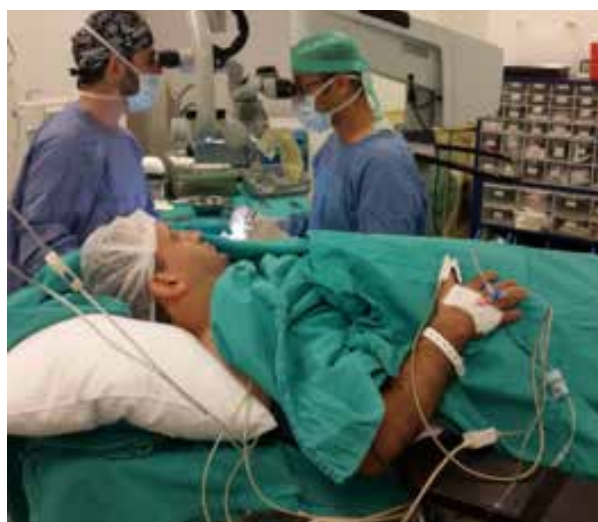

Figure 4: Established comfort of patient during replantation.

The intravenous lines (IV) should be settled at the dorsum of the contralateral hand not in the cubital area. Patients frequently comply about cubital IV lines during operation because they cannot move elbow due to pain. Our emergency team is informed about this matter and the IV line for finger amputation patient is settled on the contralateral hand dorsum at the initial preparation in emergency room (*Figure 4*).

Sometimes sedation is needed for patient's or surgeon's comfort but this may cause involuntary movements that can be detrimental during fine anastomosis.

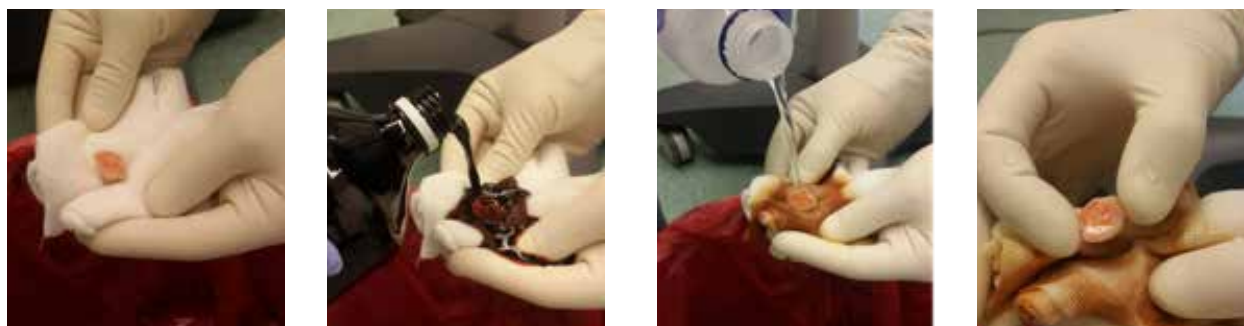

Figure 5: a) Holding without squeezing. b) Use of betadine. c) Saline wash. d) Manipulation

Preparation of the amputated finger

The amputated part should be prepared without squeezing to keep the blood within. That will help in detection of vessels especially small volar veins.

Betadine instead of foaming scrubs should be used. Because detergents in the scrubs permeate to connective tissues and vascular lumens which takes time to clean out. The betadine should be washed generously with saline. If needed the amputated part should be manipulated by holding from the lateral parts of nail not to squeeze and lose the blood of the pulp (*Figure 5*).

Stabilizing the finger for debridement and tagging

Stabilizing the amputated finger for debridement and tagging is usually performed by an assistant who holds the finger. The problem is tremor of the assistant during tagging. Few techniques are defined to overcome this problem in the literature. Defined techniques in the literature for stabilizing the amputated segment include: using hypodermic needles and a cork board, stay sutures attached to the operating table [7], using silicone finger mat of microsurgical instrument tray [8] and suturing the amputated part to a suture pack [9].

What we use for stabilization is a forceps (*Figure 6*). The microvascular clamp applicator forceps is suitable for stabilization [10].

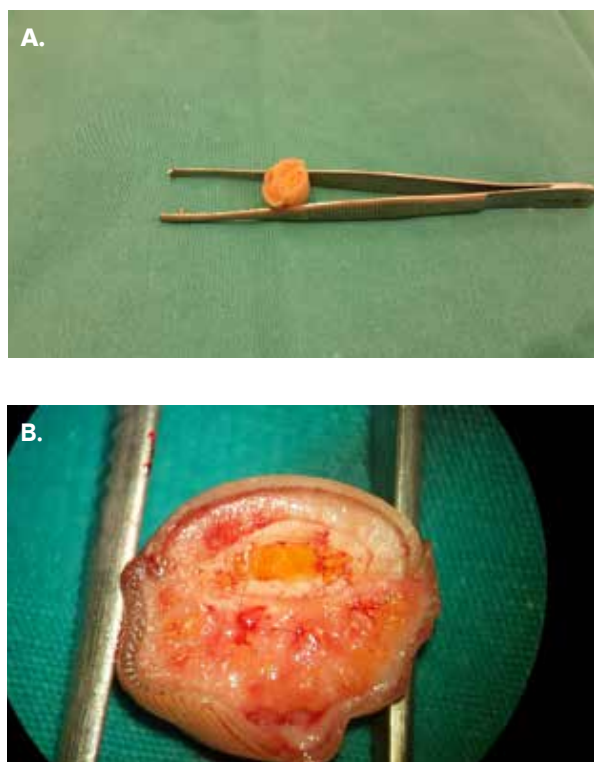


Figure 6: a) Use of forceps for stabilization. b) View of whole cross section

There is no assistant and no tremor. It fixes for easy debridement and tagging. Exploring the whole cross-section provides a better look in order to find and compare the available vessels.

Compression of the pulp will push the blood to the vessel ends and will make it easy to locate and tag (*Figure 6c*).

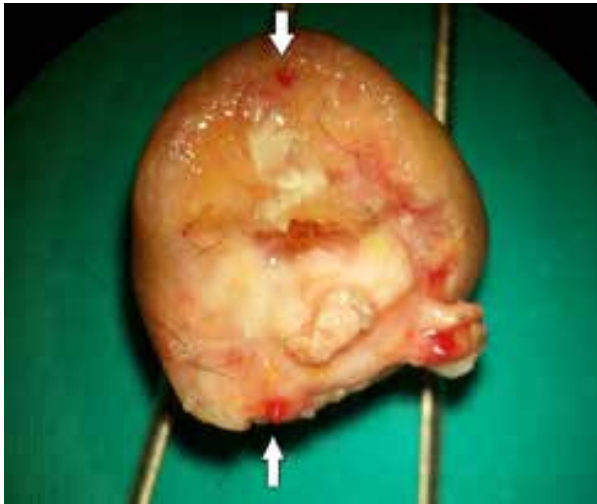


Figure 6c: Arrows indicate visible volar and dorsal veins with compression of the pulp

Debridement

The amputated part may be contaminated with oily grease, small metal particles, or soil (*Figure 7*). Debridement is needed in these situations but one can lose valuable vessel

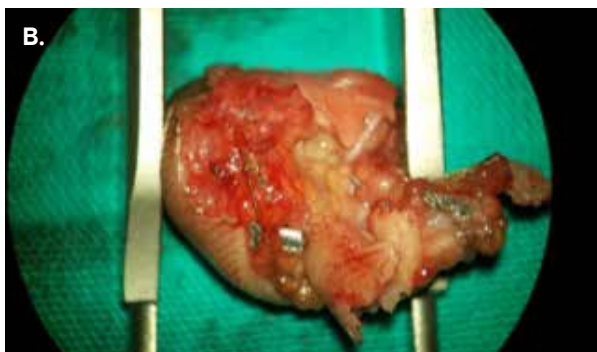
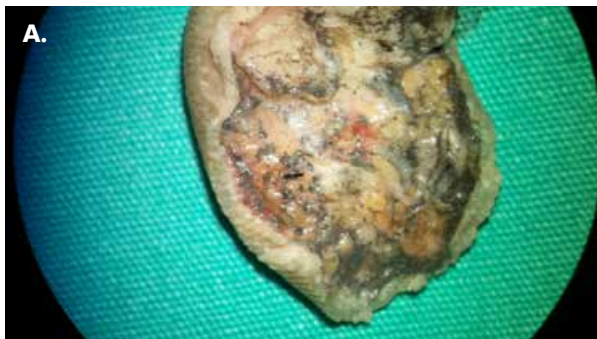
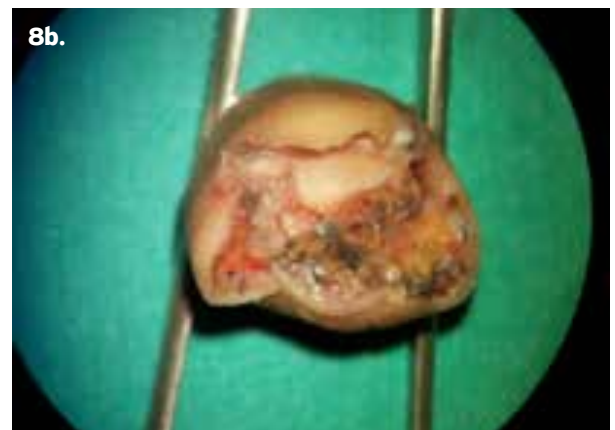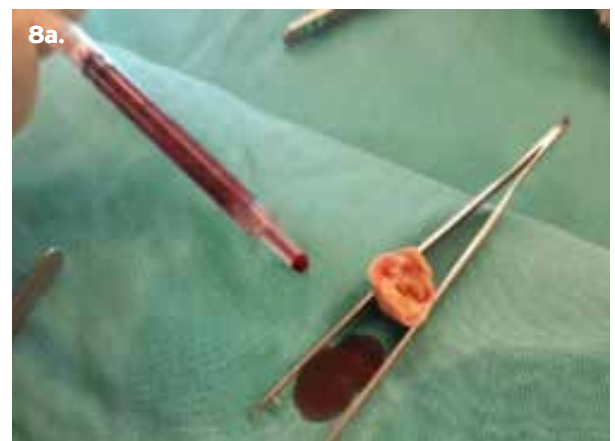Figure 7: a) Contamination with grease. b) Metal foreign bodies

length during non-discriminant debridement. Neuro vascular structures should be explored before debridement and protected. A magnet located in a sterile glove finger may be used to collect the iron metal particles. Depending on the power of the magnet superficial free big iron particles can be collected by this method but the small ones within the tissue will still take time of the surgeon.

Staining with blood

After debridement everything is white without contrast under powerful microscope lights which makes it difficult to localize vessels and nerves.

We use a drop of patient's blood obtained from IV line or proximal stump to stain the cross-section (*Figure 8*).



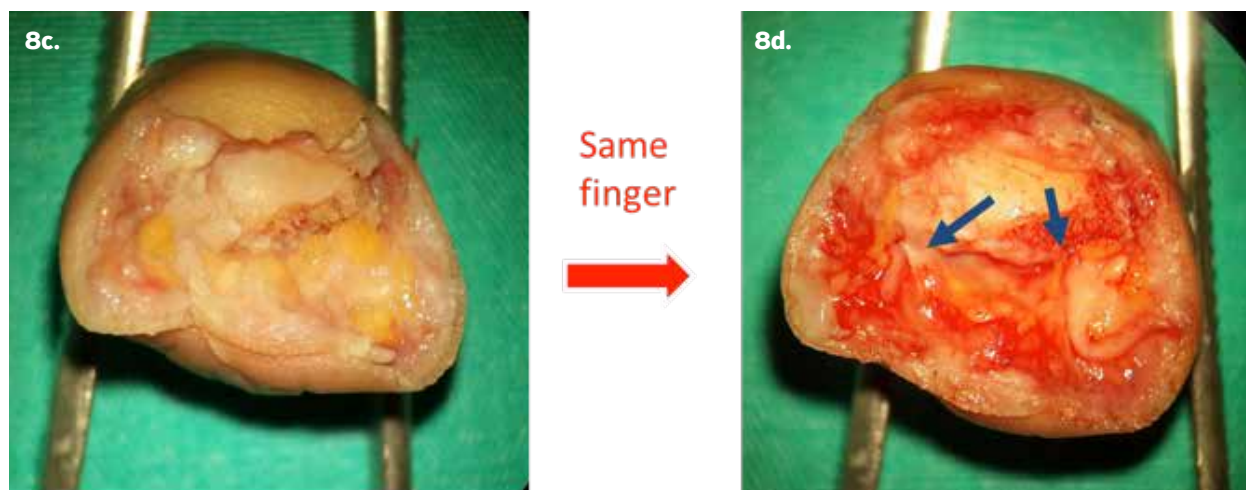


Figure 8: a) Staining with a drop of blood. b) Amputated part before debridement. c) The same finger after debridement. d) Same finger after staining with a drop of blood. Arrow indicated the neurovascular structures made visible.

Staining with a drop of blood puts a base colour that enables surgeon to see the transparent neurovascular structures (*Figure 9*). Moreover, the blood nestles within and around vessels that makes it easy to locate.

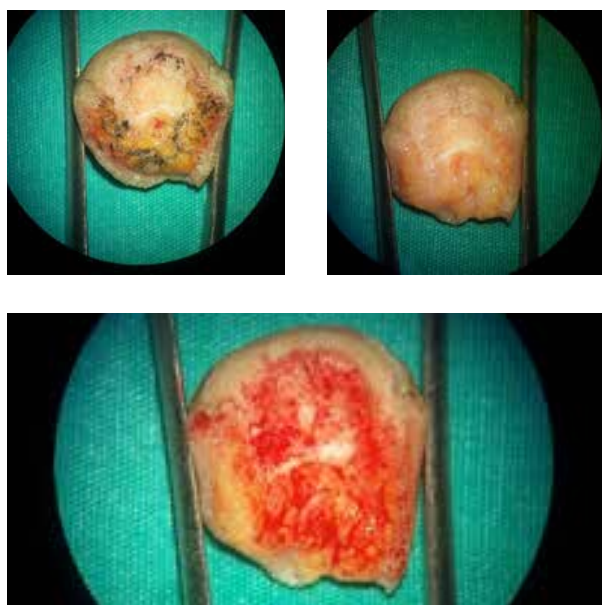


Figure 9: a) Before debridement b) After debridement c) After staining with blood

Tagging

Tagging with sutures is the classical and familiar method however it takes time (*Figure 10*).

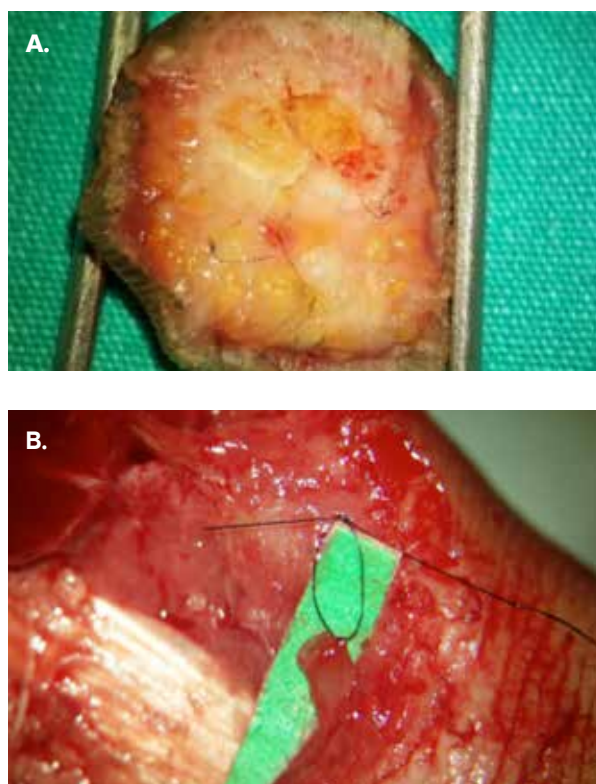


Figure 10: a) Volar veins and arteries tagged. b) Tagging with Loop suture

Loop sutures passing from adventitia may be used if the vessel will be tagged after preparation. The loop is then cut and the suture maybe taken without damaging the vessel.

Tagging with hemoclip is another choice that enables fast tagging. Hemoclip pro-

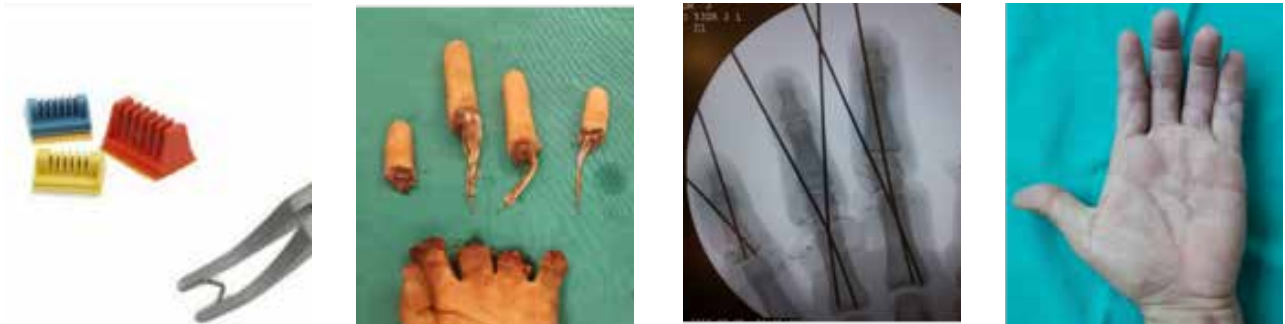

Figure 11: An example in a non-distal multi-finger amputation. Smaller sizes can be used in distal finger replantations.

vides a holding site to manipulate safely. Different sizes may be used for artery, vein and nerve. It decreases bleeding from the stump arteries. It is especially important in multiple finger replantations to save time and decrease bleeding (Figure 11). The disadvantages are; it shortens valuable length of the vessel since you have to cut it away

with a part of vessel. Surgeon must not hurry up to cut crushed vessel ends. The lumen may be explored by partial proximal cuts with preservation of the distal crushed segment (Figure 12).

Tagging by ligating a proximal injured branch will save time and decrease bleeding (Figure 13).

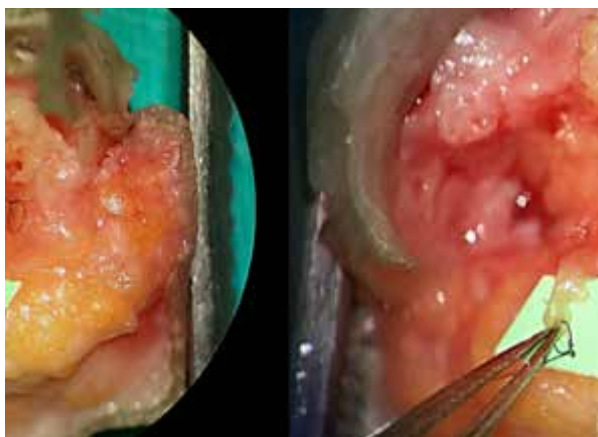
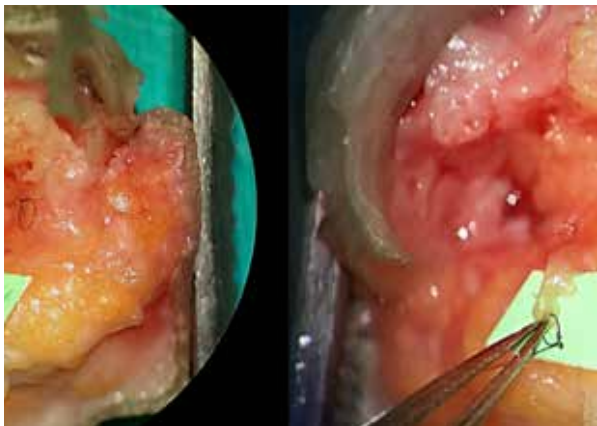
Figure 12: The crushed vessel ends provide safe tagging and holding sites for the surgeon

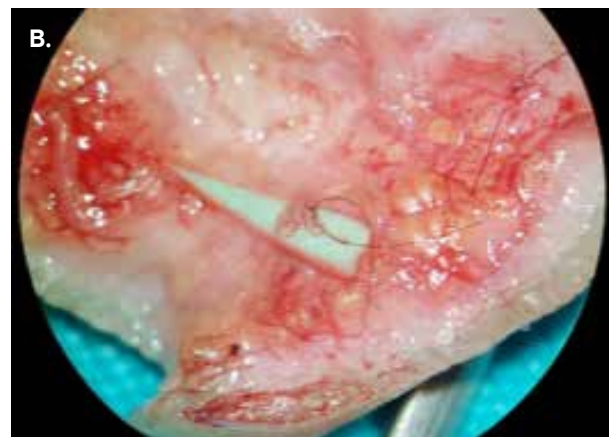
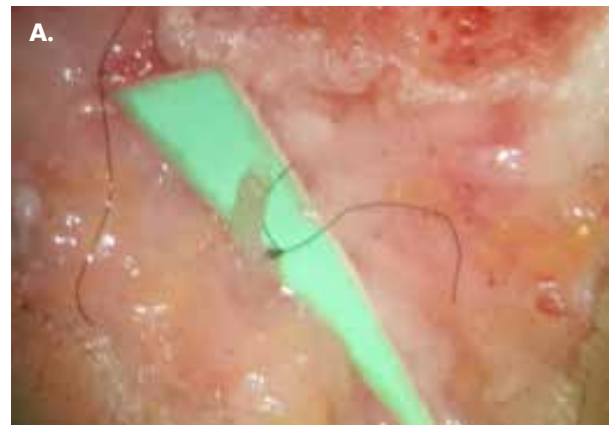

Figure 13 a, b: Two different cases with tagging by ligating an injured branch.

Preperation of the stump

The stump is usually left to stop bleeding by itself with loosely compressive gauzes.

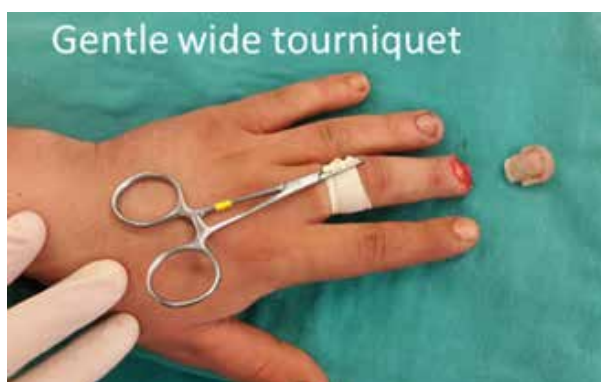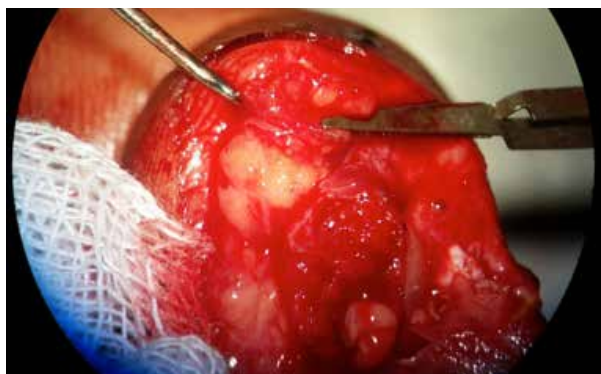


Figure 14: a) Microvascular clamp to stop bleeding. b) Finger tourniquet

The surgeon should stop bleeding from the stump. If it stops by itself then it stops with thrombosis and vasospasm that will complicate the anastomosis. We use microvascular clamps, gentle wide finger tourniquets, and hemoclips to stop bleeding from the stump (Figure 14).

These should be kept in place during bony fixation (Figure 15).

Bony fixation

One must remember that the biggest vein of finger is the medullary cavity of the bone. Complete anatomic reduction is

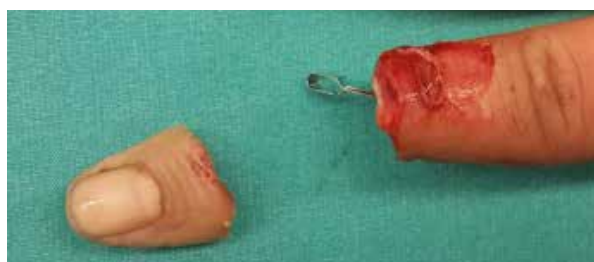
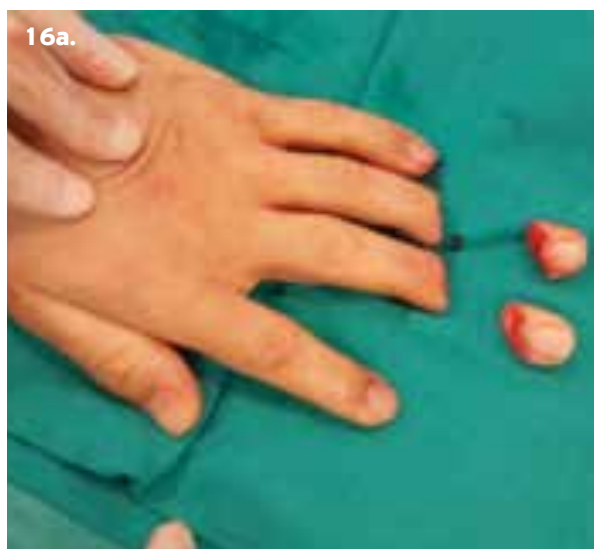
Figure 15: Microvascular clamps should be kept until arterial repair.

needed. It is especially important in distal replantations without vein repair. We try to perform complete anatomic reduction with 0.6 mm to 1 mm K-wire fixation not to occlude the medullary cavity (Figure 16).



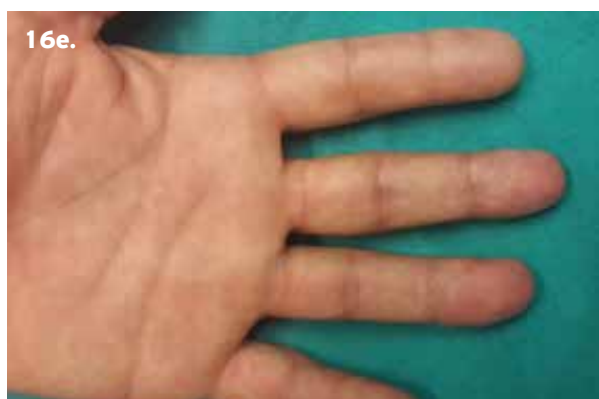
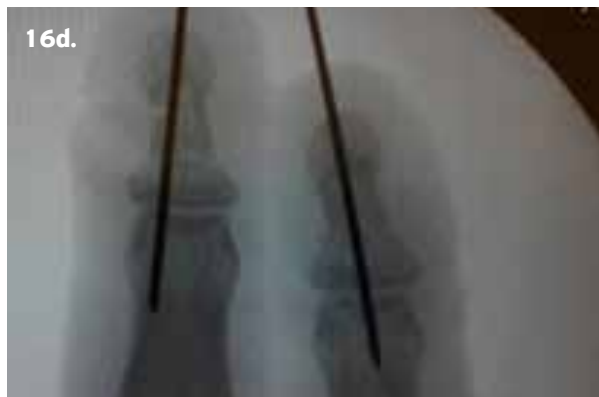
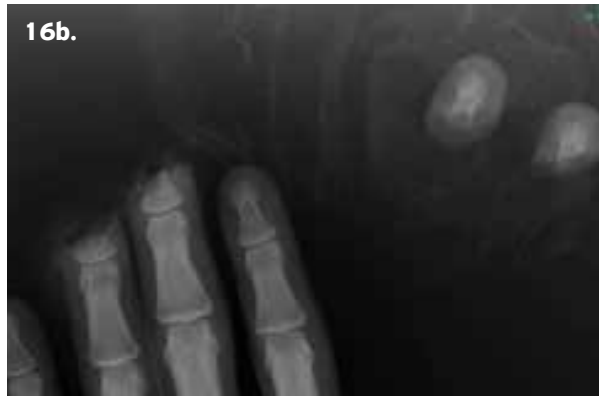Figure 16 a, b, c, d, e: complete anatomic bone reduction obtained in a distal multi-finger amputation.

Radiolucent hand table

We always check the reduction with fluoroscopy for each case. Radiolucent hand table helps for this (*Figure 17*).

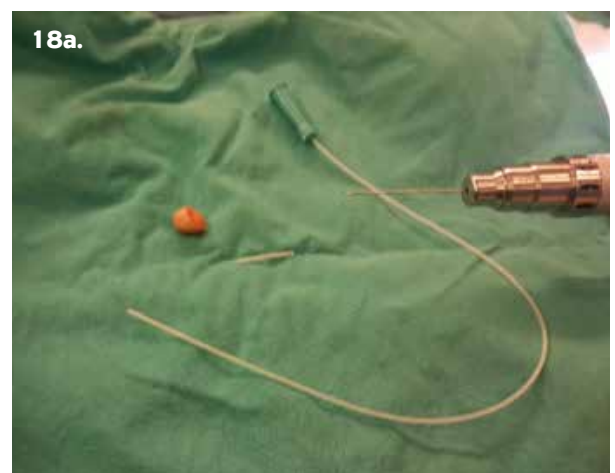


Figure 17: Radiolucent hand table is made of Plexiglas on a steel skeleton. It is cheap and helpful.

Aspiration tube to protect soft tissues

Protection of soft tissues and neurovascular structures during K-wire application is of paramount importance in distal finger replantations. If K-wire catches the vessels, you will lose valuable vessel length that even may not be reconstructed with vein grafts.

We use a segment of aspiration tube as a trocar to K-wire to protect soft tissues (*Figure 18*).



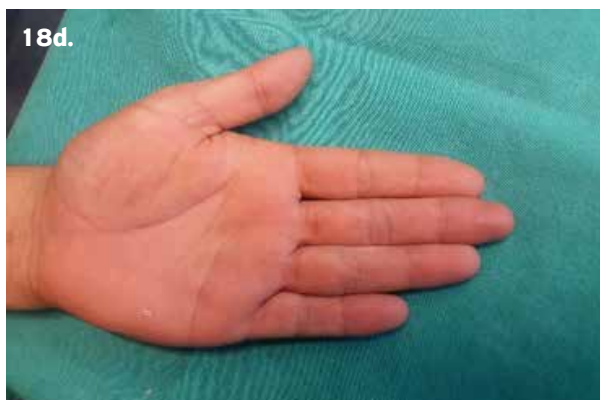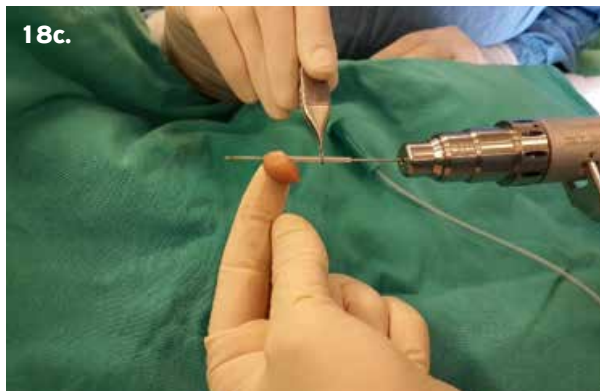

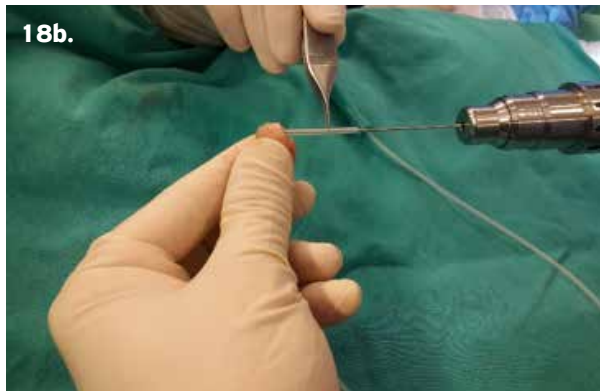
Figure 18: a) A segment of aspiration tube is prepared. b, c) The aspiration tube segment is fixed with a forceps and the K- wire is safely applied. d) Postoperative view of the patient

Tendon repairs

It is usually not needed in distal finger replantations but may be needed in amputations through DIP joint. The extensor tendon repair should not disturb the vein

repairs. Bulging of repair site and suture itself may compress the valuable dorsal vein. The repaired vein is found just between the tendon and skin and vulnerable to compression. We use a running or cross stitches suture by keeping the knot inside to protect valuable vein repair (*Figure 19*).

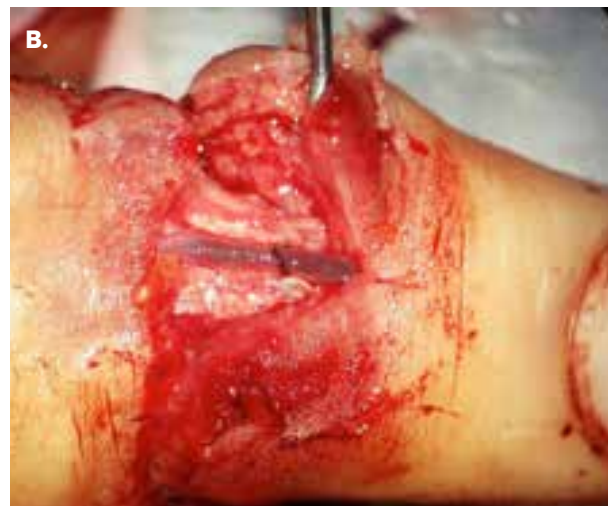
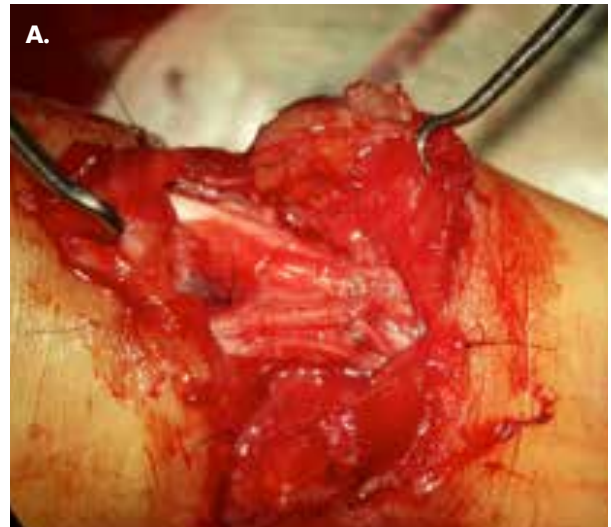
Figure 19: a) Extensor tendon repair without bulging. b) See how the valuable vein repair lies just over the tendon repair site.

Nerve repair

Nerve repairs should be performed in distal finger replantations if possible. However, nerve repair is not an essential repair that must be

performed in all distal finger replantations because protective sensation returns irrespective to nerve repair status. This was confirmed by many studies presenting good sensory recovery without nerve repair in distal finger replantations [11, 12, 13].

If bleeding from the stump artery is good and no dissection will be performed for artery then we do not do proximal exploration just for nerve in avulsion injuries because the spontaneous innervation is satisfactory without nerve repair in distal replantations (Figure 20).

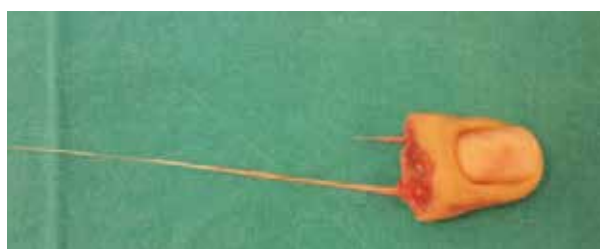

Figure 20: Avulsion injuries

Vascular repairs 12x oculars

We use 12.5x ocular instead of standard 10x oculars 12.5x ocular provides 20% extra magnification which is especially important in distal replantations. One have to increase light at these magnifications (Figure 21).

Dorsal approach for vascular repairs

Distal finger replantations have distinct technical difficulties. The vessel sizes are about 0.8 mm to 0.3 mm [5, 6]. The vessels are thin walled and their flexibility is less compared to proximal replantations. 11/0 sutures are needed in most cases. Tension is not tolerated by this very thin vessels during repair. The bulk of the pulp tissue precludes a wide view of the repair site. Retraction of skin and pulp tissue increases tension on the anastomosis. It is difficult

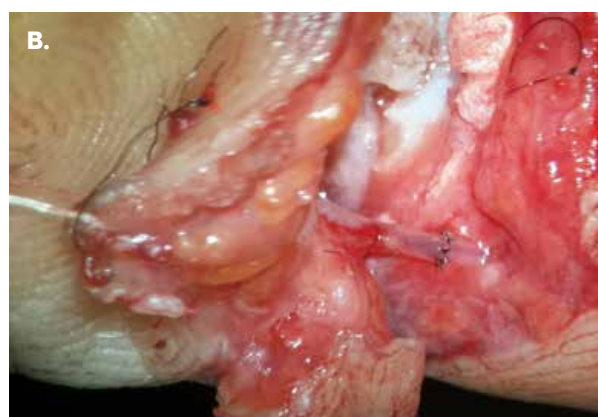
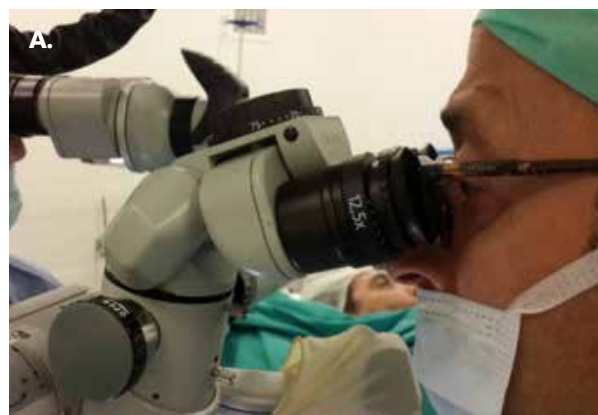
Figure 21: a) 12.5x ocular to increase magnification. b) The quality of repairs increase with extra magnification.

to use microvascular clamps in this narrow field of vision. The artery is in the deepest location just over the periosteum. Classically distal finger replantations are performed by volar approach. We use dorsal approach to overcome some of these technical difficulties. In dorsal approach the vascular repairs are performed from dorsal side before bone fixation [14] (Figure 22).

After preparing and tagging the vessels and nerves of the amputated part and proximal stump, the hand is positioned by lead hand in supine position and the uninjured fingers are fixed with lead hand (Figures 22a, 22b). A K- wire is passed to the amputated part only. The volar skin is repaired first as a hinge and the exposure is obtained from dorsal side (Figure 22b). The exposure is wide enough to

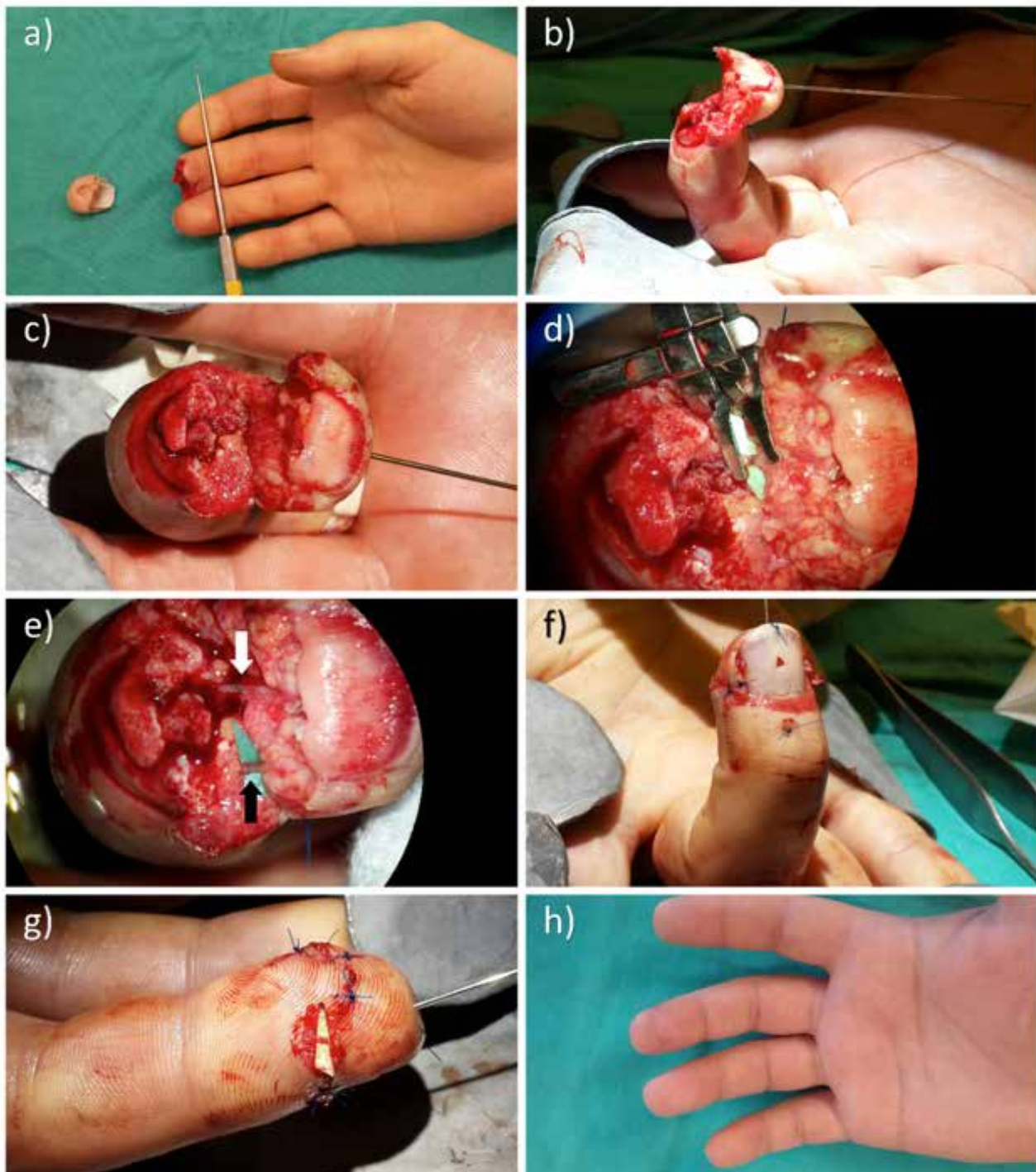


Figure 22: a) A 37-year-old male patient had a transverse Tamai Zone I amputation of the middle finger. The vessels were tagged and prepared. (b) K- wire was passed from the amputated part. Volar skin was repaired without bone fixation. The K wire's length and skin sutures were adjusted to obtain the best exposure with least tension and the amputated part was retracted to volar side using the volar skin as a hinge. The weight of the K-wire stabilized the exposure. (c) Wide exposure of the anastomosis sites was obtained. (d) The exposure was wide enough to place a microvascular clamp if needed. (e) The arterial repair was completed (white arrow). A subcutaneous volar vein was repaired without the need for a microvascular clamp (black arrow). (f) The bone was fixed and lateral skin and nail bed repair was performed and nail plate was fixed with sutures. (g) A previously tagged subdermal volar vein was repaired lastly from volar side. (h) The result at six month.

use microvascular clamp and approximator (*Figures 22c ,22d*). The structures are repaired from volar to dorsal before bone fixation. As the repairs come dorsally the number of volar skin sutures are increased or the K- wire is manipulated to obtain the best exposure with least tension. Subcutaneous volar veins repaired by dorsal approach (*Figure 22e*). After completing the repairs by dorsal approach the amputated segment is reduced carefully and the K- wire is passed to proximal bone. Lat-

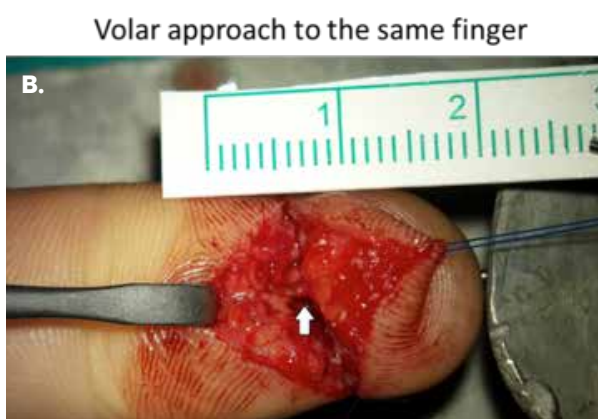
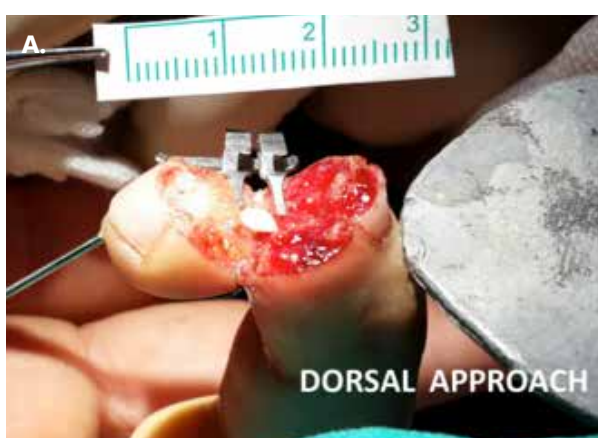
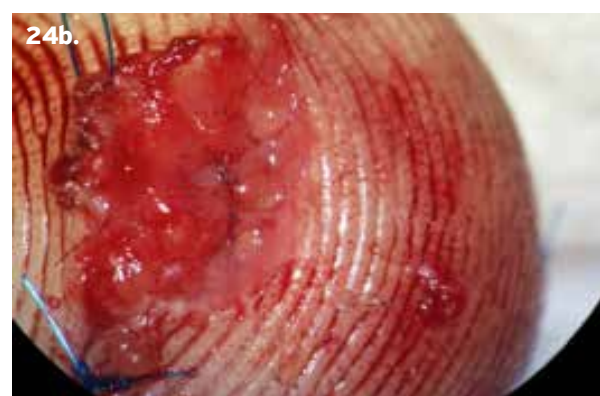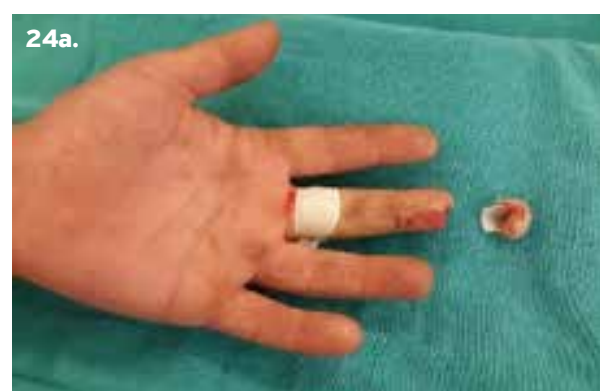Figure 23: a) The exposure of arterial repair in dorsal approach is about 2 cm without need for an assistant to retract soft tissues or without stay sutures. The cross section of cleft for vascular repairs in dorsal approach is like a semicircle providing a better exposure without soft tissue interruption. b) The volar approach to the same finger's arterial repair site (white arrow) results in a 1 cm exposure with the cross section being like a "V". The artery must be repaired at the narrowest bottom of the "V". Moreover, stay sutures and retraction of soft tissues by an assistant were needed to maintain exposure in volar approach.

eral skin and nail bed repair is performed and nail plate is fixed with sutures (*Figure 22f*). If a previously tagged subdermal volar vein will be repaired than the sutures are taken from the volar skin and the subdermal volar vein is repaired from volar side (*Figures 22 g , 22 h*).

Using dorsal approach has many advantages over volar approach [14]. Dorsal approach provides 2 times wider exposure compared to volar approach to same finger. There is no need to an assistant or stay sutures. It provides wider space for approximator compared to volar approach (*Figure 23*).

Vein repairs

The arterial fill must be balanced by venous drainage for a successful result. We routinely perform volar vein repairs [15]. Repairing volar veins is especially important in Tamai Zone I where dorsal veins do not exist (*Figure 24*).



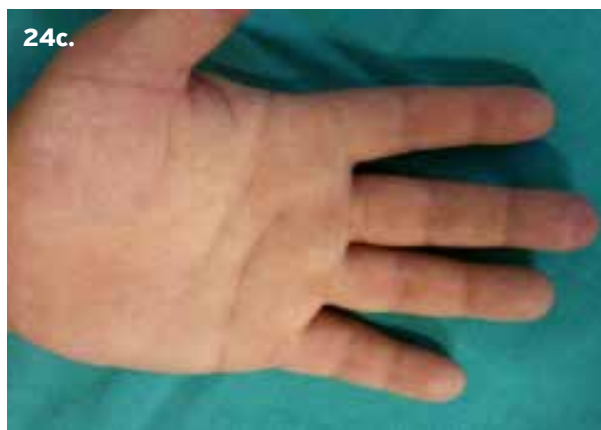

Figure 24: a) Volar veins can be found in subdermal area as in this patient. b) Two neighboring subdermal volar veins were repaired. c) View at sixth month

We frequently repair subcutaneous volar veins in distal finger replantations that are bigger than subdermal ones (*Figure 25*).

Volar veins can be located easily within the microhematomas in the subcutaneous tissue or subdermal area (*Figure 26*).

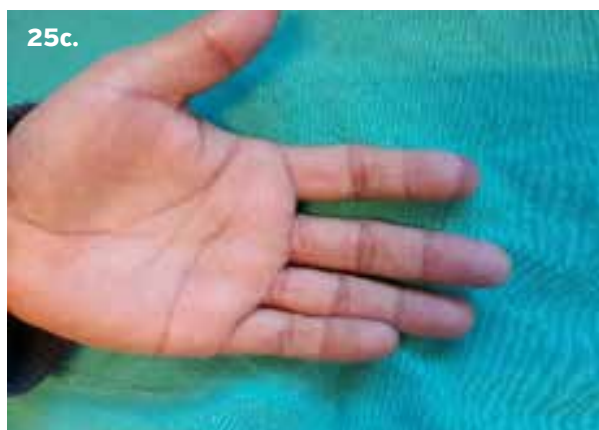
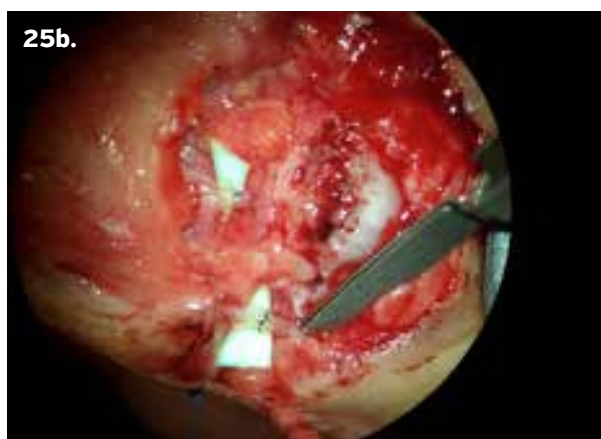
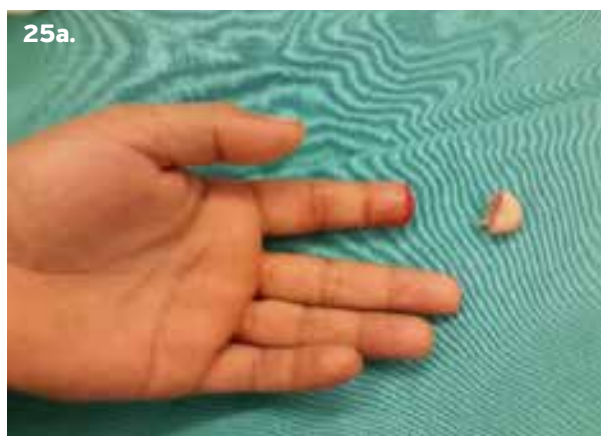Figure 25: a) Second finger amputation. b) One subcutaneous volar vein lateral to central artery is repaired by dorsal approach in this patient. c) View at fourth month

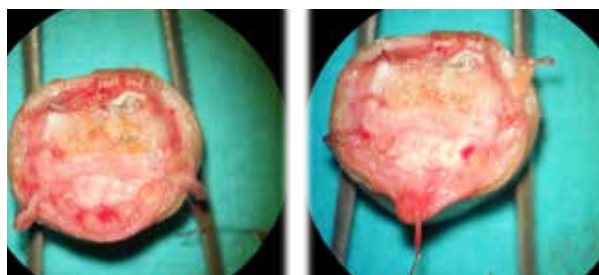


Figure 26: a) The microhematoma at the volar subcutaneous tissue. b) One subcutaneous volar vein was located within the microhematoma.

We frequently repair big volar veins within the subcutaneous tissue of pulp (*Figure 27*).

Skin closure

We always start skin closure from the vascular repair sites first. Because due to edema if we leave it to the last then the anastomosis tend to protrude from the repair site and it is possible to pass sutures from the repaired vessels (*Figure 28*).

Multiple finger

In multiple finger replantations time is important. We sometimes perform the vas-

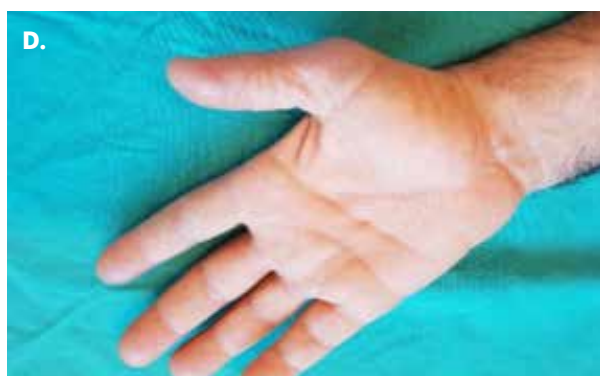
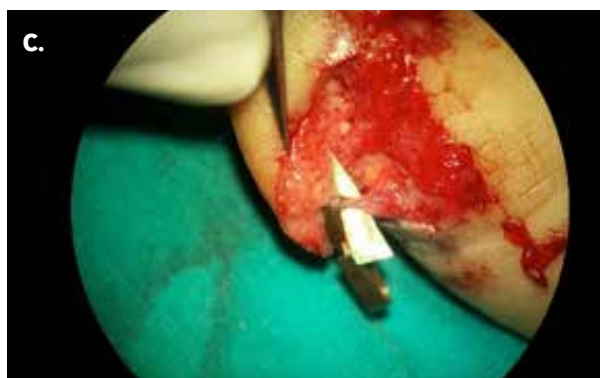
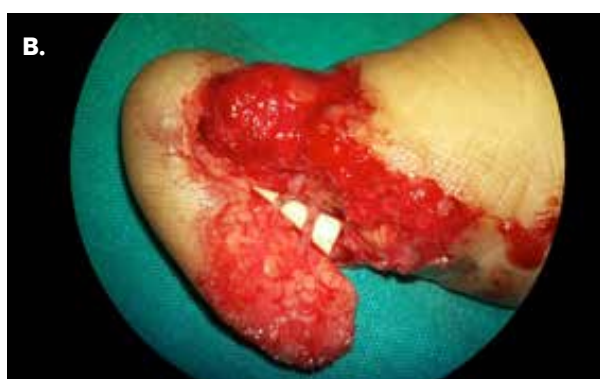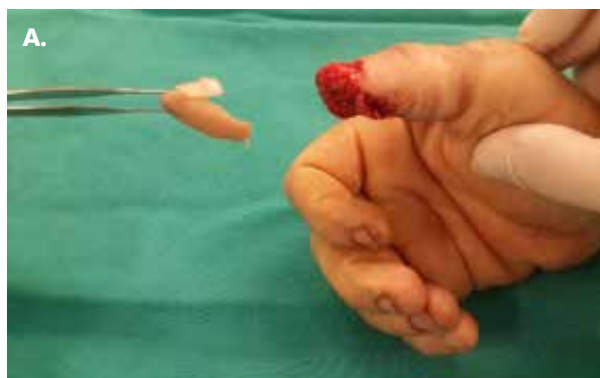Figure 27: a) Pulp amputation in a 47 years old male. b) Two arteries were repaired c) One big subcutaneous vein repair was enough to balance the arterial fill. d) View at seventh month

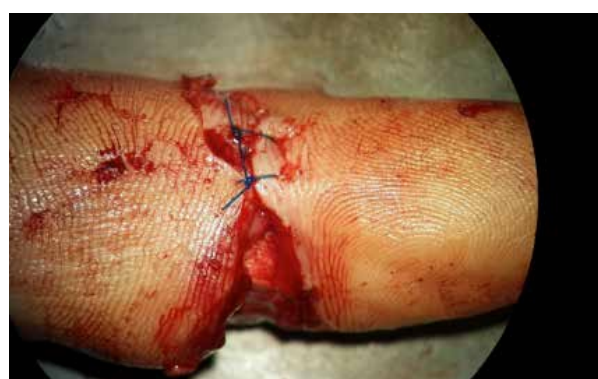
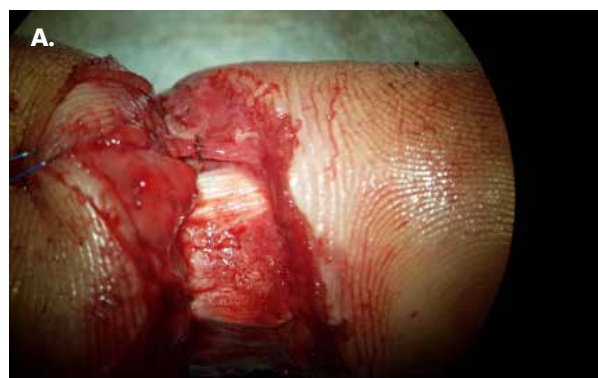
Figure 28: a) Repaired artery in a distal finger replantation. b) Skin closure was started from the repair site first to protect the anastomosis

cular repairs by two surgeons working on two different fingers with two microscopes to save time (Figure 29).

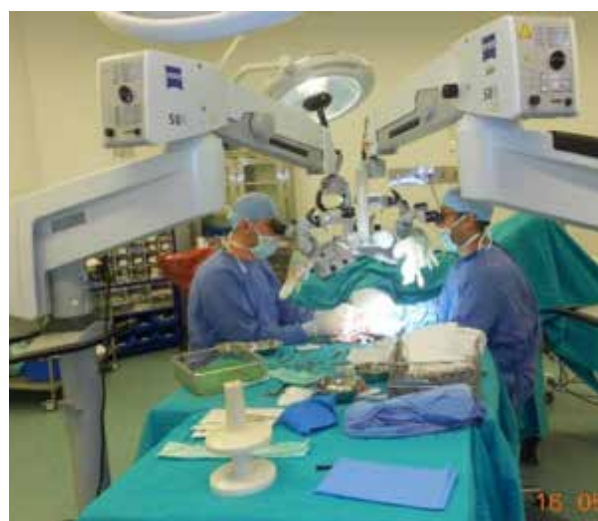

Figure 29: Two surgeons repairing different fingers simultaneously by two microscopes in a multi-finger distal replantation.

REFERENCES

1. Foucher G, Norris RW. Distal and very distal digital replantations. *Br J Plast Surg* 1992;45(3):199–203.
2. Morrison WA, McCombe D. Digital replantation. *Hand Clin* 2007;23:1–12.
3. Goldner RD, Stevanovic MV, Nunley JA, Urbaniak JR. Digital replantation at the level of the distal interphalangeal joint and the distal phalanx. *J Hand Surg [Am]* 1989;14:214–220.
4. Hattori Y, Doi K, Ikeda K, Estrella EP. A retrospective study of functional outcomes after successful replantation versus amputation closure for single fingertip amputations. *J Hand Surg* 2006;31A:811–818.
5. Strauch B, de Moura W. Arterial system of the fingers. *J Hand Surg* 1990;15A:148–154.
6. Smith DO, Oura C, Kimura C, Toshimori K. The distal venous anatomy of the finger. *J Hand Surg* 1991;16A:303–307.
7. Grabb and Smith Plastic Surgery. 3rd Edn. Boston, Little, Brown, 1979: 701.
8. Blackburn AV, Jemec B. The microsurgical instrument tray - a tremor-free assistant for stabilising amputated parts in replant surgery. *J Plast Reconstr Aesthet Surg*. 2007;60(8):961
9. Venkatramani H, Sabapathy SR. A simple technique for securing the amputated part during preparation in fingertip replantation. *Br J Plast Surg* 2004;57:592-3.
10. Kabakas F, Ugurlar M, Yigit B, Purisa H. Tissue forceps for stabilizing amputated parts in a finger replantation. *Hand and Microsurgery*. 2016;5(3):178-179
11. Ozcelik IB, Tuncer S, Purisa H, Sezer I, Mersa B, Kabakas F, Celikdelen P. Sensory outcome of fingertip replantations without nerve repair. *Microsurgery* 2008;28:524–530.
12. Faivre S, Lim A, Dautel G, Duteille F, Merle M. Adjacent and spontaneous neurotization after distal digital replantation in children. *Plast Reconstr Surg* 2003;111:159–165
13. Wong C, Ho PC, Tse WL, Cheng S, Chan DK, Hung LK. Do we need to repair the nerves when replanting distal finger amputations? *J Reconstr Microsurg* 2010;26:347–354.
14. Kabakaş F. Dorsal approach for vascular repairs in distal finger replantations. *Microsurgery*. 2016 Nov;36(8):628-636
15. Mersa B, Kabakas F, Pürisa H, Özçelik IB, Yeşiloğlu N, Sezer I, Tunçer S. Advantages of using volar vein repair in finger replantations. *J Plast Reconstr Aesthet Surg*. 2014 Jan;67(1):63-7

Harvesting A Toenail Flap Based On The Fibro-Osseous Hiatus Branch

17

Sae Hwi Ki

Dept. of Plastic Surgery, Inha University, School of the Medicine

Author had performed about 40 nail reconstructions with the microsurgical nail transfer method for 12 years. Based on the personal experience, I show the cadaver dissection to elucidate the perfusion of toenail flaps by the fibro-osseous hiatus branch (FHB), and toenail flap harvesting technique, microsurgical revascularization technique with clinical cases for reconstruction of a fingernail defect.

Four second toes of two fresh Korean cadavers were dissected. We try to find the perfusion of the toe-nail tissue, and apply the

anatomical knowledge to the clinical series of the nail defect patients. The plantar digital artery (PDA) and terminal segment branch (TSB) were ligated, and red latex was injected distally into the ligated PDA.

The results of perfusion study showed that one side of the unilateral FHB was identified and traced proximal to the PDA, which was ligated. The distal toe-nail bed was perfused by the dye through the FHB. The toe-nail flap was marked at 5 mm distal to the nail fold and 5 mm lateral to the paronychium.

From 2004 to 2016, 40 toenail flaps based on the FHB pedicle with or without toe pulp were applied to 34 patients for finger nail reconstruction. The toe-nail complex based on the FHB was elevated and transferred to the finger. The nail and matrix were elevated with or without including the distal phalanx.

All the toe-nail flaps survived.

In conclusion, the vascularized toe-nail flap can be transferred with a minimum amount of soft tissue, depending on the FHB, because FHB is large enough to supply blood and can be included in 5 mm margin from eponychium and paronychium.

Reconstruction of the Elbow Flexion with Modified Oberlin Procedure

18

Zinon T. Kokkalis, MD, PhD¹, Aikaterini Bavelou, MD¹, Panayotis N. Soucacos, MD, PhD²

¹ University of Patras, School of Medicine, University Hospital of Patras, Department of Orthopaedics, Rio-Patras, Greece

² First Department of Orthopaedics, National and Kapodistrian University of Athens, School of Medicine, Attikon University Hospital, Athens, Greece

Introduction

Throughout most of its history, the surgical management of brachial plexus injuries was associated with pessimism, but the greater understanding of the processes of nerve healing and the advances of microsurgical techniques and instrumentation during the last decades, have led to better outcomes. Nerve transfers have been used with increasing frequency for the reconstruction of brachial plexus injuries. Many

options exist for the restoration of the elbow flexion and the most appropriate depends largely on the availability of donor motor nerves [1].

In 1994 Oberlin et al [2] described the transfer of one fascicle of the ulnar nerve to the biceps branch of the musculocutaneous nerve, in order to restore elbow flexion. Their original description consisted of a series of four patients and a cadaveric study of the branching pattern of the musculocutaneous nerve to the biceps muscle. No loss

of ulnar nerve function was found postoperatively at the clinical examination.

Then, in 2003, Mackinnon et al [3] suggested reinnervation of both the biceps and the brachialis muscles in order to maximize the potential of recovery of strong elbow flexion. They considered the fact that the biceps muscle acts as a primary forearm supinator and only as a secondary flexor of the elbow, whereas the brachialis is the primary muscle providing elbow flexion. Four different nerve donors were used for transfer to the brachialis branch of the musculocutaneous nerve: the medial pectoral, intercostals, and thoracodorsal nerves, along with a triceps branch of the radial nerve, with MABC and LABC used as nerve grafts. Eight patients were reviewed in this study, with MRC Grade 4 in five patients and 4+ in three. Reinnervation of both the biceps and the brachialis muscles was confirmed in EMG studies. Ulnar nerve function was not downgraded in any patient. In conclusion, the writers note that the Oberlin FCU fascicle transfer procedure provides a reliable source of donor motor axons for transfer in brachial plexus injuries and allows reinnervation of the biceps muscle without functional donor sequelae, but in some patients where the quantity of functioning motor axons may not be sufficient, the additional nerve transfer to reinnervate the brachialis muscle provides maximal recovery of elbow flexion strength.

In 2005 Mackinnon et al [4] reported results on the simultaneous use of the median and ulnar nerves as donors for the double fascicle transfer to the two elbow flexors. The use of an expendable fascicle of the median nerve as a donor nerve in a similar fashion to the FCU transfer has previously been described to reinnervate the biceps

muscle after brachial plexus injury [5,6]. The authors noted that the motor fascicles in the median nerve are found on the medial side of the median nerve and the sensory component on the lateral side of the median nerve. The motor component of the ulnar nerve is located on the lateral or central portion of the ulnar nerve. To locate fascicles of appropriate caliber and sufficient length for direct transfer internal neurolysis of these nerves was performed adjacent to the biceps and brachialis branches. The brachialis branch was neurolysed proximally, divided, and moved over toward the median or ulnar nerve to select the best match to the donor nerve. Either the median or ulnar nerve was used as a donor for either the biceps or brachialis transfer depending on the match to the recipient nerve. The fascicle used for transfer usually made up 15 to 20% of the entire nerve.

Surgical Procedure - How I Do It

In this paper, we present our modified technique of the double fascicle transfer to the two elbow flexors from two fascicles of the ulnar nerve only as a donor nerve.

With the patient in supine position and the arm in lateral abduction, a 12-15 cm incision is made along the medial arm beginning at the pectoralis and coursing distally along the neurovascular bundle. Initially, the biceps is identified and an incision is made on the fascia and the muscle is retracted laterally. The musculocutaneous nerve is identified between the biceps and the coracobrachialis muscles. It is then dissected from proximal to distal and from medial to lateral. The nerve to the biceps is identified. According to Oberlin [2] the mean

distance from the acromion to the origin of the nerve to the biceps is 12 cm. The ulnar nerve is approached in the same level. The motor branch destined to the biceps is identified and then split proximally from the musculocutaneous nerve for approximately 2 cm and transected. The distal part is then rotated medially toward the dissected ulnar nerve. Then, dissecting distally the musculocutaneous nerve, the branch destined to the brachialis is identified and split carefully proximally into the musculocutaneous nerve for approximately 3-5 cm and transected. Attention should be paid in order to get adequate length of this branch to reach the proper fascicle of the ulnar nerve. The dissected branch is then rotated backward to the previously dissected ulnar nerve.

The epineurium of the ulnar nerve is incised and two fascicles are selected and elec-

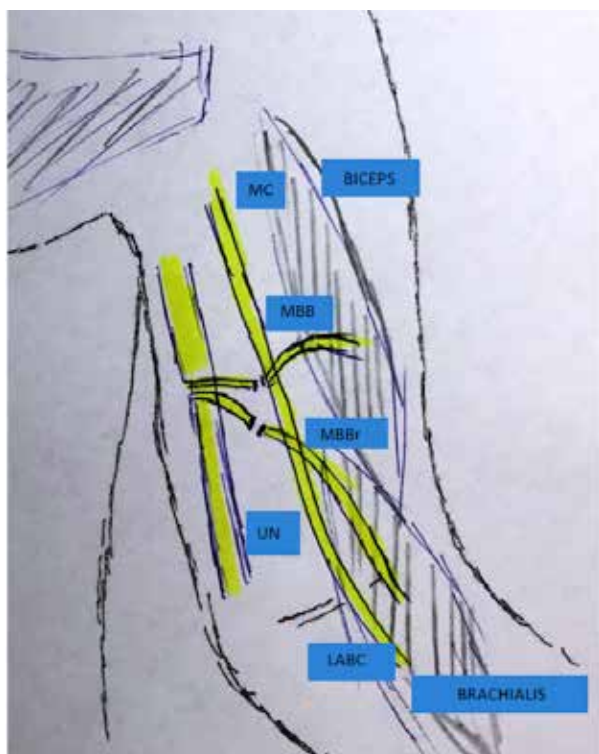


Figure 1: Schematic illustration of the procedure. MC: musculocutaneous nerve, MBB: motor branch of the biceps, MBBr: motor branch of the brachialis, UN: ulnar nerve, LABC: lateral antebrachial cutaneous nerve.

trically stimulated in order to distinguish between sensory and motor fascicles. The motor component of the ulnar nerve is located on the lateral or central portion of the ulnar nerve. The chosen fascicles, normally the fascicles for the FCU (flexor carpi ulnaris) are separated from the ulnar nerve over 2 cm and divided distally. Then the fascicles are turned laterally and sutured separately, one to the motor branch to the biceps, and the other to the branch of the brachialis with 10.0 nylon, without any tension. Fibrin glue is added to enhance the neurorraphy (*Figures 1 & 2*).

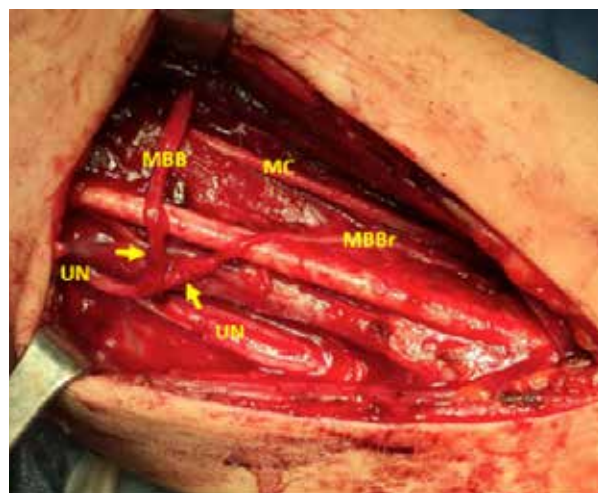


Figure 2: Intraoperative image of the procedure. MC: musculocutaneous nerve, MBB: motor branch of the biceps, MBBr: motor branch of the brachialis, UN: ulnar nerve.

Rehabilitation

The upper extremity is immobilized in a sling for 1 month. The subsequent physiotherapy includes passive ROM of the shoulder, elbow and hand. Electrotherapy is initiated at 2 weeks and continued for up to 6 months. The earliest contractions in the biceps are seen between 2-4 months after surgery. The patient is then asked to initiate

active supination exercises. Physiotherapy is carried out for 9 more months.

Discussion

In a follow-up of 32 patients reported in 2004 by Oberlin et al [7] elbow flexion of Medical Research Council (MRC) grades 3 to 4 was achieved in 94% of cases and no significant donor morbidity was seen. Ten patients, however, secondarily required a Steindler flexorplasty to obtain satisfactory elbow flexion. Additionally, after the use of median and ulnar nerve as donors for the two elbow flexors, as Mackinnon et al reported [4], clinical evidence of reinnervation was noted at a mean of 5.5 months after surgery and the mean follow-up period was 20.5 months. Mean recovery of elbow flexion was MRC grade 4+. Postoperative pinch and grip strengths were unchanged or better in all patients. No motor or sensory deficits related to the ulnar or median nerves were noted and all patients maintained good hand function. No patients required additional procedures to further improve elbow flexion strength. The authors concluded that the transfer of expendable motor fascicles from the ulnar and median nerves, without the need for nerve grafts, can successfully reinnervate the biceps and brachialis muscles for strong elbow flexion without functional or sensory donor morbidity. Then, in 2009 Oberlin et al [8] also observed that the double transfer provides better results than one single.

In our experience with 5 patients, using our modified technique of the double fas-

cicle transfer to the two elbow flexors from two fascicles of the ulnar nerve, all patients showed clinical evidence of reinnervation in approximately 6 months and gained full muscle strength, as well as range of motion (*Figure 3*). Unfortunately, our sample size is limited, but according to previous results in the bibliography and our experience, we propose this modified technique of the double fascicle transfer from the ulnar nerve, as it reserves the median nerve, allows reinnervation of both elbow flexors and no type of motor or sensitive problem are found in the ulnar territory.



Figure 3: This patient underwent our modified technique of the double fascicle transfer to the two elbow flexors from two fascicles of the ulnar nerve and he gained full muscle strength (M5), as well as range of motion, at 15 months after surgery.

REFERENCES

1. Tung TH, Mackinnon SE. Brachial plexus injuries. *Clin Plastic Surg*. 2003;30:269-287.
2. Oberlin C, Béal D, Leechavengvongs S, Salon A, Dauge MC, Sarcy JJ. Nerve transfer to biceps muscle using a part of ulnar nerve for C5-C6 avulsion of the brachial plexus: Anatomical study and report of four cases. *J Hand Surg Am*. 1994;19(2):232-237. doi:10.1016/0363-5023(94)90011-6.
3. Tung TH, Novak CB, Mackinnon SE. Nerve transfers to the biceps and brachialis branches to improve elbow flexion strength after brachial plexus injuries. *J Neurosurg*. 2003;98(2):313-318. doi:10.3171/jns.2003.98.2.0313.
4. Mackinnon SE, Novak CB, Myckatyn TM, Tung TH. Results of reinnervation of the biceps and brachialis muscles with a double fascicular transfer for elbow flexion. *J Hand Surg Am*. 2005;30(5):978-985. doi:10.1016/j.jhssa.2005.05.014.
5. Sungpet A, Suphachatwong C, Kawinwonggowit V. One-fascicle median nerve transfer to biceps muscle in C5 and C6 root avulsions of brachial plexus injury. *Microsurgery*. 2003;23(1):10-13. doi:10.1002/micr.10079.
6. Hou Z, Xu Z. Nerve transfer for treatment of brachial plexus injury: comparison study between the transfer of partial median and ulnar nerves and that of phrenic and spinal accessory nerves. *Chinese J Traumatol = Zhonghua chuang shang za zhi*. 2002;5(5):263-266. <http://www.ncbi.nlm.nih.gov/pubmed/12241634>. Accessed January 14, 2018.
7. Teboul F, Kakkar R, Ameer N, Beaulieu J-Y, Oberlin C. Transfer of fascicles from the ulnar nerve to the nerve to the biceps in the treatment of upper brachial plexus palsy. *J Bone Joint Surg Am*. 2004;86-A(7):1485-1490. <http://www.ncbi.nlm.nih.gov/pubmed/15252097>. Accessed January 14, 2018.
8. Oberlin C, Durand S, Belheyar Z, Shafi M, David E, Asfazadourian H. Nerve transfers in brachial plexus palsies. *Chir Main*. 2009;28(1):1-9. doi:10.1016/j.main.2008.11.010.

Vascularized fibula Grafts in Musculoskeletal Oncology

19

Vasileios A. Kontogeorgakos¹, George Panagopoulos¹, Zoe Dailiana², Panayotis J. Papagelopoulos¹

¹ Department of Orthopaedic Surgery, ATTIKON University Hospital Xaidari, Athens, Greece

² Medical School, University of Thessaly, Larissa, Greece

Introduction

Bone sarcomas are rare malignant mesenchymal tumors of the musculoskeletal system. [1] In the past, the main treatment modality was essentially amputation of the involved limb, whereas 5-year survival was very low. However, during the last three decades, limb salvage has become the rule rather than the exception, as the use of neoadjuvant and adjuvant therapies (radiation and chemotherapy) has dramatically increased tumor resectability

and disease-free survival. For example, until late 70's the treatment of choice of a patient with osteosarcoma was unequivocally limb amputation. Results were extremely poor, with a 2-year incidence of metastatic disease of about 80% and an overall 5-year survival of approximately 20%. [2] Neoadjuvant chemotherapy, combined by limb-salvage surgery and followed by adjuvant chemotherapy is now the treatment modality of choice for the vast majority of such patients, with a 5-year survival now reaching 66%. [3]

Reconstruction of large tissue defects still remains a big challenge in tumor surgery patients. In particular, vascularized tissue transfer has been proved to be very helpful in the management of complex tissue or functional defects that are frequent results after radical tumor resection. The principles, indication and results of microsurgical reconstruction are directly related not only to the underlying disease process, but also to the local and systemic therapeutic modalities (adjuvant therapies) applied to the individual patient.

Surgical resection of malignant pelvic or limb bone sarcomas (or benign but aggressive tumor) may result in large bone and soft tissue defects. Frequently bone sarcomas have a metaphyseal location with extension to the epiphysis or/and the diaphysis. Usually the tumor penetrates the cortex extending into the soft tissue (stage IIB Enneking). The goal of surgical treatment is resection of the bone tumor with the soft tissue extension attached, to negative histologic margins. Based on location and extent, such osseous defects can be addressed with the use of a vascularized bone graft, an allograft or by the use of an endoprosthesis.

Vascularized Fibula Grafts. Indications, Results and Complications

The use of a vascularized fibula in the treatment of posttraumatic defects, infected non-unions or congenital pseudoarthrosis is well established. [4-8] The vascularized fibula flap has also been widely used for reconstruction of bone defects after tumor resection in the mandible, in long bones, for spinal stabilization after vertebrectomy and for pelvic re-

construction after internal hemipelvectomy (*Figure 1*). [3, 9-11] It can also be used in conjunction with muscle or a skin island, in order to achieve simultaneous soft tissue coverage (*Figure 2*). [7, 11] Innocenti et al., [12] based on a previous cadaveric study by Taylor et al., [13] have described a vascularized transfer of the proximal epiphysis-diaphysis of the fibula, supplied by a branch of the anterior tibial artery. The transferred epiphysis maintained approximately 80% of its growth potential. As it is covered by articular cartilage, the proximal fibular epiphysis can be used to reconstruct an articular surface (i.e., distal radius), aiding on the same time longitudinal growth. [14]

A direct comparison of the use of a vascularized fibular graft either for posttraumatic or tumor defects has yielded better results in the tumor group of patients. This has been attributed to the greater soft tissue damage (more tissue scarring and tissue hypoxia) usually seen in the posttraumatic group [6].

However, the use of vascularized fibula for reconstruction after bone sarcoma resection is undoubtedly associated with a complication rate reported to be as high as 33-55%. Most of these complications can be managed, and do not typically lead to limb loss. The three main complications are infection, nonunion, and stress fracture. [7, 15-18]

Despite the high biologic potential of the vascularized fibular graft, delayed union and nonunion do occur, the main contributing factor being inadequate fixation. In such a case, the fixation typically needs to be revised and stable fixation augmented by autologous bone graft is suggested. Eward et al on a study for 30 vascularized fibula graft for oncologic bone defects, reported a 77% of primary union rate at a mean time of 6 months. [18] The remaining fibular grafts healed after revision

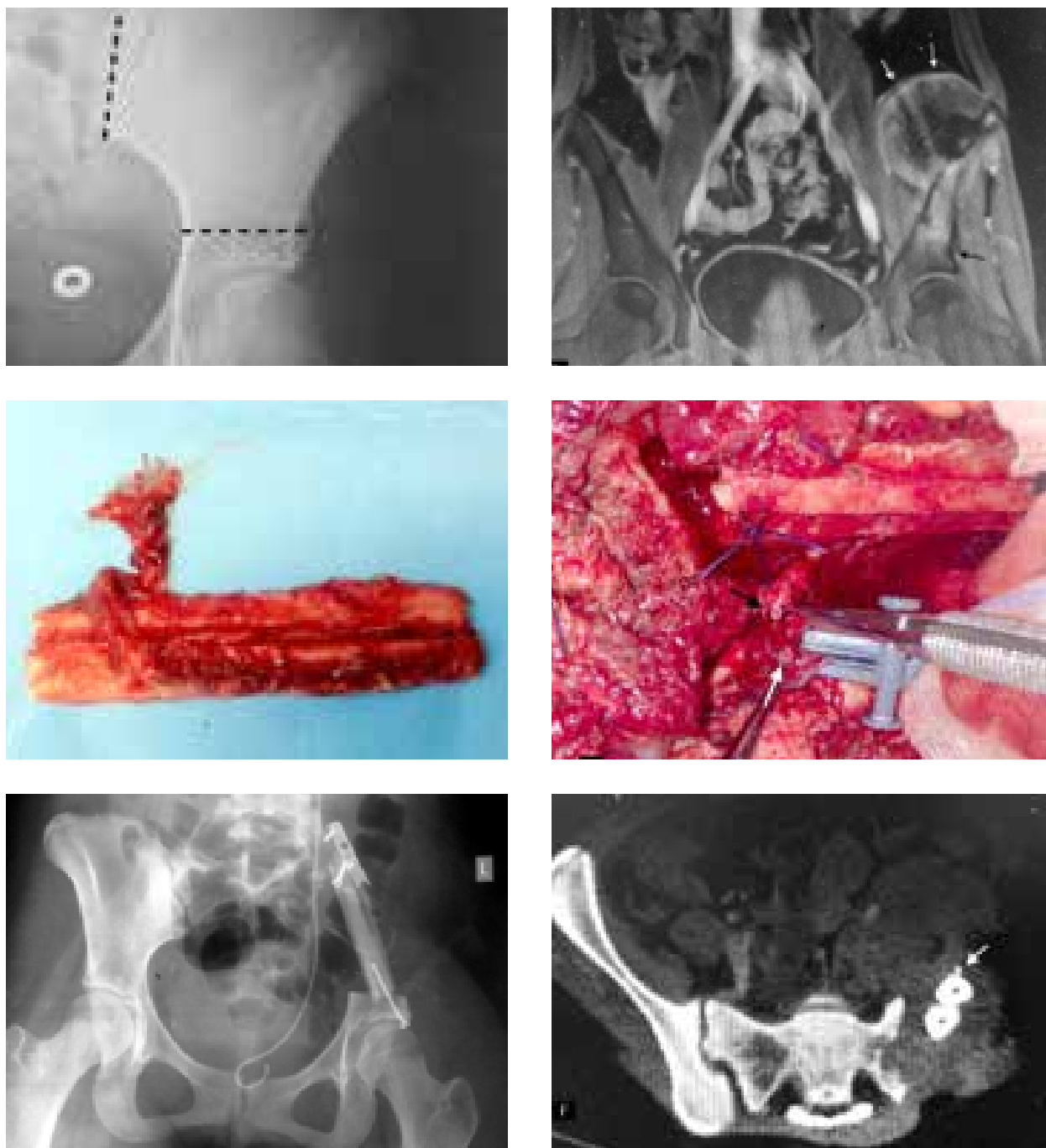


Figure 1: Ewing sarcoma of the left iliac wing of 12-year-old girl. A,B: There is tumor extension in the soft tissue. Intra-osseous extension of the tumor up to 3 cm above the acetabulum. The patient underwent 3 months pre-op chemotherapy and internal hemipelvectomy type I (iliac wing with osteotomy above acetabulum) was performed. C: A free vascularized fibula graft was harvested and shaped in a double barrel strut. The two segments were fixed with a screw. D: The peroneal artery (black arrow) was anastomosed to superior gluteal artery (white arrow). E: The double barrel fibula graft was fixed with small plates and screws to lateral sacrum proximally and a screw distally at the supra-acetabular area. F: CT angiography at follow-up revealed patent peroneal artery (arrow).

with stable osteosynthesis and bone auto-graft with an index of 1.33 additional operations per patient. [18] Mean time to union for

these patients was 9.2 months and the total complication rate in this series was 53%.

Stress fractures usually occur within a year

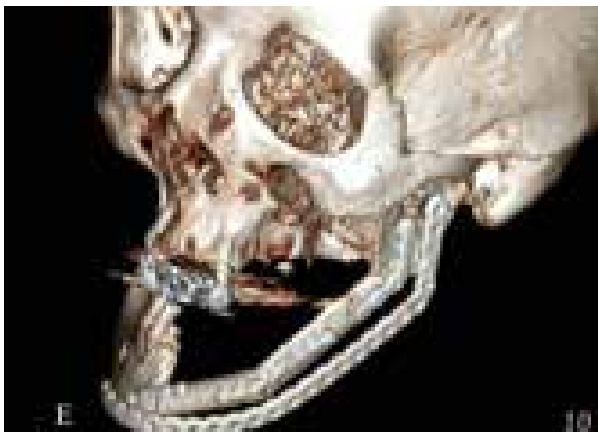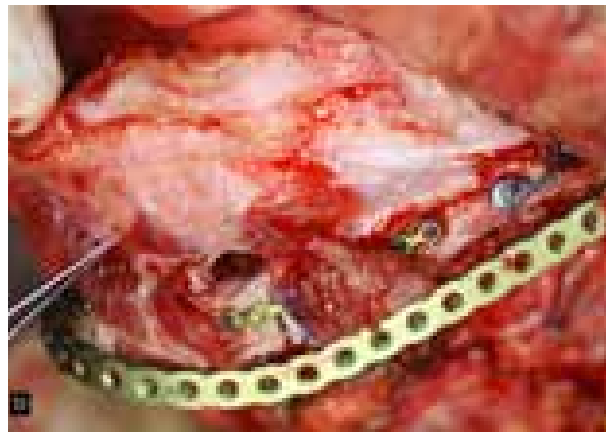
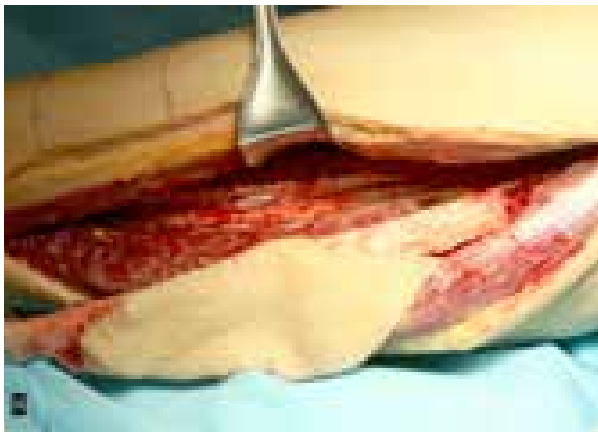

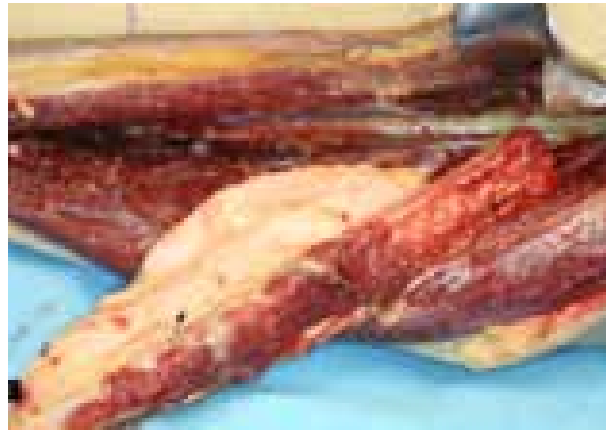
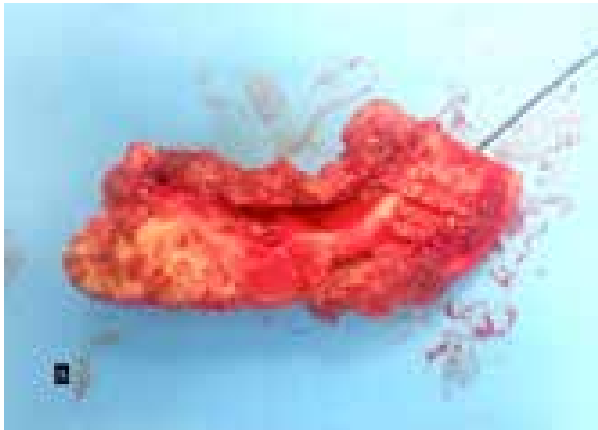Figure 2: A: Left jaw after malignant tumor resection. B: Because of bone and soft tissue defect a free vascularized fibula graft with a skin paddle was harvested. C: Perforator from the peroneal artery nourishing the skin paddle (black arrow) D: The fibula was subperiosteally osteotomized and the osteotomy site was fixed with mini plates and screws. Anastomosis was performed to the superior thyroid artery. E: 3D CT of the reconstruction.

of achievement of union of the fibular graft to the recipient site. Conservative management of stress fractures typically results in abundant callous formation and fibular hypertrophy [7, 10, 15]. In a study performed by Sainsbury et al., 19 vascularized fibular grafts were used to reconstruct lower limb bone defects after tumor resection in children. [19] Graft survival was reported to be 95%, union was achieved

in a mean of 24 months and the incidence of fibular fracture was 52.6%. 90% of patients reported to be satisfied of the procedure.

Recently Houdek et al reported on 109 free vascularized fibula grafts; 52% performed for oncologic defects. [20] In their study, the indication for surgery did not impact on union rate of the graft. Union was achieved after the initial procedure in 70% at a mean of ten months and overall union was achieved in 91%. Although chemotherapy and diabetes mellitus posed an increased hazard ratio for

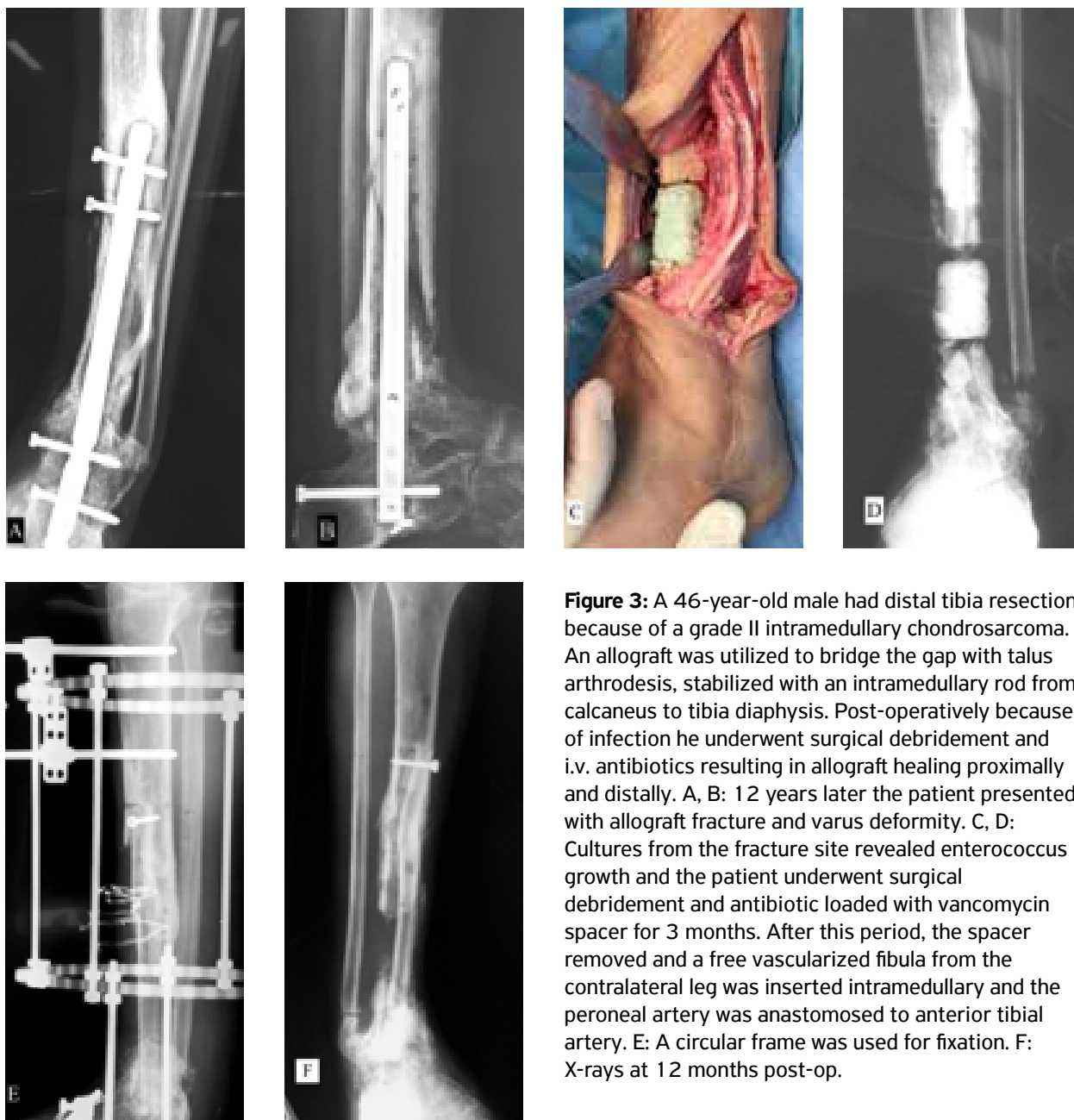

Figure 3: A 46-year-old male had distal tibia resection because of a grade II intramedullary chondrosarcoma. An allograft was utilized to bridge the gap with talus arthrodesis, stabilized with an intramedullary rod from calcaneus to tibia diaphysis. Post-operatively because of infection he underwent surgical debridement and i.v. antibiotics resulting in allograft healing proximally and distally. A, B: 12 years later the patient presented with allograft fracture and varus deformity. C, D: Cultures from the fracture site revealed enterococcus growth and the patient underwent surgical debridement and antibiotic loaded with vancomycin spacer for 3 months. After this period, the spacer removed and a free vascularized fibula from the contralateral leg was inserted intramedullary and the peroneal artery was anastomosed to anterior tibial artery. E: A circular frame was used for fixation. F: X-rays at 12 months post-op.

nonunion, only smoking reached statistical significance. Thus, the authors recommend that patients stop smoking at least four weeks before the operation.

Vascularized Fibula Grafts and Structural Bone Allografts

During the 80's and 90's, the use of structural bone allografts for large bone defects

was popularized. Defects with an intra-articular extension can be addressed with osteoarticular allografts, whereas diaphyseal defects can be reconstructed with diaphyseal structural allografts. However, after an early enthusiasm, it was observed that allograft use was associated with a significant amount of complications, especially in the case of distal femoral osteoarticular allografts, and for diaphyseal allografts exceeding 15 cm in length [21-24]. The three main complica-

tions include infection, nonunion and allograft fracture [23, 26]. Management of such complications is not as easy, though. Surgical debridement for infection and fixation revision and bone graft for fractures and nonunion do not yield reliable results. [26, 27].

The primary use of rotational or free vascularized flaps in conjunction with an allograft, in the same setting with tumor resection, has been shown to reduce allograft failure and infection rates [28]. The use of a vascularized fibular graft as a salvage procedure for already instituted complications has also been shown to be effective (*Figure 3*). [27-30]

Bae et al. [27] employed a vascularized fibular graft in 8 patients with allograft nonunion, obtaining union in 7 patients (88%), pain relief and limb conservation. Friedrich et al. [30] used a vascularized fibula as a salvage procedure in 33 patients after institution of allograft related complications (25 nonunions, 6 infections, 2 fractures). Mean time to union was 7.7 months. Ten major complications arisen, five of which were relates to infection. 23 patients had a very good or good function result; five patients underwent limb amputation.

Capanna et al. [31] employed a hybrid reconstruction technique, involving the combined use of a structural allograft and a vascularized fibular graft. The allograft provided mechanical and structural support, until the vascularized fibula could hypertrophy and incorporate, thus reducing the chance of a stress fracture and facilitating patient rehabilitation and limb use. Moreover, it was theorized that the vascularized fibula biological potential would reduce complications related to the presence of an avascular allograft, such as infection. Two different techniques have been described.

In one of these techniques, the vascularized fibula is placed directly into the allograft

lumen (inlay technique) [31,32]. This can be achieved in one of two ways: (1) the fibula is dragged into the lumen of the allograft through one of the bone ends, with its vascular supply passing through a hole in the allograft cortex; (2) a longitudinal cortical window is created in the desired level, wide enough to accommodate the harvested vascularized fibula. The graft is placed in the allograft cavity, so that its vascular supply is not compressed and can be easily anastomosed to the area's existing vascular network. The allograft bridges the bone defect and is secured in place with rigid fixation (plates and screws). The harvested fibula is usually 4-6cm longer, so as to accommodate to the proximal and distal parts of the pre-existing defect. This technique is particularly helpful in the case of tibial tumors, as diaphyseal allografts are usually straight and can easily accommodate a relatively straight fibular graft. Depending on mechanical loads and degree of vascular supply, fibula may undergo either hypertrophy or atrophy [33].

In the second method, the vascularized fibular graft is placed on the structural allograft (onlay technique) [31,34]. This method is preferred for arthrodesis of the humerus to the scapula and for large femoral defects, as anterior femoral bowing does not usually allow for the insertion of a straight fibular graft [7,31,34]. However, the fibular graft can be inserted within the medullary canal (inlay technique) of a femoral allograft through an extended cortical window but the fibula has to be subperiosteally osteotomized in order to follow the anterior femoral bowing.

As intramedullary rod fixation is not favored any more for the onlay technique, the allograft is fixed in place with plate and locked screws, whereas the free vascular-

ized fibula is placed medially and fixed on the femoral cortex with a proximal and a distal cortical 3.5 mm screw. After allograft and fibula graft fixation the microvascular anastomoses are performed. The descending branch of the deep lateral circumflex femoral artery, running between the rectus femoris and the vastus lateralis muscle, is a reliable artery that can be used for anastomosis and should be preserved during tumor resection surgery (if not close to the tumor margins). Otherwise perforating arteries from the profunda femoris artery can be used for anastomosis.

In a series published by Chang et al., [34] a hybrid technique was used in 7 out of 8 patients. Union was achieved in a mean of 10 months. Innocenti et al. [35] used this method in 10 patients with bone sarcomas of the tibia. Fibular graft survival was confirmed in 25 out of 27 patients. Mean time to union was 5.4 months for the fibular graft and 19.1 months for the allograft. Significant fibula hypertrophy (>20%) occurred in 94.4% of cases. A stress fracture occurred in 3 patients, usually within 10 months of the procedure, which subsequently went to full union after 2 months of conservative treatment. Full weight bearing was achieved in a mean of 21.6 months (range, 15-36). 47.6% of patients developed a complication. Local recurrence rate was 9.5%, whereas metastatic disease occurred in 14.3% of patients.

In the past, it was hypothesized that the use of free flaps would lead to an increase

in angiogenesis that would ultimately favor malignancy recurrence [36]. Studies that followed attempted to compare the rate of local or systemic recurrence in patients who had a flap versus in those who did not have one. Multivariate analysis failed to demonstrate an increased local recurrence rate or a decrease in survival in patients who had a vascularized fibular graft or free soft tissue flap [18, 37].

Conclusion

In the current decade, the treatment of a patient suffering from a musculoskeletal malignancy is highly individualized and essentially based on a multidisciplinary approach. Surgical resection to negative margins remains the cornerstone of bone sarcomas treatment. The increased use of limb salvage causes an increased incidence of postoperative tissue and functional defects, as well as wound complications, that now have to be addressed more often. Reconstruction in musculoskeletal oncology needs to be part of a wider management strategy, that must take into account not only tumor resection surgery, but also the need for adjuvant treatments, such as chemotherapy and radiation. Use of the vascularized fibula flap does not seem to compromise oncologic surgery principles. Even when complications arise, these are usually manageable and the limb can typically be salvaged.

REFERENCES

1. Finnish Cancer Registry. Cancer in Finland 2004 and 2005. Cancer Society of Finland. Helsinki 2007.
2. Friedman MA, Carter SK. The therapy of osteogenic sarcoma: current status and thoughts for the future. *J Surg Oncol.* 1972;4(5):482-510
3. Bacci G, Forni C, Longhi A, et al. Local recurrence and local control of non-metastatic osteosarcoma of the extremities: a 27-year experience in a single institution. *J Surg Oncol.* Aug 1 2007;96(2):118-123.
4. Minami A, Kasashima T, Iwasaki N, Kato H, Kaneda K. Vascularised fibular grafts. An experience of 102 patients. *J Bone Joint Surg Br.* Sep 2000;82(7):1022-1025.
5. Chhabra AB, Golish SR, Pannunzio ME, Butler TE, Jr., Bolano LE, Pederson WC. Treatment of chronic nonunions of the humerus with free vascularized fibula transfer: a report of thirteen cases. *J Reconstr Microsurg.* Feb 2009;25(2):117-124.
6. Malizos KN, Nunley JA, Goldner RD, Urbaniak JR, Harrelson JM. Free vascularized fibula in traumatic long bone defects and in limb salvaging following tumor resection: comparative study. *Microsurgery.* 1993;14(6):368-374.
7. Pederson WC, Person DW. Long bone reconstruction with vascularized bone grafts. *Orthop Clin North Am.* Jan 2007;38(1):23-35
8. Bumbasirevic M, Stevanovic M, Bumbasirevic V, Lesic A, Atkinson HD. Free vascularised fibula grafts in orthopaedics. *Int Orthop.* 2014 Jun;38(6):1277-82
9. Shin AY, Dekutoski MB. The role of vascularized bone grafts in spine surgery. *Orthop Clin North Am.* Jan 2007;38(1):61-72
10. Minami A, Kaneda K, Satoh S, Abumi K, Kutsumi K. Free vascularised fibular strut graft for anterior spinal fusion. *J Bone Joint Surg Br.* Jan 1997;79(1):43-47.
11. Toma CD, Dominkus M, Pfeiffer M, Giovanoli P, Assadian O, Kotz R. Metatarsal reconstruction with use of free vascularized osteomyocutaneous fibular grafts following resection of malignant tumors of the midfoot. A series of six cases. *J Bone Joint Surg Am.* Jul 2007;89(7):1553-1564.
12. Innocenti M, Ceruso M, Manfrini M, et al. Free vascularized growth-plate transfer after bone tumor resection in children. *J Reconstr Microsurg.* Feb 1998;14(2):137-143.
13. Taylor GI, Wilson KR, Rees MD, Corlett RJ, Cole WG. The anterior tibial vessels and their role in epiphyseal and diaphyseal transfer of the fibula: experimental study and clinical applications. *Br J Plast Surg.* Sep 1988;41(5):451-469.
14. Innocenti M, Delcroix L, Manfrini M, Ceruso M, Capanna R. Vascularized proximal fibular epiphyseal transfer for distal radial reconstruction. *J Bone Joint Surg Am.* Jul 2004;86-A(7):1504-1511.
15. Kasashima T, Minami A, Kutsumi K. Late fracture of vascularized fibular grafts. *Microsurgery.* 1998;18(5):337-343.
16. Gebert C, Hillmann A, Schwappach A, et al. Free vascularized fibular grafting for reconstruction after tumor resection in the upper extremity. *J Surg Oncol.* Aug 1 2006;94(2):114-127.
17. Zaretski A, Amir A, Meller I, et al. Free fibula long bone reconstruction in orthopedic oncology: a surgical algorithm for reconstructive options. *Plast Reconstr Surg.* Jun 2004;113(7):1989-2000.
18. Eward WC, Kontogeorgakos V, Levin LS, Brigman BE. Free vascularized fibular graft reconstruction of large skeletal defects after tumor resection. *Clin Orthop Relat Res.* Feb 2010;468(2):590-598.
19. Sainsbury DC, Liu EH, Alvarez-Veronesi MC, et al. Long-term outcomes following lower extremity sarcoma resection and reconstruction with vascularized fibula flaps in children. *Plast Reconstr Surg.* Oct 2014;134(4):808-820.
20. Houdek MT, Bayne CO, Bishop AT, Shin AY. The outcome and complications of vascularized fibula grafts. *Bone Joint J.* 2017 Jan;99-B(1):134-138
21. Sorger JI, Hornicek FJ, Zavatta M, et al. Allograft fractures revisited. *Clin Orthop Relat Res.* Jan 2001(382):66-74.
22. Brigman BE, Hornicek FJ, Gebhardt MC, Mankin HJ. Allografts about the Knee in Young Patients with High-Grade Sarcoma. *Clin Orthop Relat Res.* Apr 2004(421):232-239.
23. Mankin HJ, Gebhardt MC, Jennings LC, Springfield DS, Tomford WW. Long-term results of allograft replacement in the management of bone tumors. *Clin Orthop Relat Res.* Mar 1996(324):86-97.
24. Deijkers RL, Bloem RM, Kroon HM, Van Lent JB, Brand R, Taminiau AH. Epidiaphyseal versus other intercalary allografts for tumors of the lower limb. *Clin Orthop Relat Res.* Oct 2005;439:151-160.
25. Muscolo DL, Ayerza MA, Aponte-Tinao L, Ranalletta M, Abalo E. Intercalary femur and tibia segmental allografts provide an acceptable alternative in reconstructing tumor resections. *Clin Orthop Relat Res.* Sep 2004(426):97-102.
26. Mankin HJ, Hornicek FJ, Raskin KA. Infection in massive bone allografts. *Clin Orthop Relat Res.* Mar 2005(432):210-216.

27. Bae DS, Waters PM, Gebhardt MC. Results of free vascularized fibula grafting for allograft nonunion after limb salvage surgery for malignant bone tumors. *J Pediatr Orthop*. Nov-Dec 2006;26(6):809-814.
28. Mastorakos DP, Disa JJ, Athanasian E, Boland P, Healey JH, Cordeiro PG. Soft-tissue flap coverage maximizes limb salvage after allograft bone extremity reconstruction. *Plast Reconstr Surg*. Apr 15 2002;109(5):1567-1573.
29. Campanacci DA, Puccini S, Caff G, et al. Vascularised fibular grafts as a salvage procedure in failed intercalary reconstructions after bone tumour resection of the femur. *Injury*. Feb 2014;45(2):399-404.
30. Friedrich JB, Moran SL, Bishop AT, Wood CM, Shin AY. Free vascularized fibular graft salvage of complications of long-bone allograft after tumor reconstruction. *J Bone Joint Surg Am*. Jan 2008;90(1):93-100.
31. Capanna R, Campanacci DA, Belot N, et al. A new reconstructive technique for intercalary defects of long bones: the association of massive allograft with vascularized fibular autograft. Long-term results and comparison with alternative techniques. *Orthop Clin North Am*. Jan 2007;38(1):51-60, vi.
32. Clemens MW, Chang EI, Selber JC, Lewis VO, Oates SD, Chang DW. Composite extremity and trunk reconstruction with vascularized fibula flap in postoncologic bone defects: a 10-year experience. *Plast Reconstr Surg*. 2012 Jan;129(1):170-8.
33. Manfrini M, Vanel D, De Paolis M, et al. Imaging of vascularized fibula autograft placed inside a massive allograft in reconstruction of lower limb bone tumors. *AJR Am J Roentgenol*. Apr 2004;182(4):963-970.
34. Chang DW, Weber KL. Use of a vascularized fibula bone flap and intercalary allograft for diaphyseal reconstruction after resection of primary extremity bone sarcomas. *Plast Reconstr Surg*. Dec 2005;116(7):1918-1925.
35. Innocenti M, Abed YY, Beltrami G, Delcroix L, Manfrini M, Capanna R. Biological reconstruction after resection of bone tumors of the proximal tibia using allograft shell and intramedullary free vascularized fibular graft: long-term results. *Microsurgery*. 2009;29(5):361-372.
36. Hunt T. Irradiation-Induced Hypoxia in Bones and Soft Tissues: An Experimental Study. *Plast Reconstr Surg*. 1986;77(2):266-267.
37. Vasileios KA, Eward WC, Brigman BE. Surgical treatment and prognosis in patients with high-grade soft tissue malignant fibrous histiocytoma of the extremities. *Arch Orthop Trauma Surg*. Jul 2012;132(7):955-961.

Reconstruction of a massive sacrectomy defect – technical tips

20

Kuokkanen Hannu¹, Kiiski Juha², Kääriäinen Minna², Kaartinen Ilkka², Pakarinen Toni-Karri², Laitinen Minna²,

¹ Helsinki University Hospital,

² Tampere University Hospital, Finland

Introduction

Primary sacral tumors requiring sacrectomies are rare and constitute less than 7 % of all spinal tumors [1]. Chordoma is the most common primary malignancy of the sacrum [2]. Total sacrectomy is a complex surgical procedure resulting in a large bone and soft tissue defect with spinopelvic discontinuity.

There is no consensus, whether a spinopelvic fixation should be used or how

the bony pelvic ring and soft tissue defect should be reconstructed after sacrectomy. In a systemic review only 116 reported patients with total sacrectomies were identified in high quality reports [2]. From 116 patients in 24 no spinopelvic fixation was performed and only 3 patients had had a vascular bone reconstruction of the pelvic ring. Local flaps were used for soft tissue reconstruction in 36 patients. They could not identify any patient with a free flap reconstruction of the soft tissues in this review.

Patients

Tampere University Hospital sarcoma center has performed 21 partial and 3 total sacrectomies (*Figure 1.*) between 2008-2017 for primary sacral tumors. The most common tumor indicating sacrectomy was a chordoma.

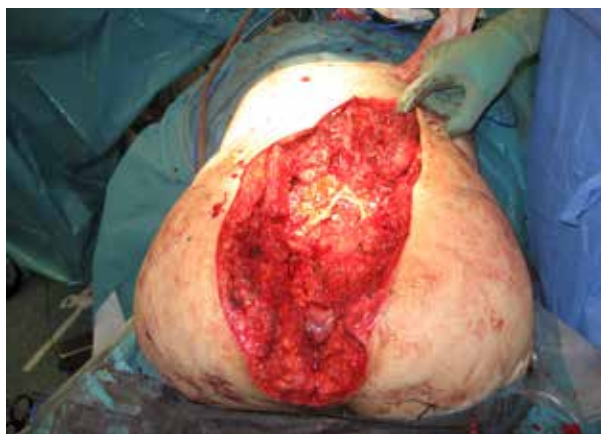

Figure 1: A 64-year old man with Chordoma of sacrum. The first stage operation was started with removal of rectum and an end-sigmoideostomia. The patient was transposed to a mekka-position and a total sacrectomy was performed. A spinopelvic fixation was performed and the wound was closed with drains.

A protective loop sigmoideostomy was performed in 7 patients in the beginning of the operation.

After sacrectomy a spinopelvic fixation was used in 5 patients (*Figure 2*). The bone reconstruction was performed with a free vascularized fibula in one and a free vascularized scapular rim chimeric flap in one patient. A nonvascular fibula autograft was used in four and a tibia allograft in one patient.

The soft tissue defects were reconstructed by a microvascular LD musculocutaneous flap in 3 and with a distant pedicled musculocutaneous flap in 3 patients. A gluteus maximus muscle advancement was used for soft tissue reconstruction in 7 and a fasciocutaneous flap in 4 patients. The wound was closed directly in 6 patients. To overcome

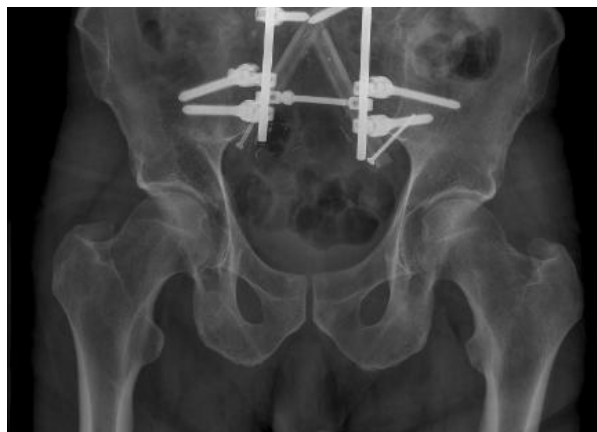

Figure 2: A planned second operation was performed one week later. A vascular fibula graft was harvested. An osteotomy was done to the middle of the fibula graft and it was fixed in a triangular form from the iliac bones to L5. The fibular vessels were anastomosed to superior gluteal artery and vein. The wound was closed directly with gluteal muscle advancement to fill the dead space. The patient is mobile and disease free with a 6-year follow up.

the problem of donor vessels a long saphenous vein arteriovenous loop was used in 3 patients. In order to keep the operation time and blood loss in reasonable levels the operation was staged in two session with one week interval in 5 patients.

Results

One flap was totally lost (VRAM) and replaced with a local gluteus maximus advancement later on. All microvascular flaps survived. A deep infection was registered in 7 patients. The spinopelvic fixation material had to be removed in 1 patient because of a persistent infection.

Conclusions

Sacrectomies are massive operations leading to a long operation time and a sub-

stantial peroperative blood loss. That is why the operations have to be planned in a multidisciplinary team with orthopaedic oncologists, abdominal-, spinal- and plastic surgeons. In our experience the reconstruction of the dead space with robust microvascular

flaps is worthwhile and reliable (4). If no local donor vessels are available for a free flap the use of a long saphenous vein a-v loop gives a source for donor vessels. A two stage policy can be favored in the biggest of the operations.

REFERENCES

1. Feldenzer JA, McGauley JL, McGillicuddy JE: Sacral and presacral tumors: problems in diagnosis and management. *Neurosurgery* 1989; 25, 884-887.
2. Reynolds et al. Soft tissue and bone defect management in total sacrectomy tumors: A systemic review with expert recommendations. *Spine* 2016; 15, 199-204.
3. Laitinen MK, Parry MC, Albergo JI, Umathi VS, Jeys LM, Grimer RJ: Resection of the ilium in patients with a sarcoma: should the pelvic ring be reconstructed? *Bone Joint J.* 2017 Apr;99-B(4):538-543.
4. Lopez et al. Primary flap reconstruction of tissue defects after sarcoma surgery enables curative treatment with acceptable functional results: a 7-year review. *BMC Surgery* 2015; 9,15:71.

Hepatic artery anastomosis: dealing with limited access and difficult orientation

21

Amitabha Lahiri

Department of Hand and Reconstructive Microsurgery
National University Hospital
Singapore

Microsurgeons are often called upon to assist hepatic artery anastomoses in paediatric liver transplants. There are certain challenges in the technique compared to anastomoses performed in the limbs.

These challenges (Figure 1)

1. The anastomosis is to be carried out in the abdominal cavity at a depth
 2. The space is constrained between the liver superiorly, the gut inferiorly, the rib cage towards the surgeon
 3. The hepatic artery is oriented in an oblique-vertical plane (*Figure 1, 2*).
 4. The orientation of vessels demands familiarity with the backhand technique
 5. Due to the above factors the sequence of suturing becomes extremely important.
- If the more convenient sutures are placed over the part of the circumference facing the surgeon, the remaining circumference becomes inaccessible to suturing.

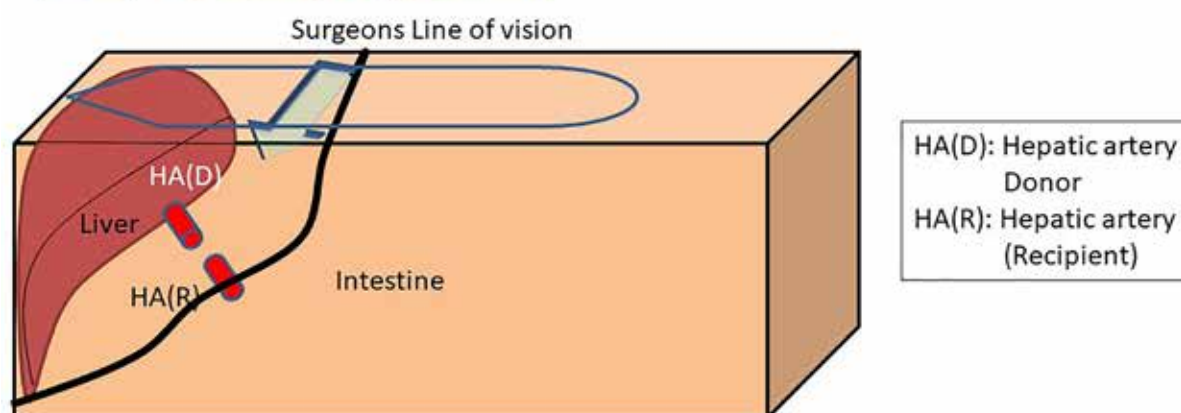
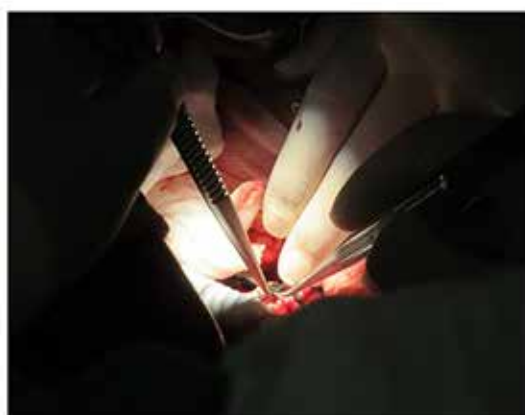
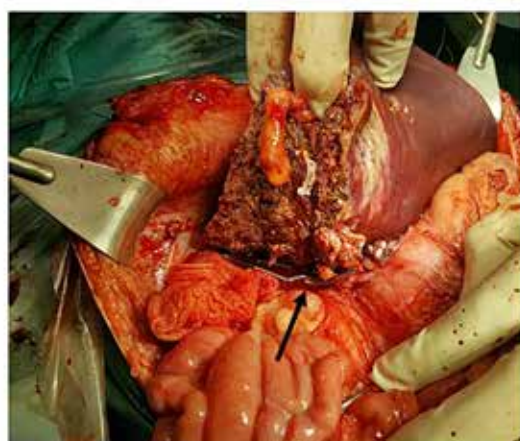
Figure 1: Top left: Donor liver and the location of the recipient artery (arrow)
 Top right: view of actual anastomosis
 Bottom: schematic representation of the location and orientation of the hepatic artery

Technical tips

The surgeon should stand on the right side of the patient and the table can be tilted towards the right side to facilitate access

The anastomosis can be carried out under a microscope or loupes of magnification between 3.5x to 4x.

Loupes are useful as they provide a greater flexibility for the surgeon in terms of positioning.

It is possible to request the anaesthetist to stop ventilation for durations of 1 to 2 minutes to minimise movement during suture placement

The assistant retracts the liver cranially, and the intestine caudally, to expose the vessels.

A large haemostat can be placed on the falciform ligament to assist in retraction of the liver.

Technique of suture placement: The technique described is for placement of interrupted sutures

Interrupted sutures are referred for small size vessels (1-2 mm diameter)

Vessel preparation

Separate bulldog clamps are placed on the donor and recipient segments. These provide much more flexibility for manipulating the vessel.

The ends are cut with sharp scissors. The overall length should be adjusted by excising

segments of the recipient vessel to avoid excessive redundancy which may lead to kinking following anastomosis.

Excision of adventitia should be kept to minimum, and the adventitia should not be excised beyond 1 to 2 mm from the vessel ends. Experience shows that the visceral arteries tear and tend to collapse after excision of adventitia. Maintaining the adventitia also prevents kinking of the vessel.

Normal (15cm) needle holders are used. Long instruments may be used as personal preference but the length may compromise

the control on the instrument. 8-0 Nylon or Polypropylene sutures can be used with taper-point needles. Cutting needles should not be used.

Suture Placement (Figure 2)

The far wall is the most challenging to access and should be sutured first. This technique is preferred over conventional 180 degree technique as the length of vessels is usually short, which precludes the pos-

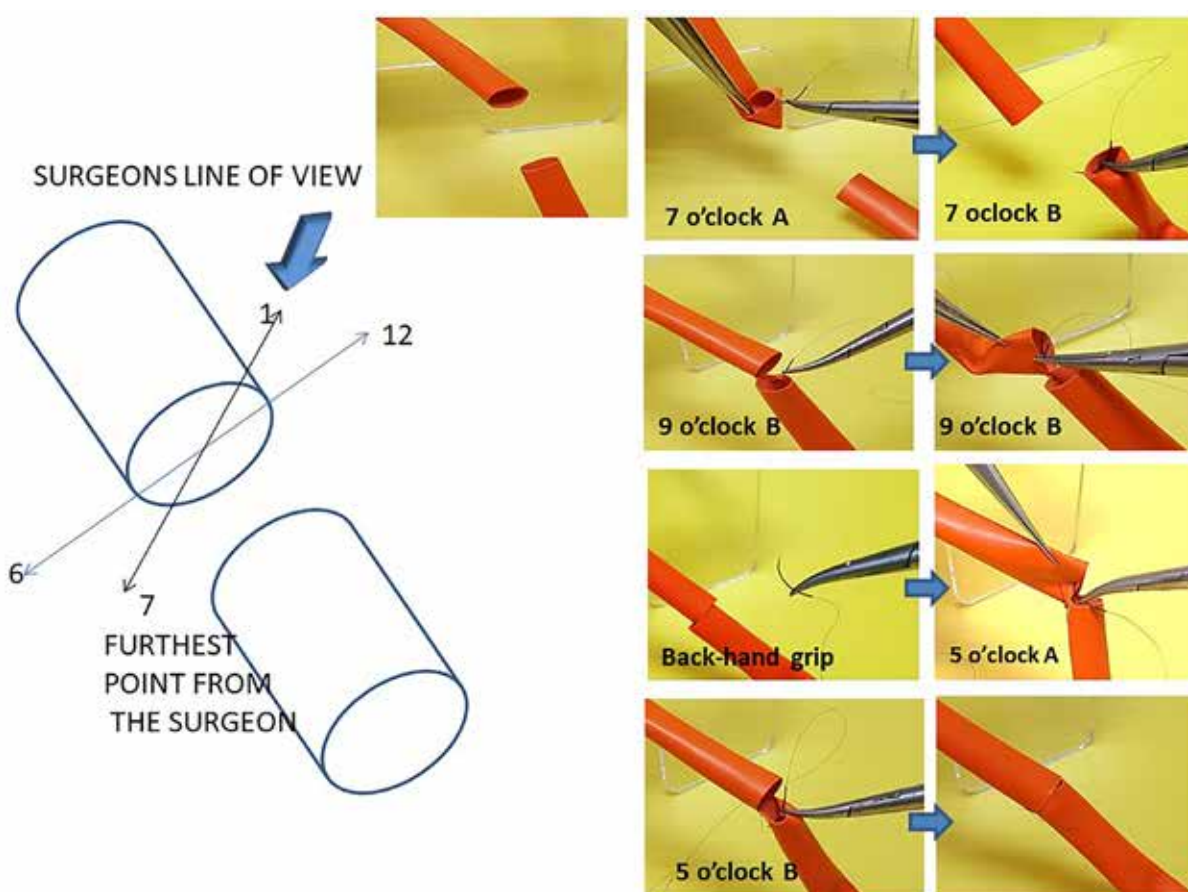


Figure 2: Left: The orientation of vessel and corresponding positions on the clock-face. 7 o'clock being the point diametrically opposite to the surgeon

Right: original position of the hepatic artery

7 o'clock: Fore-hand entry into the donor artery (A) and fore-hand entry into the recipient artery (B)

9 o'clock: Fore-hand entry to the recipient and back-hand entry into the donor artery

Back hand grip: achieved by rotating the needle holder

5 o'clock: back hand entry into the donor artery and forehand entry into the recipient artery

Completed far wall with near-wall remaining

sibility of twisting the vessel using double clamps.

The positions on the clock are used for description. Clinical judgement is necessary for deciding the space between the sutures such that there is no leak. A leak in the back-wall (far wall) is extremely difficult to handle once the anastomosis is complete.

For purpose of description, the circumference can be divided into the near-half and the far-half relative to the position of the surgeon. The near half is denoted by positions 5 o'clock to 12 o'clock and the far wall is denoted by positions 6 o'clock to 11 o'clock.

The first suture should be placed at the point diametrically opposite from the position of the surgeon (7 o'clock). The suture is placed using forehand technique through the back wall of the donor artery and entering the corresponding position in the recip-

ient artery in the inside-out direction.

This is followed by placement of the suture at the 9 o'clock position. The needle is passed through the recipient artery using forehand technique and the donor artery using backhand technique. The 11 o'clock suture is placed using the same technique.

The next suture is placed using a back hand technique at the 6 o'clock position, where the needle is passed through the donor artery first using the back hand technique and then the recipient artery in the inside-out fashion using the fore-hand technique. The 4 o'clock suture is placed using the same technique.

This completes the suturing of the circumference between the 4 o'clock and 10 o'clock position.

The remaining circumference (near wall) is completed using forehand technique.

Tips and tricks for microsurgical face and scalp reconstruction in elderly patients

22

Ozay Ozkaya MD, Ozlem Colak, MD

Okmeydani Training and Research Hospital, Istanbul

Malignant skin tumors constitute a remarkable group of head and neck cancers [1]. 70-80% of all basal cell carcinomas (BCCs) are located in head and neck region [2, 3], while 65% of all squamous cell carcinomas (SCCs) are located in head and neck region of patients with light colored skin [4]. Soft tissue defects after resection of advanced stage skin cancer located in facial region and SCALP usually need complex reconstruction options. These large tumors have bone involvements at base, and three dimensional

reconstruction options are usually needed. As the population gets older, number of patients presented with advanced stage head and neck skin malignancies increase as well. Free tissue transfers in elderly population can easily become a challenging issue for the reconstructive surgeon, where absolute indications for microsurgical reconstruction are present.

According to TNM staging system, T3 and T4 skin tumors have bone involvement at the base. These involved bone tissues

should be resected with tumor, and treatment should include three dimensional reconstruction options. Although the bone defects usually need no reconstruction in these circumstances; bone defects in the anterior wall of maxillary and frontal sinuses should be covered with stable and durable tissues, and mandibular bone defects should be bridged with bone tissue. Depending on these facts, gold standard for the treatment of defects after head and neck cancer resection is free tissue transfers [5]. Purpose of free tissue transfer is achieving a good quality of life for patients, with restoration of optimal form and function [6]. Preoperative planning should be based on location of the cancer and possible defect, evaluation of possible flap options and need for adjuvant therapies [7].

A reasonable and a multidimensional treatment option should be chosen to reconstruct these complex soft tissue defects. Having a 100% right treatment option is not always possible due to cosmetic and functional outcomes of surgery. Moreover, advanced age of patients and coexisting comorbidities may influence the surgical plan. Depending on these, treatment options are individualized and selected by some routinely accepted principles. The experiences on treatment for this patient group carry a high importance for increasing the cumulative knowledge, thus shaping the treatment principles. Besides, patient selection criteria for advanced staged malignant skin tumors of the head and neck region in elderly patients, pre-surgical assessment methods, the surgical and reconstructive approaches including neck dissections are crucial in evolution of decision-making strategies.

We evaluate the patients according to 7th edition of The American Joint Committee on

Cancer (AJCC) staging manual [8] for clinical TNM staging of cancers including Merkel cell carcinoma. Advanced stage tumors are defined as: Clinical stage III and IV, and patients with advanced stage skin cancer who are older than 60 years are categorized as elderly group. The dimensions of the tumor, involvement of the cosmetically important and vital organs and existence of palpable lymph node in the related drainage region are noted after admission. Radiologically, patients have computerized tomography (CT) scans of the whole head and neck region. Status of cervical lymph nodes are scanned with ultrasonography. Arterial and venous doppler ultrasonography are taken from external carotid artery, common carotid artery and jugular vessels bilaterally. Presence of carotid artery calcification are also checked with USG. Positron emission Tomography (PET) scan are taken preoperatively as well.

Surgical technique

Patients have intravenous antibiotic therapy for three days prior to surgery to prevent bacterial colonization in the tumors. Diabetic patients on oral anti-diabetic therapy are consulted to endocrinology department to switch their medications into intravenous insulin. Spirometric tests are conducted preoperatively to reveal pulmonary function and capacity. Compression stockings on bilateral lower limbs are dressed on the night before surgery, and intraoperative intermittent pneumatic compressions are applied in the lower limbs to prevent formation of deep venous thrombosis.

Surgical procedures are performed by two teams under general anesthesia. Tumors are resected with safe margins. Hyperemic zone

surrounding the tumors are accepted as a part of tumor, and safe margins are marked beginning from this surrounding hyperemic zone. Safe margins regarding to the tumor type are outlined in table 1. Total resection of tumors is proven by evaluation of multiple intraoperative frozen section analysis. Frozen section analysis includes samples taken from multiple points located in edges and base of skin defects after tumor resections.

Tumor Type	Safe Margins
BCC	1 centimeter
SCC	1 centimeter
MM	> 2 centimeters
MCC	2 centimeters

Table 1: Safe margins related to tumors. (Abbreviations. BCC: Basal cell carcinoma, MM: Malignant melanoma, MCC: Merkel cell carcinoma, SCC: Squamous cell carcinoma)

All patients with SCC, MCC, and MM have either modified radical neck dissection (MRND) or supraomohyoid neck dissection. A patient with BCC does not receive MRND or supraomohyoid neck dissection. Bilateral cervical lymph node dissections are performed for the patients with centrally located tumors. All cervical lymph node dissections are performed by plastic surgery team.

Hyperextension of the neck and extreme manipulations to cervical spine are avoided during neck dissections of the patients with carotid calcifications to prevent cerebrovascular thromboembolism. Superior thyroidal artery and branches of internal jugular vein are seen and preserved for anastomosis. Hemoclips are used in the branches of these vessels to control bleeding and bipolar cauterization is prevented to avoid heat damage. Superior thyroidal artery and internal jugular system are used as recipient vessels. We always perform one arterial and two venous anastomosis routinely and 5000 I.U. intravenous heparin is administered immediately after performing anastomosis.

The type of free flap is chosen for each patient individually. Shallow defects and soft tissue defects located in the delicate regions of the face are reconstructed with free radial forearm fasciocutaneous flaps (RFF). Defects with moderate need for coverage are reconstructed with free medial sural artery perforator flaps (MSAPF). Advanced tissue losses and cavities are reconstructed with free anterolateral thigh fasciocutaneous flaps (ALT), or free muscle flaps (*Figure 1*). The bone defects are reconstructed with free fibula flaps in combination with fasciocutaneous islands (*Figure 2*).

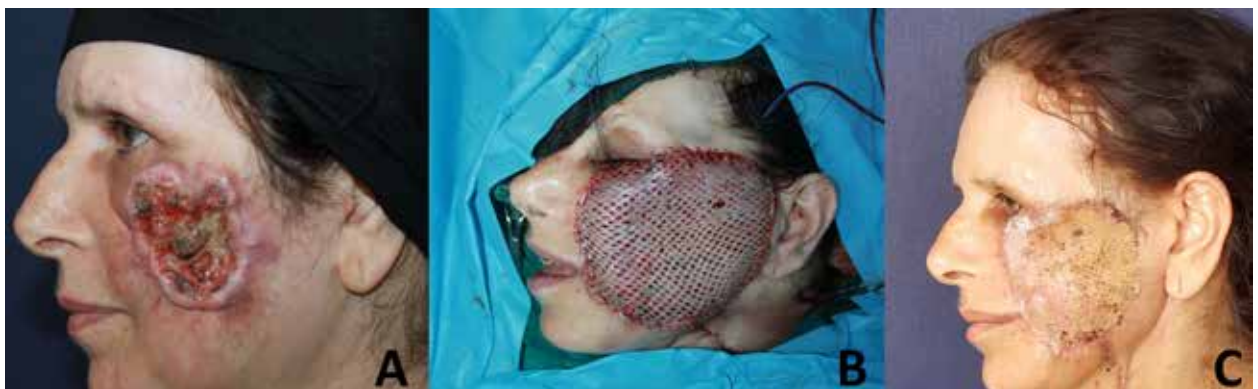

Figure 1: Advanced tissue losses and cavities cure reconstructed with free ALT

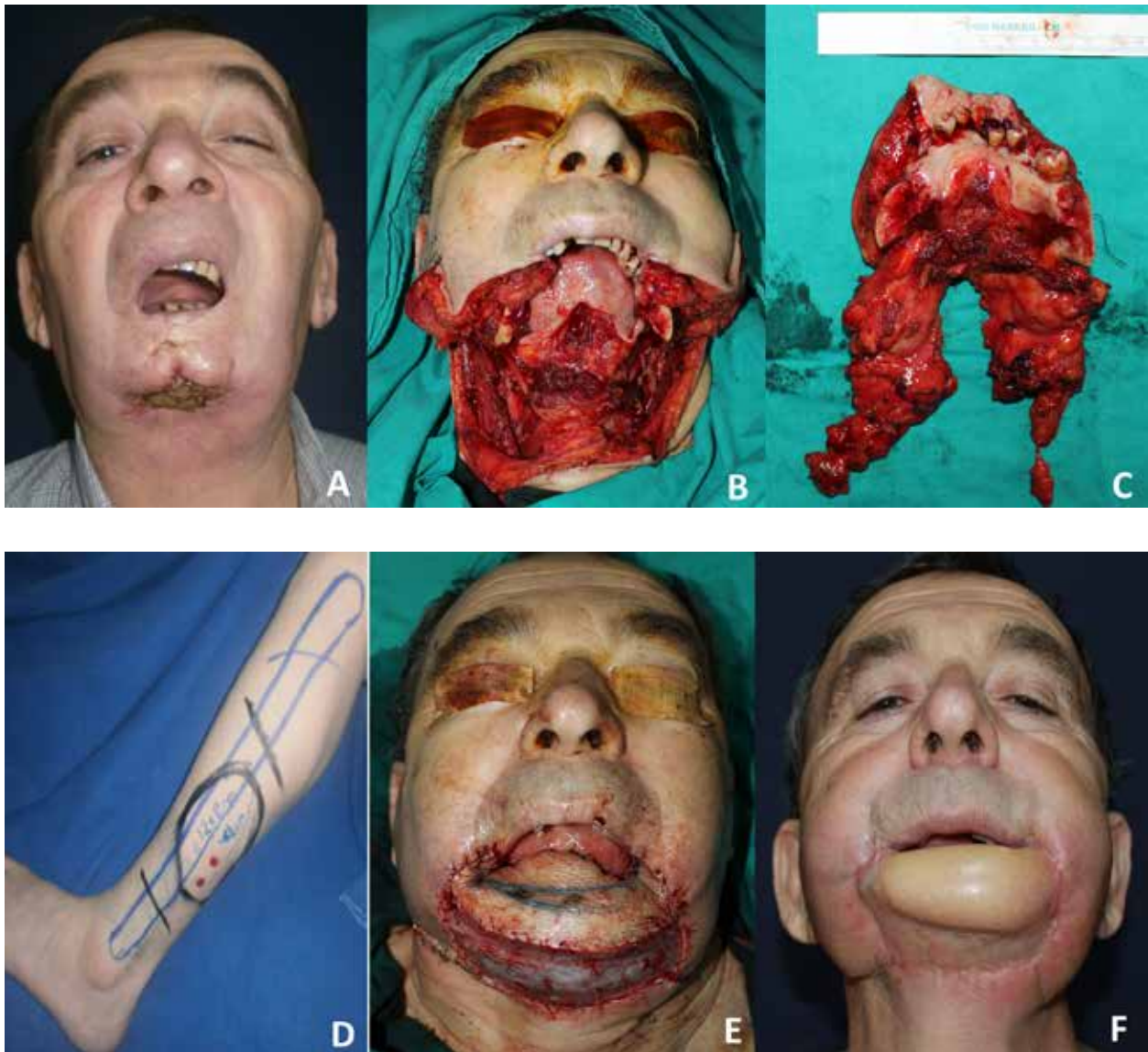

Figure 2: The bone defects are reconstructed with free ribulla flaps in combination with fasciocutaneous islands

No patients are extubated after the operation and followed in intensive care unit in the immediate postoperative 24 hours. Free flaps are controlled per hour in the first 72 hours with clinical assessment and handheld Doppler device. Anticoagulation regime included low molecular weight heparin which is used 6 hours after the operation and 300

mg acetyl salicylic acid peroral once a day after extubation.

Patients are discharged on postoperative day 14. Routine control visits are performed weekly in the first month, and monthly in the first year. Adjuvant therapies are carried out by medical oncology department after wound healing was finished.

REFERENCES

1. Kraft S, Granter SR. Molecular pathology of skin neoplasms of the head and neck. *Archives of pathology & laboratory medicine*. 2014;138(6):759-87.
2. Kopf AW. Computer analysis of 3531 basal-cell carcinomas of the skin. *The Journal of dermatology*. 1979;6(5):267-81.
3. Scrivener Y, Grosshans E, Cribier B. Variations of basal cell carcinomas according to gender, age, location and histopathological subtype. *The British journal of dermatology*. 2002;147(1):41-7.
4. Rigel DS, Cockerell CJ, Carucci J, Wharton J. Actinic keratosis, basal cell carcinoma and squamous cell carcinoma. In: Bologna JL, Jorizzo JL, Rapini RP, editors. *Dermatology*. 2nd ed. Maryland Heights, MO: Elsevier Mosby; 2008. p. 1641-60.
5. Sakuraba M, Miyamoto S, Kimata Y, Nakatsuka T, Harii K, Ebihara S, et al. Recent advances in reconstructive surgery: head and neck reconstruction. *International journal of clinical oncology*. 2013;18(4):561-5.
6. Al Deek NF, Wei FC, Kao HK. Free Tissue Transfer to Head and Neck: Lessons Learned from Unfavorable Results-Experience per Subsite. *Clinics in plastic surgery*. 2016;43(4):621-30.
7. Patel SA, Chang EI. Principles and practice of reconstructive surgery for head and neck cancer. *Surgical oncology clinics of North America*. 2015;24(3):473-89.
8. AJCC cancer staging manual. 7th ed. Edge SE, Byrd DR, Compton CC, editors. New York: Springer; 2010.

Vascularized Joint Transfer from the Foot

23

Paolo Sassu, MD, PhD

Hand Surgery Department, Sahlgrenska University Hospital

Indications

Vascularized joint transfer is indicated in young adults who have suffered from traumatic or non-traumatic loss of either the PIP or MCP joint and other conventional methods, such as arthrodesis or joint replacement, are not ideal.

Other applications are reserved to children where the reconstructed joint can benefit from the potential growth of the transfer.

Anatomy background

The PIP joint of the II and III toes has often a limited range of motion with lack of full extension and a maximal flexion of 90 degrees. The MCP joint has its greatest mobility in extension, and needs to be rotated 180 degrees for inset in the finger.

In the toe, the main vascular supply to both PIP and MCP joints comes from the plantar digital arteries which, at the neck of the metatarsal and first phalanx respectively,

give off a branch that reaches the joints. The plantar digital arteries are the end branch of the intermetatarsal arteries. [1]

The medial plantar artery and the dorsalis pedis artery give origin to a dorsal and plantar vascular system which are formed respectively by the first dorsal (FDMA) and plantar (FPMA) intermetatarsal arteries. These two systems are in communication proximally by the deep plantar artery and distally by the distal perforating branch. Many authors [2-6] have described the anatomical variations in size and course of the FDMA along the first intermetatarsal space. For surgical purposes, it is important to identify the FDMA and FPMA at the base of the great and II toe. In most cases the FDMA has a larger caliber and through a retrograde dissection [7] the vessel is followed dorsally for the necessary length. In a lesser number of cases the FPMA is dominant and the surgical dissection will continue plantarly. In case the third toe is selected for joint transfer, the arterial system comes from the second intermetatarsal space where the plantar system is usually dominant.

Surgical procedure¹

PIP joint transfer

Hand. A dorsal curved incision centered over the PIP joint is made on the injured finger.

A proximal dorsal vein at the MCP joint level is easily found and marked with a vessel loop. On the side, the dominant digital artery of the finger is isolated and marked with a vessel loop allowing easier identification after release of the tourniquet. The extensor tendon (EDC) is identified and inspected. As described by Lam et al. [8], different

situations can be present: 1) If the extensor mechanism is intact, the central slip is detached from its insertion leaving the lateral bands in continuity. The EDC will then be sutured to the long extensor from the toe. 2) If the EDC is disrupted and the lumbricals in poor conditions, the lateral bands might be centralized and the toe joint transferred underneath them with no reconstruction of the EDC. 3) If the EDC is in poor condition but the lumbricals still functional, the extension will depend on the toe long extensor and reinserted in the middle phalanx by either the Stack procedure or Te technique. [9]

The PIP joint is detached off the underlying flexor tendons and the bone prepared for proximal and distal osteotomy.

Foot. The left foot is more often chosen by the author in order to preserve the right side, more involved in driving. The choice though is made according to patient preference.

The patient is supine with the foot lying in a natural position at 90° from the bed and a tourniquet is applied at the thigh and inflated after raising the leg for one or two minutes. No Esmarch bandage should be used. Before having exsanguination of the limb, it is helpful to let the foot hang for a moment down off the bed in order to visualize the venous system and mark one or two veins of good caliber from the dorsum of the toe up to the greater saphenous vein. The surgeon sits alongside and draws a 'Z' shape incision centered over the PIP joint, which includes a rectangular skin flap used as monitor and allows easier closure of the recipient site. If inspection of the central slip is planned, the skin paddle is designed elliptical on the side of the joint. The drawing continues proximally in a zig zag fashion so as to trace the vascular and tendinous structures with adequate length.

Dissection begins isolating a dorsal cutaneous flap and one or two veins which are traced proximally, till reaching the necessary length. It is suggested to skeletonize these veins so that recipient side closure will not be disturbed by possible bulkiness from fat tissue.

The arterial system is visualized in the first intermetatarsal space as suggested by Wei [7] (*Figure 1*). If an artery of good caliber is found dorsally this is traced as proximal as needed in a retrograde fashion. The extensor

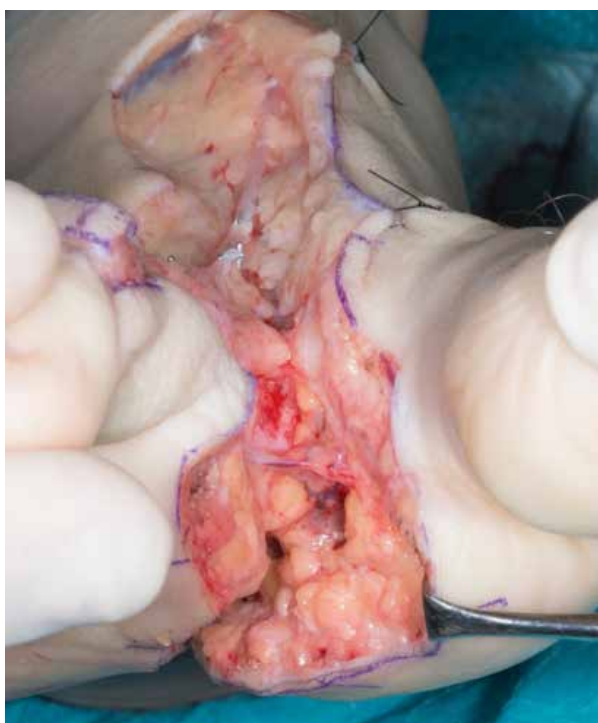

Figure 1: The arterial system is explored in the intermetatarsal space and either the dorsal or plantar artery is selected depending on the caliber of the vessels. In this case the dorsal system is inconsistent.

halluces brevis might be divided to allow better arterial exposure. If the dorsal system is insufficient then dissection must continue plantarly where the artery has a larger caliber. In case a long pedicle is needed, a vein graft should be harvested in order to avoid extensive dissection plantarly in the foot.

It is important to preserve the tibial digi-

tal artery intact to provide optimal blood supply to the tip of the toe. The pulley system is then opened plantarly and the flexor tendons preserved so that proximal and distal osteotomies can follow. The toe lies now only on the artery and vein and the tourniquet is released to assess vascular supply (*Figure 2*).

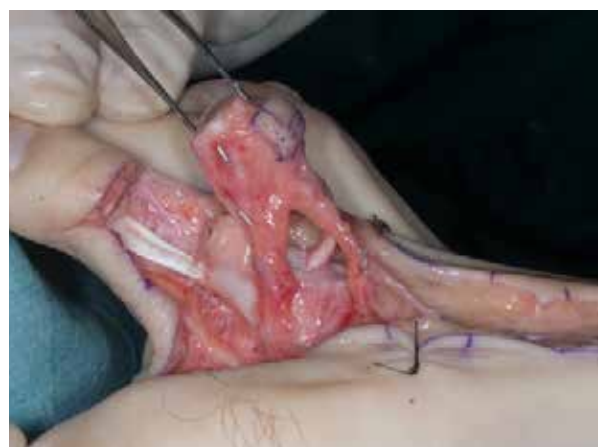

Figure 2: The PIP joint is now isolated. We can see a dorsal vein, the plantar course of the artery, and the extensor tendon.

Inset. Once appropriate length of the graft is assessed, preliminary proximal and distal osteosynthesis is performed with one 1.0mm Kirschner wire in order to evaluate proper axis of the finger in flexion and extension as well as range of motion. If adequate position is confirmed two parallel 0.6mm cerclage together with one oblique Kirschner wire are used for final fixation. The K wire can be cut tangent to the cortical bone. Miniplates can also be used but fixation takes longer and they are technically more demanding.

The extensor tendon is sutured side-to-side according to Friden [10], allowing early start of active mobilization. Vein anastomosis is performed dorsally and the artery is either tunneled volarly in the palm or sutured on the side at the base of the first phalanx. Gentle skin suture with no tension and a bulky soft dressing ends the inset.

In the foot, the finger PIP ankylotic joint is transferred to the toe and osteosynthesis is performed with K wires. A bulky dressing and high heel orthotic shoe is applied so that the patient can walk soon, few days after surgery.

Bone healing takes at least 6-8 weeks in both donor and recipient site.

MTP joint transfer¹

The surgical dissection of the MTP joint is in all similar to the PIP joint. Few details will be mentioned in this description related to the surgical approach and inset.

An elliptical skin paddle slightly on the side of the joint is first dissected. Since the joint needs to be rotated 180° when transferred to the hand, this design will make it easier when adjusting the skin paddle in the recipient side. One or two veins of good caliber are identified and traced proximally. The arterial system is assessed in the first web space and either the dorsal or plantar artery is dissected proximally depending on the dominant system. The arterial supply to the MTP joint raises off at the neck of the metatarsal bone. For the less experienced surgeon, it might be wise to include part of the interosseous muscle together with the artery in order to avoid inadvertent devascularization of the joint. The flexor tendons are freed and left intact. Proximal and distal osteotomies can now be undertaken leaving the joint attached only on the artery and vein. Vascular supply is assessed for twenty minutes before the joint is transferred. The non-functional joint from the finger can be trans-

ferred to the foot, but its rigidity might be symptomatic in the foot making amputation of the whole toe a better choice. This needs to be discussed with the patient preoperatively.

Expected outcomes

As reported in the review by Squitieri [11], PIP joint transfer provides usually a total arc of motion of 37 +/- 9 degree; MCP joint transfer can reach a total range of motion of 35+/-10 degrees.

Mohan et al. [12] have proposed, in case of PIP j-toe stiffness with lack of flexion, proximalization of the proximal phalanx. The authors suggest to shorten the proximal phalanx so that the distance between the fingertip and the palm improves. Shortening of the finger must be discussed with the patient.

Tips and tricks

Skeletonization of the dorsal veins reduces bulkiness and makes final closure in the finger easier.

Extensive dissection of the medial surface of the foot while following the vein should be avoided for the risk of skin necrosis.

Hsu et al. [13] showed that slight shortening of the toe first phalanx improves range of motion of the transferred joint.

Inspection of the extensor mechanism in the recipient and donor site might reduce extension lag.

REFERENCES

1. Lin CH, Sassu P. Toe flaps and toe transplantation. In: Wei FC, Mardini S, eds. *Flaps and Reconstructive Surgery*. 1st ed. Philadelphia: Saunders; 2009:473e500.
2. Murakami T. On the position and course of the deep plantar arteries, with special reference to the so-called plantar metatarsal arteries. *Okajimas Folia Anat Jpn*. 1971 Dec;48(5):295-322.
3. Gilbert A. Composite tissue transfers from the foot: Anatomic basis and surgical technique. In: Daniller A, Strauch B, eds. *Symposium on Microsurgery*. St Louis, Mo: Mosby, 1976.
4. May JW Jr, Chait LA, Cohen BE, O'Brien BM. Free neurovascular flap from the first web of the foot in hand reconstruction. *J Hand Surg Am*. 1977 Sep;2(5):387-93
5. Leung PC, Wong WL. The vessels of the first metatarsal web space: An operative and radiographic study. *J Bone Joint Surg Am*. 1983;65:235-238
6. Zhidian Hou, M.D, Jiyao Zou, M.D, Zengtao Wang, M.D, Shizhen Zhong, M.D. Anatomical Classification of the First Dorsal Metatarsal Artery and Its Clinical Application. *Plast Reconstr Surg*. 2013 Dec;132(6):1028e-39e
7. Wei FC, Silverman RT, Hsu WM. Retrograde dissection of the vascular pedicle in toe harvest. *Plast Reconstr Surg*. 1995;96:1211-1214
8. Lam WL, Waughlock N, Hsu CC, Lin YT, Wei FC. Improving the extensor lag and range of motion following free vascularized joint transfer to the proximal interphalangeal joint: Part 2. A clinical series. *Plast Reconstr Surg*. 2013 Aug;132(2):271e-280e
9. Loh CY, Hsu CC, Lin CH, Chen SH, Lien SH, Lin CH, Wei FC, Lin YT. Customizing Extensor Reconstruction in Vascularized Toe Joint Transfers to Finger Proximal Interphalangeal Joints: A Strategic Approach for Correcting Extensor Lag. *Plast Reconstr Surg*. 2017 Apr;139(4):915-922.
10. Fridén J, Tirrell TF, Bhole S, Lieber RL. *J Hand Surg Eur Vol*. 2015 Mar;40(3):239-45. The mechanical strength of side-to-side tendon repair with mismatched tendon size and shape. *J Hand Surg Eur Vol*. 2015 Mar;40(3):239-45.
11. Squitieri L, Chung KC. A systematic review of outcomes and complications of vascularized toe joint transfer, silicone arthroplasty, and PyroCarbon arthroplasty for posttraumatic joint reconstruction of the finger. *Plast Reconstr Surg*. 2008 May;121(5):1697-707
12. Mohan R, Wong VW, Higgins JP, Katz RD. Proximalization of the Vascularized Toe Joint in Finger Proximal Interphalangeal Joint Reconstruction: A Technique to Derive Optimal Flexion From a Joint With Expected Limited Motion. *J Hand Surg Am*. 2017 Feb;42(2):e125-e132.
13. Hsu CC, Loh CY, Kao D, Moran SL, Lin YT. The impact of transferred vascularized toe joint length on motion arc of reconstructed finger proximal interphalangeal joints: a cadaveric study. *J Hand Surg Eur Vol*. 2017 Oct;42(8):789-793

Technical tricks in upper limb classical nerves grafting according to lesion level and functional prioritization

24

Teodor Stamate

Professor Emeritus

Head of the Department of Plastic Surgery and Reconstructive Microsurgery
University of Medicine "Gr.T.Popa" IASI, Romania

Nerve defects repair using autografts remains to this day the gold standard treatment despite other alternatives [36,11]. In defects greater than 2-3 cm, grafting is the treatment of choice [34]. Upper limb nerve graft technique using cutaneous nerves (CN) segments has to respect certain principles in regard to nerve trunk exploration, and the surgeon has to choose the donor nerve and modality of harvest (total or partial, Govila-James approach) and to adapt nerve continuity reconstruction to the lesion type (com-

plete section, partial or lesion in continuity – “inlay” graft) [48]. On the other hand, microsurgical reconstruction technique by cutaneous nerve graft interposition between nerve defect ends differs by lesion level, as follows: for proximal lesions – sectorial grafting, as well as for polyfascicular trunks (without internal fascicular groups – FG - arrangement), and in distal lesions – FG – CN – FG type grafting. Available donor nerves are limited by number and length, and this is why available nerve segments must respect,

especially in large defects, the principle of functional prioritizing (Jabaley and Koman-Steiberg principle).

Nerve grafting technique implies three aspects:

- a) Exploring the nervous trunk
- b) Graft harvesting
- c) Nerve continuity reconstruction

a) Exploring nerve ends

External neurolysis permits – in secondary reconstructions – releasing of the nervous trunk from scar tissue and sectioned nerve ends mobilization.

Sectioned nerve ends handling is done by guide threads placed on nerve trunk ends and passed strictly through the epineurium, proximal and distal. The distance at which they are placed must always be greater than 2 cm from the section area, at the limit between normal epineurium and the thicker scarred epineurium. Close examination of epineurium vessels proximal and distal from lesion, as well as mesoneurium position are sufficient landmarks for correcting the rotation of sectioned nerve ends [47].

It is universally accepted that in peripheral nerve lesions the best results are obtained through direct neurorrhaphy. This is the reason why after proximal nevrroma and distal glioma resection, direct repair is to be tempted – especially in limit cases with a 3 cm “gap dilemma” [13] if nerve ends approximation is possible. If two 8-0 nylon epineurial stitches separated at 180 degrees cannot hold the cut nerve ends together with ease, an interposition nerve graft should be performed [28].

Nerve exploring must lead to:

- Correct positioning of nerve ends without

malrotation by extensive dissection until the emergence of important branches;

- Real nerve defect dimension appreciation maintaining the joints in extension or in maximum nerve stretch position [17];
- Evaluating receptor bed vascularisation for adding a nerve graft length permitting a deviated path from the normal nerve path, avoiding scar tissue.

Nerve ends exploring is finalised with microsurgical analysis of the structure and intratronicular nerve organisation for establishing correspondence between fascicular cartogram of proximal and distal ends (*Figure 1*).

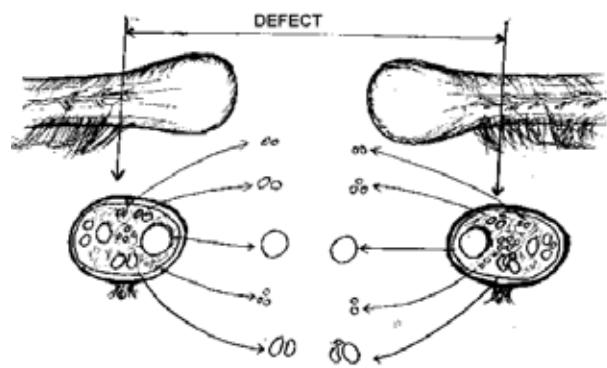


Figure 1: Establishing nerve endings cartograms of the grafted nerve

“Mirror” microsurgical analysis of the section surfaces after neuroma resection is essential for choosing the reconstruction technique [41,47].

b) Graft harvesting

Considering ideal nerve graft characteristics, the surgeon has to choose the donor nerve that best fits the clinical situation. The graft has to be long enough to cover the nerve defect in which we add an excess of length of ~20% [48] to permit a curvilinear disposition between nerve ends when adja-

Nerve	Length (cm)	Number of fascicles			Interfascicular conjoint tissue	Approach
		proximal	medial	distal		
Sural	14-35	1-4 medium	2-11 medium	2-10 medium	Reduced, compact fascicles	+++
Superficial radial	12-20	2-6 big	3-12 big	2-11 medium	Reduced, fascicles more restrained than sural	++++
Internal cutaneous of the arm	8-14	2-10 medium	3-7 medium	6-8 medium	mediu	+
Internal cutaneous of the forearm	18-20	2-7 medium	3-8 medium	4-12 medium	mediu	++
External cutaneous of the forearm	7-12	2-7 medium	2-6 medium	3-9 small	mediu	++
Femoral cutaneous	7-8	2-5 medium	2-7 medium	2-9 small	crescut	+
Posterior thigh	6-7	4-8 medii	4-11 medium	3-10 small	abundent	+

Table 1: Cutaneous nerve graft selection criteria

cent joints are in extension, to avoid tension suture [17] and facilitate revascularisation. Sunderland and Ray studied all the CN that can be used as grafts (*Table 1*).

Sural nerve and radial sensitive nerve offer the best qualities similar to the ideal nerve graft [28]. Their superiority consists in:

- Great lengths with no branching
- Are the richest in neural tissue
- Constant anatomy
- Minor donor zone morbidity

Sural nerve graft is the preferred choice by the majority of authors [48]. Graft harvesting has to be simple, easy to be done and as atraumatic as possible, although Koller (1995) explains that stripping doesn't affect graft structure [19]. The sural nerve complex usually consists of three components: the medial sural cutaneous nerve, the peroneal communicating branch and the "proper" sural nerve. The approach is done by placing a series of short 2-3 cm incisions on nerve projection and harvesting by stripping [42].

Sural complex harvest is undertaken either in full length when long grafts are needed – with local morbidity assumption [31, 38] – or by proximal component harvest – MSN and ESAN when graft length need is lower [32]. The disadvantages of using autografts consist in potential donor site morbidity – anaesthesia or nevroma, cold intolerance (33%) or allodynia (50%) – [12] and limited disponibility [35, 36, 48] and additionally prolonged operative time [28].

Sural nerves represent the longest available graft and must be principally preserved for grafting long brachial plexus defects or in big nerve trunks. The use of a sural nerve is to be condemned for grafting small digital nerve defects for which better donor nerves can be harvested from the vicinity [8], or by rational use of sural nerve, according to the Govila-James principle. [12] This principle consists of microsurgical proportional harvesting of a sufficient amount of fascicular groups from the sural nerve (*Figure 2*) for grafting a collateral digital nerve defect. By

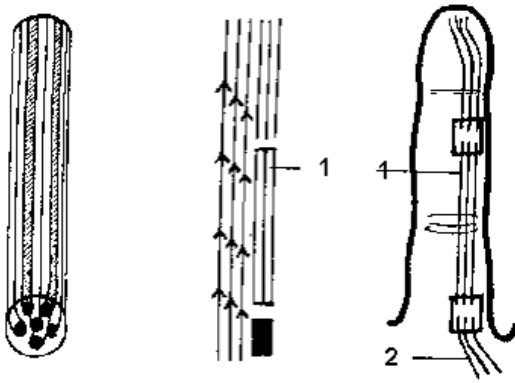


Figure 2: Rational graft harvesting for collateral digital nerve. 1. Sural nerve graft fascicles; 2. Collateral digital nerve

proceeding in this way donor zone morbidity is avoided [10].

When the entire nerve complex is harvested using sural nerve grafts has the disadvantage of losing leg and lateral foot sensibility, leading to discomfort - pain, allodynia - and even neuroma [12] or trophic ulcers on the dorsal surface of the fifth finger [32, 38]. This is the reason why Govila and James (1989) propose a proportional harvesting technique through which a small graft requirement (for digital nerves) should be covered by harvesting of just 3 from 6 fascicles isolated by internal neurolysis in the sural nerve (*Figure 2*) [10].

This technique is based on the assumption that partial traumatic sectioning of a sensitive nerve does not lead to a detectable sensibility loss, probably due to interfascicular anastomosis and collateral reinnervation [5].

c) Repairing nerve continuity

Repairing nerve continuity comprises multiple elements which can be presented in a sequential way:

C.1 - graft preparing:

- segment length approximation
- segment ends trimming

C.2 - fascicular identification

C.3 - graft segments orientation and positioning

C.4 - graft segments suturing to nerve ends

C.1 - Graft preparing

Graft length segment appreciation is achieved by bearing in mind that the graft has to be longer than the nerve defect when joints are in extension [26]. This will help to compensate scar retraction, avoiding suture tension [17] and segment contact, by arranging a suitable length of graft between the nerve ends which will permit early movement without graft tensioning. As mentioned, graft segments that will re-establish central nerve fascicles continuity will be 5-10% longer than the nerve defect (for retraction means); graft segments that will reconnect the nerve trunk circumferentially will be 20% longer [48] than the actual defect, permitting nerve trajectory changes with preserving the architecture (*Figure 3*).

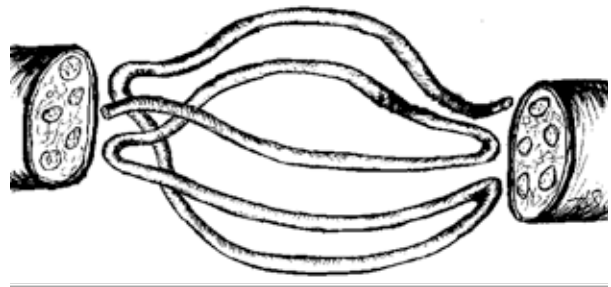


Figure 3: Projecting the length of the graft by arranging the entire graft between nerve ends

The CN segment number must take into account the surface of the grafted nerve [8, 41], the defect length and the fascicular cartography by lesion level [42]. Accordingly, for the ulnar nerve, motor fascicles can be easily recognised by deep positioning and di-

ameter, and can be isolated for one or two CN graft segments [2]. The surgeon should consider the functional importance of reconstruction [37] and therefore the approach has to be as for two nerves, sensitive and motor, regarding the ulnar nerve in the 3rd distal of the forearm [16].

The number of CN graft segments depends on how the nerve trunk is organised [27]. Frequently there is a FG organisation with diameters comparable with those of the graft. Millesi (1988) recommends 5-6 segments of CN for the median nerve and 4-5 segments for the ulnar nerve [25]. At each segment of CN we mark the proximal edge of the graft in such a manner that we can inverse it to be placed in the defect [7, 41, 48].

C.2 – Fascicular identification

The intraoperative electrostimulation method for identifying the fascicular motor is used nowadays with good results throughout the world [15, 18, 45].

Correspondent fascicular identification between proximal and distal nerve graft ends requires a careful analysis at 16x and 25x magnification of the cartograms, defining the vascular extra and intratronicular network and exact mapping of the biggest fascicles [21, 47].

C.3 – Orientation and placement of graft segments

Placing the nerve grafts of different lengths between grafted nerve ends depends on the particular vascular status of the receptor bed. There are two sources of free grafts revascularisation: from the nerve ends and from the receptor bed. In 3 weeks an anastomotic system between the extrin-

sic epineural arteries system from the graft and the receptor bed evolves. The outcome of this process is key to determining the viability of the graft which depends on receptor bed vascularisation [25]. In the case of a receptor bed being scarred, in the absence of improvement by tissue transfer (local or distant flaps), the graft placement should be detoured on a trajectory that avoids bad vascularisation regions. Even if the graft is 2-3 cm longer, it is important to be placed in a well vascularised tissue which will ensure viability [44, 49].

CN segments must also be in contact with the entire circumference of the receptor nerve [27]. If the graft bed is well vascularised, the graft length does not influence the result [1, 25, 39], the regenerating axon has the genetic information for continuing growth until reaching the target organ [21]. It is considered that grafts longer than 7 – 10 cm can be correlated with poor results [48]. To avoid scar tissue in the grafting of the radial arm nerve, Bertelli and Ghizoni proceed with proximal and distal nerve ends transposition and subcutaneous bypass of sural nerve graft segments [1].

If by simple detouring of the nerve grafts a good vascularised bed is not found, then muscular flaps, synovial and adipofascial flaps can be considered (Strickland, Becker) and distant flaps can be used in particular situations. [22] The surgeon must avoid placing segments of CN at equal lengths in the defects forming a cable or a nerve trunk which is too thick, that poses the risk of not vascularising the central fascicles, even if the bed is of good quality [14]. Recent case reports showed that vascularised nerve grafts did not improve the results as expected, despite efforts and difficulties of harvesting the nerve grafts and last years published

cases showed that this type of graft included microsurgical transferred flaps [4, 50]. Graft positioning is mandatory. Each segment of CN graft is placed in an inversed position, with the proximal end of the graft towards the distal end of the grafted nerve [7, 48].

C.4 – Graft segment suture to nerve ends

By CN segment coaptation technique there are two different microsurgical techniques: 1.) sectorial grafting useful for high lesions, at a polyfascicular nerve trunk without FG organization; 2.) FG-CN-FG type grafting indicated for nerves with FG organisation. Regarding the grafting type, CN segments are coaptated to the nerve ends by 9-0 10-0 microsutures, which remains a standard technique [14], or using fibrin adhesive (tissue coll) applied only at nerve ends [7, 38, 44, 48, 50].

C.4.1 – sectorial grafting

The difficulty of correspondent fascicle identification between proximal and distal ends in polyfascicular nerves without FG organization, led to the idea of sectorial coaptation of grafts between nerve ends [25]. Although, the great numbers of fascicles change their aspect and position on small distances, with numerous anastomosis between them in the proximal portion (plexiform structures), from a practical point of view what is important is that they still respect functional sectorial topographical organisation on long distances [16]. This is why in polyfascicular nerves without FG organisation, CN coaptation on correspondent quarters on the nerve section between proximal and distal ends remains the best solution (*Figure 4*).

Approximating the first graft segment at the proximal nerve which is to be repaired

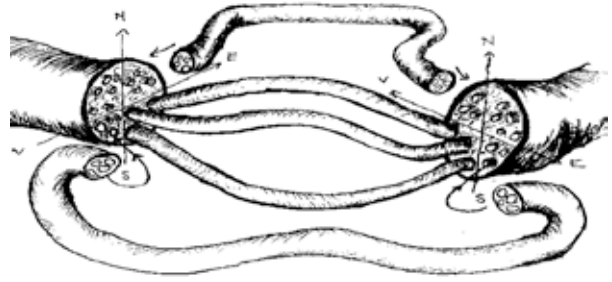


Figure 4: Graft arrangement in sectorial type of graft

will be with the biggest FG, clearly represented, both in proximal and distal or with the most important functional sector [47].

On the other hand, even in selecting the segments of CN, the surgeon must choose the most convenient grafts for a more precise coaptation of the FG or of the important fascicles, keeping the thinnest of the CN segments for reconstructing the continuity of FG from the sectors less functionally important.

In sectorial grafting, sutures are different for CN central segments than for those places at the periphery of each sector.

The central suture which reunites 3-4 segments of graft coming in direct contact will first be passed through epineurium of the CN segment, then through interfascicular conjoint tissue of the nerve and finally through the epineurium of the CN segment (*Figure 5*). Tightening of the suture has to

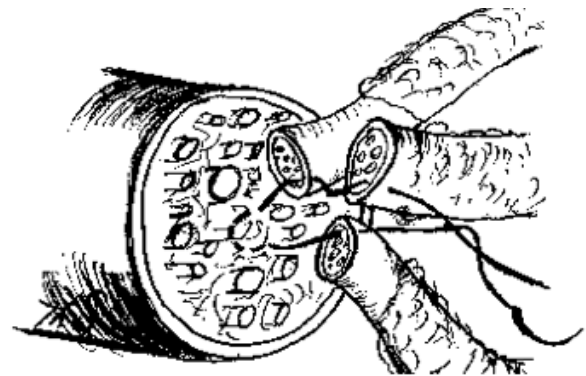

Figure 5: Central “U” suture

be done with the maximum of attention to avoid the telescoping of fascicles contained in the graft. The 9.0 will be tightened with a certain degree of laxity just at the contact between the fascicles of the graft and those of the nerve to be grafted.

For segments of CN which are used to graft the peripheral circumferential fascicles, the suture points should support the contour epineurium of the nerve trunk and then through the graft epineurium. Where two nerve grafts come in contact, the suture will be placed in a “U” shape reuniting the epineurium of the two CN segments (*Figure 6*).

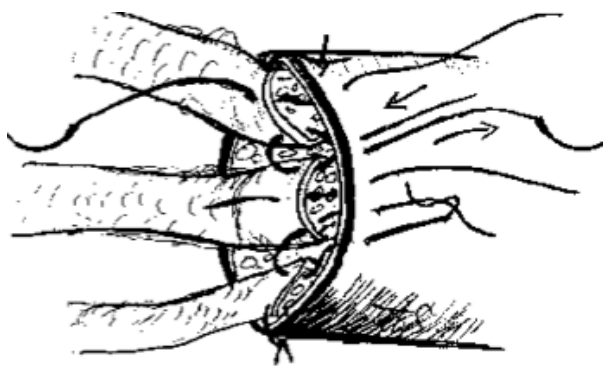


Figure 6: “U” stitch for circumferential grafts

This modality of suturing in sectorial grafting reduces the quantity of foreign material on the suture line [43].

The surgeon must respect a certain correspondence between fascicle dimension in the sector of the grafted nerve and the diameter of the fascicles contained in the graft. For the principal functional sector CN grafts with the biggest fascicular reception surface must correspond to that from the grafted nerve, even being a little bigger.

C.4.2 – FG-CN-FG type grafting

Depending on the diameter of each FG in the CN graft segment, 2 to a maximum of 4

points of suture are placed using 9.0 or 10.0 thread [23]. The needle is passed through the internal epineurium of the FG at 25x magnification and then through the contour epineurium of the CN. Atraumatic manipulation of the FG and CN is mandatory. The surgeon has to make a compromise regarding maximum precision and minimum trauma.

When the nerve trunk to be grafted has a FG organisation, the FG diameter should correspond to that of the CN [31] and the CN has to be placed between proximal FG and its distal correspondent. After coaptation of the most functionally important FG, proximally with a graft segment of adequate diameter, the microsurgical span should be moved to the distal CN graft suture and to the correspondent distal end of the nerve to be repaired. Careful examination of the correspondent FG, guided by extra and intratranocular vessels, internal topography notions and the relation with the neighbouring FG or fascicles resembling those on the proximal cartogram [24], should be undertaken. The suture technique is similar to that of FG neurorrhaphy. Tightening of the suture must be tension free and even show laxity if there is a contact between fascicles of the graft and the grafted nerve [47] and a correct alignment should be insured [43].

Proceeding in this manner, grafting a polyfascicular nerve trunk with FG organisation at which the diameter of each FG corresponds to that of a segment of CN utilised (*Figure 7*), we will code this repair FG – CN – FG, and for 3 FG and 3 CN coding will be 3(FG – CN – FG). If the receptor nerve has 4 or 5 FG and for each one segment of CN used, the coding of this repair is 4(FG – CN – FG) or 5(FG – CN – FG).

FG – 2CN – FG type nerve graft. There are clinical situations in which a FG diameter on




Figure 7: Grafting type FG-CN-FG

the end nerve cartogram is bigger than the diameter of the CN.

In these situations repairing the continuity of a big FG 2 or 3 segments of CN can be used, interposed between correspondent proximal and distal FG. When 2 CN segments are enough for grafting a big FG (*Figure 8*) coding is FG – 2CN – FG, and in the case of 3 segments, the coding is FG – 3CN – FG.




Figure 8: Grafting type (FG-3CN-FG) + (FG-2CN-FG) + (FG-CN-FG)

In the case of nerve grafts, one fundamental principle states that the number of endoneurial tubes (ENT) from the graft should be bigger than those from the nerve graft FG to reduce axonal loss at suture line [2, 8, 21, 24, 25]. The most frequently used grafts of CN are placed between corresponding FG, either FG- CN -FG, or FG – 2(3) CN – FG.

C.4.3 – “Inlay” type fascicular grafting

For lesions in continuity in which internal neurolysis associated with intraoperative

fascicular electrostimulation [8, 15, 18] require partial resection of the dysfunctional fascicles, the defect is grafted with segments of CN of approximately the same length as that of the defect, making a call for thin grafts (*Figure 9*).

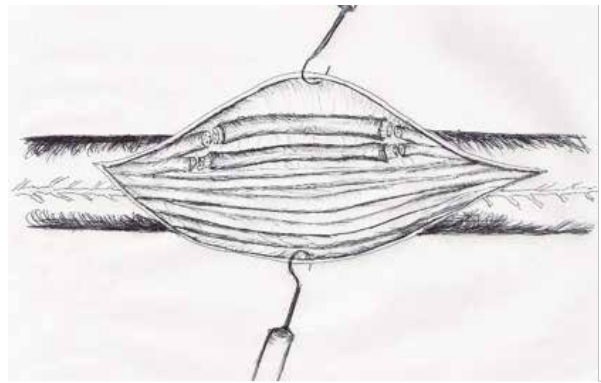


Figure 9: “Inlay” graft for in continuity lesions

In certain cases this type of grafting named “inlay”, specific for in continuity lesions, is the only situation in which the true interfascicular technique proposed by Millesi (1974) has a clear indication [21]. “Inlay” fascicular graft remains a useful tool for the surgeon as an alternative to the “omega” suture applied in emergency. “Inlay” graft is indicated in old in continuity lesions, with lateral neuroma, when fibrosis compromise the gliding [24] and the “omega” suture isn’t possible anymore. In the case of in continuity lesions situated at the periphery of a nerve trunk it is possible that an entire FG is functionally interrupted, a situation which

determines the surgeon to excise the FG after a limited internal neurolysis and repairs the continuity with an “inlay” graft of FG – CN – FG type [43].

Choosing the grafting technique depending on the lesion level

a) High lesions

In high lesions an intratrocular dissection for grafting type FG – CN – FG is not justified due to the multiple interfascicular anastomoses and the functional mosaic diffuse pattern, all these implying rather a sectorial type reconstruction [16]. The best way to address this issue is to divide each section area into functional quarters, guided by epineural vessel network of the nervous trunk associated with motor dominant sectors identified by electrostimulation [15, 16, 24, 45]. Graft segments will reconnect corresponding quarters by the sectorial grafting technique [23]. The method is applied for brachial plexus lesions, for big defects, but also for peripheral trunks without FG organisation.

b) Distal lesions

As nerve trunks approach their destination, FG separation becomes more visible [21]. Fascicular group organisation is well individualised in distal peripheral nerve lesions, and this can help to establish the correspondence between FG of the affected nerve to be grafted [23, 38]. Finding the emergence of pure motor or sensitive branches can be achieved by prolonging dissection towards proximal and intratrocular following of the branches by internal neurolysis from the apparent origin to the real origin which is always

5-7 cm proximal [16]. In distal lesions, autograft usage offers the best results [51] despite other alternatives, such as nerve transfers, biological conduits [7, 40].

The radial nerve separates in FG at two levels: at the arm in the radial groove and at the elbow level. In the radial groove, ~10-20% of its diameter is occupied by sensitive fascicles for the posterior side of the forearm. Then it gives the first branch for the long portion of the triceps muscle which has around 4 motor fascicles, 3 other fascicles arise, followed by lateral cutaneous sensitive nerve organised in 7 fascicles and branches with only 2 fascicles for brachioradialis, extensor carpi radialis longus and triceps [2]. In the radial groove the majority of radial nerve lesions are repaired through grafting [33] and in over 50% of cases in the other 3 regions [20]. The radial nerve finishes in the first portion of the forearm in two terminal branches: posterior interosseous nerve and radial sensitive nerve. Separation of these two branches begin in the nerve trunk, at 7-9 cm proximal to the elbow [16], the sensitive FG being in the lateral quadrant. It divides 2 cm distal to the elbow into a superficial sensory branch and a deep motor branch, the posterior interosseous nerve [42].

At the level of the lateral epicondyle at about 1-4 cm distal, the radial nerve divides into a sensitive and motor branch. The fullness of conjoint tissue in the structure of the radial nerve at the elbow reaches around 79% [2], and this makes it easier to separate the sensitive FG and therefore avoiding wrong coaptation with a motor FG. For shortening the length of grafts and to avoid placing on a scar tissue bed, Bertelli and Ghizoni proceed with subcutaneous transposition of radial nerve ends at arm level [1]. The graft passage by tunnelisation avoids incisions and possible scar entrapment [48]. Subcutaneous tunneling

of long grafts is used in brachial plexus surgery with a bypass over retroclavicular scar tissue [39, 44, 46]. Radial nerve lesions are divided in 4 regions (infraclavicular, shoulder, arm, lateral antebrachial groove and direct on posterior interosseous nerve), distal lesions offering a better outcome [33].

For the median nerve it is not indicated to be separated in FG even at wrist level [25]. Still, for the correct grafting of a median nerve defect in the 3rd distal region of the forearm, dissection can be extended towards the palm to follow the thenar branch and to determine its proximal position inside the nerve trunk [7, 35]. Previous studies have shown that isolating the motor FG (thenar branch) can be done from 3 to 7 cm proximal to the radial styloid [16, 42].

Certainly the median nerve in the 3rd proximal region of the forearm, needs to be approached by FG because at this point it branches into the anterior interosseous nerve, which lies and branches on the origin of the superficial flexors for 2-5 fingers and the profound flexors for 2-3 fingers. Individualising the fascicles for anterior interosseous nerve starts at approximately 6 cm above the elbow [16] and target motor grafting is recommended [35, 42, 43].

For the ulnar nerve, the importance of the motor branch as well as the isolation of this branch in the 2nd and 3rd distal regions of the forearm justifies internal neurolysis of the nerve ends, the ulnar nerve being approached as two separate nerves, a motor one (the most important from the functional view) and the second sensitive one [16]. From a surgical point of view it is important to account that the motor FGs are located inside the cubital nerve trunk at 7,5-10 cm proximal from its apparent origin. This aspect is very important because separation through neurolysis of the mo-

tor FG for a distance of 7-10 cm proximal earns some extra length. Serial histologic analysis at every 5 mm showed a precise correspondence for the motor FG which is kept from the distal 3rd of the forearm to the deep branch at the wrist [42].

At wrist level and in Guyon's canal, the cubital nerve can be separated into FG. At this level the motor component holds a dorso-ulnar position and it is clearly separated from the sensitive component. This is one of the most distinct separations between the motor and sensitive components, which permit a separate surgical treatment in primary and secondary repair. To avoid motor and sensitive mismatch, Jabaley (1991) recommended treating ulnar nerve lesions at the wrist and 3rd distal region of the forearm as two separate nerves, a sensitive one and a motor one (Jabaley principle). For lesions located above the emergence of the dorsal sensitive branch we must take into account that this branch is found as a separate FG for 17-20 cm proximal to its apparent origin inside the nerve trunk. This separation as a latero-ulnar FG reduces the risk of mismatching sensitive and motor branches found inside the trunk. It is considered as a separate sensitive nerve which contains ~ 24 fascicles that follow a common trajectory with the ulnar nerve [2]. This detail also helps in cases in which we can use the dorsal cutaneous sensitive branch as a nerve graft [16]. Judging of this manner, median and ulnar nerve lesions at the 3rd distal and median regions of the forearm should include distal dissection towards the division of branches [8, 27, 42].

Prioritising functional nerve grafts

The function of the nerve to be grafted is a key factor for the manner in which the

surgeon will distribute the cutaneous nerve graft segments that are of limited length. Using the principle of functional prioritisation, the surgeon must use the best resources for reconstructing the FG which has the main role in functionality in the repaired nerve [14]. Proceeding like so, the CN segment that contained the biggest FG, without emergent branches on the selected length will be used for repairing the FG that are most important for the grafted nerve. According to the principle that the graft ENT surface must surpass the FG of the repaired nerve [8], usage of two segments of CN prioritise the ideal repair of FG with the most important function.

For nerves of the upper limb, functional prioritisation is very simple: the radial nerve is a principally a motor nerve and the sensitive branch can be ignored (sometimes it is used as a nerve graft); the ulnar nerve is mainly a motor nerve (the most important motor nerve of the hand) and the sensitive function is secondary; the median nerve is predominantly sensitive (the most important sensitive nerve of the hand) and less important as the motor nerve [43].

For the ulnar nerve, motor recovery is essential [38]. Microsurgical approach for lesions of the ulnar nerve in the 3rd distal region of the forearm for treating the two nerves, the motor and the sensitive ones (Jabaley principle) supports the idea of prioritising the motor FG. Intraoperative motor FG identification by electrostimulation is common practice [9, 46]. Grafting will commence with the biggest and deepest FG – the motor one – and will be done with one CN segment containing the biggest FG, mono or oligofascicular that surpasses the surface of the motor FG [8]. The graft technique coded FG – CN – FG or FG – 2(3) CN

– FG. For the sensitive FG one or maximum of two segments of CN graft length should be used. These principles of functional prioritisation were applied at a presented case of secondary reconstruction after chainsaw complex trauma, with a 7 cm defect of the ulnar nerve trunk in the 2nd and 3rd distal region of the forearm. Sural nerve graft distribution used 3 segments, prioritising repair of motor FG with 2 segments and one segment of graft (the thinnest) for sensitive FG (Figure 10).

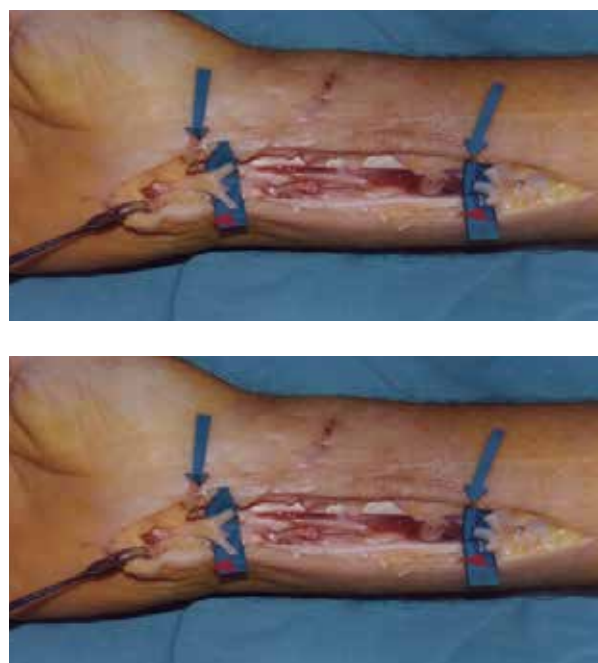


Figure 10: 1. Ulnar Nerve a) 7 cm defect; Jabaley principle treatment for 2 nerves: motor + sensitive ; b) nerves grafts: 2 grafts FG's Motor and 1 graft sensitive FG

Associating electrostimulation with a good knowledge of layered cartogram sections with identification of the priority FG permits the surgeon to apply the principle of functional prioritisation in nerve graft repair. For the median nerve it is more important to repair the sensitive function rather than the motor one and the latter should be repaired with a palliative surgery. In consequence, the sensitive FG will be repaired

Nerve	No.segments Graft Available	No. Segments Graft for Sensory FG	No. Segments Graft for Motor FG
Median Nerve segments grafts 4		3	1
Ulnar Nerve segments grafts 3		1	2
Radial Nerve segments grafts 4		1	3
segments grafts 3		0	3

Table 2: Graft segments distribution

with 2-3 segments of CN grafts and the motor FG (identified by electrostimulation) only requires one segment of CN graft- the principle of Koman-Steiberg. Median nerve prioritisation grafting for sensitive FG at the 3rd distal region of the forearm offers the best results [7]. Segments containing the thinnest FG will repair the less important function of the grafted nerve. Knowledge of intrafascicular topography combined with intraoperative identification permits the surgeon to distinguish the motor FG and sensitive FG and achieve better results (42).

For the radial nerve, the sensitive fascicles are identified by distal dissection and

separated from the nerve trunk by internal neurolysis. At ~ 7-9 cm proximal from the elbow, the sensitive branch (real origin) forms one FG that can be easily separated.

Emergence of the sensitive branch (apparent origin) at 1-4 cm from the lateral epicondyle makes isolation of the branch easier and facilitated posterior interosseous nerve prioritisation in the 3rd superior region of the forearm.

Proceeding like so, according to the functional prioritisation principle, as applied in a case with a 5 cm defect on the radial nerve trunk at the 3rd distal region of the arm (after a fracture-dislocation of the humeral palette with comminution), we used 4 segments of sural nerve graft: 3 segments for prioritisation of the posterior interosseous nerve and one for the sensitive branch. (*Figure 11*)

Distribution of CN segment grafts used for large defect repairs of the upper limb can be resumed in *Table 2*. Take into account that for the sensitive branch of the radial nerve we even suggest that no repair should be carried out if the graft segments are insufficient.

Microsurgical nerve repair has to give priority to the restoration of the fascicular groups (FG) which have the most important function. This can be achieved by internal

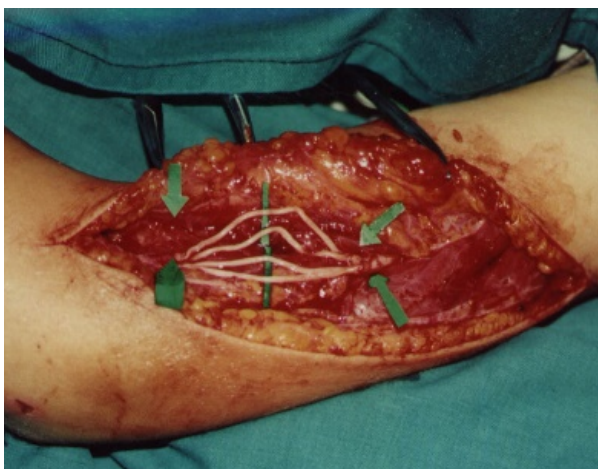


Figure 11: 2. Radial nerve 5 cm defect: 3 grafts for posterior interosseous nerve; 1 graft for sensitive radial branch.

neurolysis of the main FG and by their individual repair. For the nerve grafting, the most important fascicles are repaired first, with the best grafts and in sufficient number. For the median nerve, the main function is sensitivity, whilst for the ulnar and radial nerves the motor function is more important.

We applied this principle in 235 of the nerve repairs in the upper limb: 79 median and 153 ulnar nerves in the distal forearm and for 31 radial nerves in the distal forearm and at the elbow crease, with improved results compared to the standard techniques.

Sural nerve autografts can be used for upper limb and other techniques such as staged

reconstruction (the first stage is “nerve graft banking” and the second stage occurs one year later when a free functional muscle is transferred and coapted to this banked nerve graft to restore function) (28); neuro-neuronal neurotisations intra and extraplexal (9, 29, 30, 39, 44, 46), long nerve grafts to bypass the large area of scar tissue for brachial plexus injuries (46) or neuro-muscular (promoted by Georgio Brunelli) (3, 43, 44), the nerve bypass vascularised graft procedure (4, 50), nerve transfers (14) for end-to-side nerve supercharge or babysitter (28) or free flap reinnervation (6). All of these methods are possible options in lesions repair, but are out of scope of the current paper.

REFERENCES

1. Bertelli A.J., Ghizoni M.F. Results of nerve grafting in radial nerve injuries occurring proximal to the humerus, including those within the posterior cord. *J Neurosurg* 124:179-185, 2016
2. Bonnel F., Foucher G., Saint-Andre J.M. "Structure histologique du nerf cubital" in "Nerfs peripheriques - anatomie et pathologie chirurgicale" s. Bonnel F., Mansat M. Masson. Paris. 1990. 144-155
3. Brunelli G.A., Brunelli G.R. "Direct muscle neurotization" *J.Reconstr.Microsurg.* 9:2. 81-90. 1993
4. Casal D., Diogo Pais D., Mota-Silva E., Pelliccia G., Iria I., Videira A.P., Mendes M.M., Goyri-O'Neill J., Mouzinho M.M. Reconstruction of a long defect of the ulnar artery and nerve with an arterialized neurovenous free flap in a teenager: A case report and literature review. *Microsurgery*, 2017, 1-9; DOI: 10.1002/micr.30265
5. Dellon, A.L. Sensibility testing in "Operative nerve repair and reconstruction". red. Gelberman R.H. J.B. Lippincott Company. Philadelphia. 135-148, 1991.
6. Doi K. Management of Total Paralysis of the Brachial Plexus by the Double Free-muscle Transfer Technique. *J Hand Surg Eur Vol*, 33 no. 3 ; 240-251; 2008.
7. Fox K. I., Mackinnon, E.S. Adult Peripheral Nerve Disorders—Nerve Entrapment, Repair, Transfer and Brachial Plexus Disorders. *Plast Reconstr Surg*. 2011 May ; 127(5)
8. Gilbert, A., De Moura, W., Salazar, R. "Prelevement des greffes nerveuses" in "Traite de chirurgie de la main. vol. III" s. red Tubiana, R. Masson. Paris. 451-458. 1986
9. Goubier JN, Teboul F, Khalifa H. Reanimation of elbow extension with intercostal nerves transfers in total brachial plexus palsies. *Microsurgery*. Jan;31(1):7-11; 2011.
10. Govila, A., James, J.H. "Nerve apportionement in microneural surgery" *Brit.J.Plast.Surg.* 42. 570-572. 1989
11. Grinsell D., Keating C. P. Peripheral Nerve Reconstruction after Injury: A Review of Clinical and Experimental Therapies. *BioMed Research International*, Volume 2014, ID 698256, 13 pages <http://dx.doi.org/10.1155/2014/698256>
12. Hallgren Al., Björkman A., Chemnitz A., Dahlin B.L. Subjective outcome related to donor site morbidity after sural nerve graft harvesting: a survey in 41 patients. *BMC Surgery* 2013, 13:39
13. Hentz, V.R., Rosen, J.M., Xiao, S.J., McGill, K.C., Abraham, G. "The nerve gap dilemma: a comparison of nerve repaired end to end under tension with nerve grafts in a primate model" *J.Hand Surg.* 18.3: 417-425. 1993
14. Houschyar K. S., Momeni A., Pyles M. N., Cha J. Y., Maan Z. N., Duscher D., Jew O. S., Siemers F., van Schoonhoven J. The Role of Current Techniques and Concepts in Peripheral Nerve Repair. *Plastic Surgery International*, 2016; ID 4175293, 8 pages <http://dx.doi.org/10.1155/2016/4175293>
15. Jabaley ME: Electrical nerve stimulation in the awake patient. *Bull Hosp Jt Dis Orthop Inst* 44:248-259, 1984.
16. Jabaley, M.E. Internal topography of peripheral nerves related to repair. in "Operative nerve repair and reconstruction". (pp 241-258) s. red. Gelberman R.H. J.B. Lippincott Company. Philadelphia, 1991.
17. Kalomiri DE, Soucacos PN, Beris AE. Nerve grafting in peripheral nerve microsurgery of the upper extremity. *Microsurgery* 1994;15(7):506-511.
18. Kline, D.G. "Surgical repair of peripheral nerve injury" *Muscle-Nerve* 13.9: 843-852. 1990

19. Koller, R., Frey, M., Rab, M., Deutinger, M., Freilinger, G. "Wich changes occur in nerve grafts harvested with a nerve stripper? Morphological studies" *Handchirurgie Mikrochirurgie, Plastische Chirurgie* 27.2: 98-101. 1995
20. Li J, Hu H, Wang H, Cheng X. The effective analysis of microsurgical repair of radial nerve deep branch injury. *Zhongguo Xiu Fu Chong Jian Wai Ke Za Zhi*. 2012 Nov; 26(11):1344-7
21. Lundborg, G. "Nerve injury and repair". Churchill Livingstone. Edinburgh London Melbourne. 1988
22. Merle, M. "Lesioni nervosi" în "La mano traumatica. l'emergenza", (pp 235-258) s.red. Merle, M., Dautel, G., Vaianti, L. Ed. Masson. Paris.Milano, 1993.
23. Michon, J., Merle, M. "Techniques de reparation des nerfs peripheriques" în "Nerfs peripheriques - Anatomie et pathologie chirurgicale" s.red. Bonnel, F, Mansat, M. Ed. Masson, Paris.Milan.Barcelone. 1990.
24. Millesi H. Bridging defects: autologous nerve grafts. *Acta Neurochir Suppl*. 2007; 100():37-8.
25. Millesi, H. "Fascicular nerve repair" în "Textbook of microsurgery" red. Brunelli, G. Masson Paris. 613-615. 1988
26. Millesi, H. "The problem of two sites of coaptation in nerve grafting and the defect -distance relation" în "Posttraumatic peripheral nerve regeneration: experimental basis and clinical implications". red. Gorio, A., Millesi, H., Mingrino, S., Raven Press, New York. 1981
27. Millesi, H. "Reparations nerveuses secondaires: les greffes" în "Traite de chirurgie de la main" (pp 434-450) s.red. Tubiana, R., Ed. Masson. Paris. 1991.
28. Moore AM, Wagner IJ, Fox IK. Principles of nerve repair in complex wounds of the upper extremity. *Semin Plast Surg* 2015;29(1):40-7.
29. Narakas, A. "Les neurotisations ou transferts nerveux dans les lesions du plexus brachial" *Ann.Chir. Main* 1.2: 101-118. 1982
30. Narakas, A. "Thoughts on neurotisation or nerve transfers in irreparable nerve lessions" - *Clin.Plast.Surg.* 11. 1. 1984
31. Nunley, J. "Donor nerves for grafting" (pp 545-570.) in "Operative nerve repair and reconstruction". s. red. Gelberman R.H. J.B. Lippincott Company. Philadelphia 1991.
32. Ortiguella, M.E., Wood, M.B., Cahil, D.R. "Anatomy of the sural nerve complex". *J. Hand Surg.* 12A. 1119-1123. 1987
33. Pan CH, Chuang DC, Rodriguez-Lorenzo A. Outcomes of nerve reconstruction for radial nerve injuries based on the level of injury in 244 operative cases. *J Hand Surg Eur Vol* 2010; 35(5):385-91.
34. Panagopoulos N.G., Megaloikonomos D.P., Mavrogenis F.A. The Present and Future for Peripheral Nerve Regeneration. *Orthopedics*. 2017;40(1):e141-e156
35. Pederson WC. Median nerve injury and repair. *J Hand Surg Am* 2014;39(6):1216-22.
36. Ray WZ, Mackinnon SE. Management of nerve gaps: autografts, allografts, nerve transfers, and end-to-side neurorrhaphy. *Exp Neurol*. 2010 May; 223(1):77-85.
37. Revol, M., Servant, J.M. "Paralysies de la main et du membre superieur". *Medsi. Paris*. 1989
38. Ribaka S., Ferreira da Silva Filhoa R.P., Tietzmann A., Hirataa H.H., Augusto de Mattosa C., Machado da Gamaa S.A. Use of superficial peroneal nerve graft for treating peripheral nerve injuries. *Rev Brasileira de Ortopedia*, 2016; 51(1):63-69.
39. Sakellariou I.V., Badilas K.N., Stavropoulos A.N., Mazis G., Helias Kotoulas K.H., Kyriakopoulos S., Tagkalegkas I., Sofianos P.I. Treatment Options for Brachial Plexus Injuries *ISRN Orthopedics*, Volume 2014 , Article ID 314137, 10 pages.
40. Schonauer F, Marlino S, Avvedimento S, Molea G. Peripheral Nerve Reconstruction with Autologous Grafts. In *Basic Principles of Peripheral Nerve Disorders*. Edited by Dr. Seyed Mansoor Rayegani, ISBN 978-953-51-0407-0; Published online 28, March, 2012.
41. Seddon H.J. Nerve grafting. *J Bone Joint Surg Br*. 1963, Aug; 45():447-61.
42. Slutsky J. D. A Practical Approach to Nerve Grafting in the Upper Extremity . *Atlas Hand Clin* 10 ; 2005: 73-92.
43. Stamate T. "Microchirurgia reconstrucivă a nervilor periferici", Ed. Tehnopress. ISBN 973-98277-2-1. Iași., 1998
44. Stamate T., Budurca A.R., Lazar A.N., Tamas C., Stamate M.. Results in brachial plexus palsy after biceps neuro-muscular neurotisation associated with neuro-neural neurotisation and teno-muscular transfer. *Acta Neurochir. [Suppl]*, 93:127-131; 2005.
45. Teboul F., Goubier J.N. Le plexus brachial et ses traumatismes. Création du site - 23/05/2008. <http://www.plexusbrachial.com>
46. Terzis J. K., Vekris M. D., Soucacos, P. N. Outcomes of Brachial Plexus Reconstruction in 204 Patients with Devastating Paralysis. *Plastic and Reconstructive Surgery*. 1999, 104(5):1221-1240
47. Terzis, J.K., Smith, K.L. "Repair and grafting of the peripheral nerve". în "Plastic surgery. Vol. I", s.red. McCarthy, G.C. W.B. Saunders Company. Philadelphia. 630-697. 1990
48. Trehan K.S., Model Z., Lee K.S. Nerve Repair and Nerve Grafting. *Hand Clin* 2016; 32: 119-125.
49. Trumble TE: Physiology of peripheral nerve graft incorporation. *J Hand Surg Am* 19:420-427, 1994
50. Usami S., Tanaka K., Ohkubo A., Okazaki M. Vascularized Nerve Bypass A Case Report of an Additional Treatment for Poor Sensory Recovery. *Plast Reconstr Surg Glob Open* 2016;4:e686; doi: 10.1097/GOX.0000000000000673
51. Whitlock EL, Tuffaha SH, Luciano JP, et al. Processed allografts and type I collagen conduits for repair of peripheral nerve gaps. *Muscle Nerve*. 2009; 39:787-799.

Tips in management of tongue and floor of mouth cancer

25

Spiros Stavrianos

Greek Anticancer Institute

This is the commonest cancer of the oral cavity. In a tertiary center we come across enlarged tumours infiltrating the base of the tongue and FOM musculature and the bony mandible. However, the true base of tongue and oropharyngeal tumours are of different biology and metastatic potential.

Wide surgical resection remains the key-stone therapy followed by planned postoperative radiotherapy.

We usually perform modified radical Neck dissection type 2 that preserves SAN

and IJV while preparing the ECS with the superior thyroid, lingual or facial arteries for microvascular anastomoses and the IJV for venous anastomoses.

Of outmost importance is cleaning the lymph node IIb level sending multiple frozen sections with a very low threshold to convert it to radical Neck dissection if necessary. However, this is not the case most of times.

Access to the oral cavity via all time classic lip split parasymphiseal mandibulotomy

preserving contralateral floor musculature. Resection of the part of tongue involved with a generous 2-3 mm margin and if previous radiotherapy given 5 mm margin of healthy tongue.

Hemiglossectomy is the most common operation performed but care is paid to preserve even a small strip of intact tongue if still vascularized to act as a motor to the reconstruction transplant.

FOM musculature and especially genio-glossus and mylohyoid muscles are generously removed en block with the specimen taking care to remove all lymphatic tissue together with the primary. If necessary a strip of periosteum is taken for frozen sections and special care is exercised to the edentulous mandible if previous radiotherapy has been given. Previous bone scans are of importance in terms of mandibular resections. Lateral resections are the most commonly used and not always necessary to reconstruct.

The key point to address is if the tumor goes beyond the circumvallate papillae in tongue V region. In that case the minimum operation is hemiglossectomy or 2/3 glossectomy or near total glossectomy combined with a modified horizontal laryngectomy that is removal of the thyroid cartilage and the epiglottis along with the hyoid apparatus that is hyoid bone with sternohyoid and geniohyoid muscles. It is evident that support has to be provided to the larynx and adequate reconstruction to prevent aspiration pneumonias.

The most common and robust reconstruction used is anterolateral thigh free flap ALT not to forget the radial forearm flap

RFF reconstruction used some time ago.

ALT flap is providing bulk and good skin quality together with a long pedicle to manipulate as necessary even to contralateral neck vessels.

RFF can combine skin qualities with a small piece of bone if necessary.

A good tip is to suture the skin transplant tight to the tongue remnant since this is to contract after surgery thus avoiding the bunched up appearance which is bad reconstruction.

Of utmost importance is to reconstruct in 3D dimensions thus create a neotongue and then separately the FOM and the lateral pharyngeal wall. Failure to do so is creating a tongue tethering which is most debilitating. There is no need to reconstruct the pharyngeal pillars.

If there is too much of the flap before closing, the mandible deepithelialize the skin and cover the big vessels thus reinforcing your closure.

Most of the times, use the IJV since it acts as a pump for the drainage of the flap. If necessary, we perform two venous anastomoses ensuring the flap drainage safely.

Secure the drains with rapid absorbable sutures above the clavicle and onto the trapezoid muscle and always wake up the patient few hours later in the ICU with a tracheostomy and peg gastrostomy in place.

All been well, the patient returns to the ward next day and chest physiotherapy commences immediately along with inhalers.

The postoperative period, if uncomplicated, is about 10-15 days before you discharge the patient home.

Microsurgical reconstruction of the trachea and esophagus

26

Peirong Yu, MD, FACS

Professor, Department of Plastic Surgery
MD Anderson Cancer Center, Houston, TX, USA

The most common oncologic causes leading to tracheal resection are secondary tumors from the adjacent organs, such as thyroid, laryngeal and esophageal cancers. Tracheal reconstruction after surgical resection is difficult because of several tracheal characteristics including the rigidity needed to maintain an open lumen, an intact luminal lining, and the ability to clear secretions. Short tracheal defects (up to 2 cm) may be closed primarily. Extended resection up to 4 cm may be reapproximated with the neck

at 15 to 35 degrees of flexion and laryngeal release to minimize anastomotic tension. Additional airway mobilization and hilar release may provide another 1.4 cm of tracheal length for selected patients at a few specialized centers. However, anastomotic complications and mortality rates increase with increasing length of the defect. Defects longer than 5 or 6 cm had not been successfully reconstructed in human until recently. With our recent experiences in tracheal reconstruction, a classification system was de-

veloped to guide the reconstructive options for this difficult problem.

Type I defects

Type I defects are small enough to be closed primarily. Based on the size of the defects, they are further classified as Type Ia, less than 2 cm in length, and Type Ib, 2 – 4 cm in length.

Type Ia defects can be closed primary without further manipulations. Type Ib defects require suprahyoid laryngeal release with the neck flexed by suturing the chin to the anterior chest skin, with or without hilar mobilization. In young patients with an untreated neck and an elastic trachea, a slightly longer defect up to 5.5 cm may be closed primarily with these maneuvers. Coverage of the repair site with a pedicled pectoralis major muscle flap is recommended in patients with a compromised wound bed, such as a large dead space around the trachea, a radiated wound, or with aggressive paratracheal dissection.

Type II defects

Type II defects are greater than 5 or 6 cm that can not be closed primarily. Reconstruction of these defects had been largely unsuccessful in the past. These patients are usually considered as non-surgical candidates or require a total laryngectomy and possibly a mediastinal tracheostomy. Successful tracheal reconstruction would expand surgical indications, preserve laryngeal functions, avoid a high-risk mediastinal tracheostomy, and improve quality of life. The ultimate goals of tracheal reconstruction are to provide a non-collapsible airway with a functional epithelial lining and reliable well-

vascularized tissue coverage. The first priority is given to the non-collapsible construct.

The neotrachea consists of a thin skin flap, usually a radial forearm free flap, for lining and a prosthetic material for rigid support. The supporting material can be a Hemashield or Gore-Tex vascular graft stented with several rings of the Synthes Polymax resorbable mesh to maintain a diameter of 3 cm. The skin flap is suspended to the supporting material around it with Prolene sutures. The flap is revascularized with microsurgical techniques and the entire construct is covered with either a sternocleidomastoid or pectoralis major muscle flap. A temporary T-tube tracheostomy is performed at the end of surgery to facilitate airway cleaning and to prevent airway compromise from flap swelling. The T-tube can be removed several weeks later once airway patency is established. In patients with a compromised airway, such as subglottic stenosis, a thick flap, combined with unilateral vocal cord paralysis, the T-tube can be left in place as a permanent tracheostomy which is well tolerated in our experience. Patients are able to speak with the T-tube capped, which is a major advantage over a total laryngectomy.

Microsurgical reconstruction of the trachea is a complex procedure requiring expertise from several disciplines and meticulous postoperative care. Prompt management of complications, most commonly air leak and airway compromise, is mandatory. Contraindications include severe cardiac and pulmonary comorbidities and severely compromised laryngeal function.

Type III defects

Type III defects are those involving the tracheal stoma either from a concomitant laryngopharyngectomy (Type IIIa) or stoma recur-

rence (Type IIIb) or combined tracheal and total esophagectomy (Type IIIc). For Type IIIa defects, simultaneous reconstruction of the tracheostoma and pharyngoesophagus is best served with a two-skin island anterolateral thigh flap which provides reliable reconstruction with a single flap, superior functional outcomes and minimal donor site morbidities. For Type IIIb isolated tracheostoma defects, a pedicled internal mammary artery perforator (IMAP) flap provides a quick and simple reconstruction with predictable results. The flap is islanded based on the second intercostal perforators and designed parallel to the intercostal space, with a width of 5 to 6 cm and length 13 to 15 cm. The prognosis of patients with tracheostoma recurrence is usually poor with frequent distant metastasis at presentation and high risk of vascular rupture. Therefore complex reconstruction in this patient population should be avoided. The simple IMAP flap is particularly suitable for this purpose. For Type IIIc defects, the tracheal defect is usually reconstructed with a free ALT flap while the total esophagectomy defect is reconstructed with a supercharged jejunal flap.

Pharyngoesophageal Reconstruction

While early-stage cancers in the hypopharynx and larynx are usually treated with

radiotherapy, recurrent and advanced-stage cancers in the hypopharynx and larynx require surgical resection. Because of prior radiotherapy, primary closure of the hypopharynx after a salvage total laryngectomy often results in pharyngocutaneous fistulas, making primary closure impossible in many patients. Traditionally, free jejunal flaps have been used to reconstruct circumferential pharyngoesophageal defects to re-establish alimentary tract continuity. In recent years, however, the ALT flap has become the flap of choice for pharyngoesophageal reconstruction, offering superior functional outcomes, quicker recovery, and, because laparotomy and bowel resection are not required, fewer donor-site morbidities. Furthermore, more than 90% of patients can resume an oral diet following pharyngoesophageal reconstruction with an ALT flap. Tracheoesophageal puncture can provide intelligible speech with good voice quality.

In many patients with cancer that recurs after radiotherapy, neck dissection, or pharyngocutaneous fistula, additional surgery typically results in pharyngoesophageal and anterior neck or tracheal defects that are difficult to manage, even in the best hands. A two-skin island ALT flap combined with various amounts of vastus lateralis muscle can be used to achieve reliable single-stage reconstruction.

Perforator flaps for head and neck reconstruction

27

Peirong Yu, MD, FACS

Professor, Department of Plastic Surgery
MD Anderson Cancer Center, Houston, TX, USA

The ulnar artery perforator (uap) flap

The radial forearm flap (the Chinese flap) has become one of the most popular flaps for head and neck reconstruction. It has many advantages including robust blood supply, easy to harvest, thin and pliable skin, long vascular pedicle, and possibility of sensory reinnervation. There are some disadvantages, however, which include sacrifice of a major artery supplying the hand, the need for skin

grafting to the forearm donor site, frequent partial loss of skin grafts and tendon exposure, tendon adhesion and stiffness, sensory loss in the thenar eminence, occasional injury to the radial sensory nerve, hairy in some patients, and conspicuous scar in the distal forearm. An alternative flap in the forearm is the ulnar artery (or ulnar forearm) flap. The ulnar artery flap never gained popularity because of the traditional belief that the hand perfusion is ulnar artery dominant. More studies have shown, however, the radial ar-

tery is equally important or even radial artery dominant in some patients. Therefore, the ulnar artery flap can be safely harvested without jeopardizing the hand perfusion.

The true ulnar artery perforator flap and perforator anatomy have not been reported. The author's experience of the ulnar artery perforator flap and its perforator anatomy are described in detail.

Perforator Anatomy

One to three cutaneous perforators from the ulnar artery are present and they are designated as A, B, and C from distal to proximal. Perforator A is present in 79% of cases and located 7.3 ± 1.1 cm from the pisiform. Perforator B is present in 95% of cases and located 11.4 ± 1.0 cm from the pisiform. Perforator C is present in 87% of cases and located 15.9 ± 1.8 cm from the pisiform. All patients have at least 2 perforators, and 61% have three perforators. All A and B perforators are septocutaneous, while 10% of the C perforators are musculocutaneous, passing through a thin layer of FCU muscle. The length of the pedicle is 5.3 ± 1.6 cm from the bifurcation to the most proximal perforator included in the flap. Donor site morbidity is minor. Grip testing demonstrated a transient decrease in grip strength during the post-operative period, and most recovered to the contralateral level by 3 months.

Compared to the radial forearm flap, the advantages of the ulnar artery flap include: 1) less obvious scar in the forearm; 2) usually no sensory deficit distal to the flap; 3) less hair on the skin; 4) some donor sites can be closed primarily; 5) less or no tendon exposure; 6) skin graft take is generally better. The ulnar artery perforator flap can be used for a variety of reconstructions, similar to the radial forearm flap.

The anteromedial thigh (amt) flap

While the anterolateral thigh (ALT) flap has become the flap of choice for many soft tissue reconstructions, the anteromedial thigh (AMT) flap is less well known to most surgeons. There have been very few reports and the descriptions of vascular anatomy in the literature have been rather confusing. The author has recently studied the vascular anatomy of the AMT flap in 100 patients undergoing head and neck reconstruction. The perforator anatomy and its relationship with the ALT flap are described in detail.

Perforator Anatomy

In the 100 AMT flaps explored, 21 thighs (21%) had no cutaneous perforators. There were 96 perforators in the remaining 79 thighs. Fifty-nine of the perforators originated from the rectus femoris branch (RFB) of the descending branch of the lateral circumflex femoris artery (LCFA). The rectus femoris branch travels along the medial edge of the rectus femoris muscle or within the muscle itself and is accompanied by two venae comitantes. The other 37 perforators originated from the superficial femoral artery (SFA). The perforator near the midpoint of the AP line was designated as perforator B, the more proximal one, perforator A, and the more distal one, perforator C, similar to the ALT perforator classification.

Overall, 39 of the 59 RFB perforators (66%) were septocutaneous, traveling in the intermuscular space between the rectus femoris and the sartorius/vastus medialis muscles. Septocutaneous courses were identified in 58%, 70%, and 64% of perforators A, B, C, respectively. All musculocutaneous perforators traverse the medial edge of the rectus

femoris muscle to reach the skin. Typically, this muscle layer is thin. None of the RFB perforators travel through the sartorius or vastus medialis muscle. The perforators originating from the RFB could be traced back to the descending branch of the LCFA, generating a long (7 to 15 cm) and sizable vascular pedicle similar to the ALT flap. Therefore, the flap based on the perforators from the rectus femoris branch should be considered the true AMT flap.

The true AMT (RFB) perforators were further analyzed. Only 51 of the 100 thighs had one (43 thighs) or two (8 thighs) perforators. Therefore, the possibility of raising an AMT flap based on the RFB existed in only 51% of cases.

Relationships of ALT and AMT Perforators

Most patients with small or no ALT perforators had a large AMT perforator (80% and 60 % respectively), while patients with large or medium ALT perforators were more likely to have medium or small AMT perforators (90% and 88%). This inverse relationship of ALT and AMT perforator size was significantly associated ($p=0.029$, Fisher's exact test). Compared to patients with medium or large ALT perforators, patients with small/no ALT perforators had about a 6-fold increased chance of having large/medium AMT perforators ($OR=6.18$, $95\%CI=1.23-30.91$, $p=0.026$).

Most patients without ALT perforators had one or more AMT perforators (20% and 60 % respectively), while most patients with three ALT perforators had no AMT perforators (76%). This inverse relationship in ALT and AMT perforator number was significantly associated ($p<0.001$, Fisher's exact test). Compared to patients with 2 or

more ALT perforators, patients with one or fewer ALT perforators had about a 4-fold increased chance of having an AMT perforator ($OR=3.77$, $95\%CI=1.34-10.65$, $p=0.012$).

Based on the clinical importance, the large, medium and small perforators were assigned a score of 6, 3 and 1, respectively. The total scores over three regions in the ALT or AMT were analyzed using a linear regression model. Lower scores of ALT perforators were significantly related to higher scores in AMT perforators (slope = - 0.33, $95\% CI= (-0.46, -0.20)$, $p<0.001$).

In conclusion, there is an inverse relationship between size and number of ALT and AMT perforators: when ALT perforators are inadequate, AMT perforators are typically useable, expanding the reconstructive options available from a single donor site through the same incision.

The internal mammary artery perforator (imap) flap

The IMAP flap was first described in the English literature in 2006 by the author for tracheostoma reconstruction. Neligan et al further conducted injection studies and reported their clinical use of this flap in 2007. More recently Dr. Saint-Cyr's group reported the three-dimensional perforator anatomy using injections and 3-D CT scan of cadaveric specimens.

Vascular Anatomy

The internal mammary artery perforators, as the name implies, originate from the internal mammary artery. The internal mammary artery itself originates from the subclavian artery and travels along the

sternal border on each side of the sternum. It becomes the superior epigastric artery in the upper abdomen and nourishes the upper part of the rectus abdominis muscle. In its path along the sternal border, the internal mammary artery sends out several perforators through the intercostal space to the chest skin.

At the level of third intercostal space, the artery has a mean diameter of about 1.9 mm and the vein, 2.5 mm in live patients. The average distance between the artery and the sternal border was about 1.5 cm.

Perfusion Territory

Based on the injection study, internal mammary artery perforators in the first intercostal space perfused to the level of the clavicle and lateral mammary fold in all cases and to the level of the xiphisternum one-third of the time. Internal mammary artery perforators in intercostal space 2 had a territory reaching the clavicle and xiphisternum in four of six cases and the lateral mammary fold in all cases. Internal mammary artery perforators in intercostal space 3 reached the clavicle in only 40 percent, the xiphisternum in 60 percent, and the lateral mammary fold in 80 percent of cases. When the superior internal mammary artery perforators were injected (intercostal spaces 1 and 2), the linking vessels were found to be orientated in a transverse fashion. However, when the inferior internal mammary artery perforators (intercostal spaces 3 to 7) were injected, the orientation of the linking vessels took a more inferolateral orientation. Therefore, the axi-ality of blood flow of the internal mammary artery perforator flap is lateral if an internal mammary artery perforator in intercostal space 1 or 2 is used and inferolat-

eral if an internal mammary artery perforator in intercostal space 3 and below is used. This is important when designing flaps.

Surgical Techniques

The internal mammary artery perforators at the second and third intercostal spaces along the sternal border on each side are examined with a handheld Doppler device. For head and neck reconstruction, the perforator at the second intercostal space is preferred as the basis of the flap because of its proximity to the neck defect. The Doppler signal can be used as a guide for perforator selection. If the Doppler signal in the second intercostal space is significantly weaker than that at the third intercostal space, the latter should be chosen. The side chosen depends on the location of the defects. For a centrally located defect, the side with a stronger Doppler signal is chosen. Once the IMAP is selected, the flap is designed with its long axis parallel to the intercostal space. The medial limit of the flap is the midline of the sternum, and the length of the flap is based on the arc of rotation needed to reach the defect with the lateral limit of the flap slightly beyond the anterior axillary fold. When the IMAP at the second intercostal space is chosen, the long axis of the flap should be horizontal. The flap design should not extend above the clavicle or extend to the deltoid region since the perfusion in these areas is unreliable.

The medial half of the superior incision is made first down to the fascia; subfascial dissection proceeds inferiorly with a pair of tenotomy scissors until the internal mammary perforator vessels are identified. The perforator vessels are dissected and the rest of the flap is incised and islanded. If needed, the pectoralis major muscle attachments cepha-

lad to the perforators are divided to increase the length of the vascular pedicle. The flap is then rotated to reconstruct the neck defect, either through a subcutaneous tunnel or by dividing the narrow skin bridge between the donor site and the neck defect. The viability of the very distal end of the flap is confirmed by active bleeding from the skin edge. The donor site is then closed primarily.

Perforators either from the lateral thoracic artery or intercostal artery may be encountered in the lateral aspect of the flap. These

perforators can be safely divided without compromising the flap perfusion. When a large flap is needed and the donor site cannot be closed primarily, a thoracodorsal artery perforator flap can be used to close the chest donor site.

When used as a free flap, the internal mammary artery and vein are dissected as the main vascular pedicle to obtain more pedicle length and larger diameter. The rib cartilage above the perforator is removed to facilitate the dissection of the internal mammary vessels.

Reconstruction of the mandible and the fibular flap

28

Peirong Yu, MD, FACS

Professor, Department of Plastic Surgery
MD Anderson Cancer Center, Houston, TX, USA

A clinical classification of mandibular defects

In order to guide mandibular reconstruction, a simple and practical classification system is created by the author (Table I).

Type I is a segmental bony defect. It is further divided into Ia and Ib according to the extent of soft tissue defect. Type II is a posterior defect or hemimandibular defect. Similarly, it is further classified as IIa and IIb based on the extent of soft tissue defect.

Management of Each Type of Mandibular Defect

Type Ia defects

Type Ia defect is typically a lateral segmental defect with an intact condyle. Because of the intact condyle and ramus, this type of defect is best reconstructed with a bone flap to maximize function. Our preferred flap is the fibular osteocutaneous flap with a skin paddle to reconstruct the intraoral soft tissue defect.

Defects	Type Ia	Type IIb	Type IIa	Type IIb
Bony defect	Segmental	Segmental	Posterior or hemi	Posterior or hemi
Condyle	Intact	Intact	Removed	Removed
Mucosal defect	Yes	Yes	Yes	Yes
External skin defect	No	Yes	No	Yes
Option 1	Fibula OS flap	2 skin island fibula or fibula OC+soleus	Fibula OC or iliac crest osteocutaneous flap	2 skin island fibula or fibula OC+soleus,
Option 2	Iliac crest or scapula	Double free flaps (FFF+ALT, FFF+RFF)	ALT with or without VL	ALT with two skin islands or one skin island ALT with VL
Option 3		FFF + pec flap		
Option 4		Remove condyle, 2 skin island ALT		

Table 1: Classification of Mandibular Defects

Type Ib defects

Because of soft tissue defects both intra-orally and externally, these defects are more difficult to reconstruct. In addition, these patients usually have long standing orocutaneous fistula and repeated episodes of osteomyelitis, resulting in severe neck fibrosis, making recipient vessel dissection extremely difficult.

Choice #1. A two-skin island fibular osteocutaneous flap.

Choice #2. One-skin island fibular osteocutaneous flap with soleus muscle and skin grafting.

Choice #3. Double free flap reconstruction.

Choice #4. Fibular osteocutaneous flap with a pectoralis major muscle or myocutaneous flap.

Choice #5. Convert to a posterior or hemimandibulectomy defect by removing the ramus and condyle and reconstruct it with a soft tissue flap.

Type II defects

In type II defects, the condyle and ramus are removed. The defect may extend all the way to

the parasymphysis although most defects end in the anterior or mid body of the mandible. Without the condyle, the importance of bony reconstruction is much lower. Bone reconstruction may minimize the jaw deviation, provide better occlusion and slightly better definition of the jaw line compared to soft tissue flap reconstruction, functional outcomes are, however, similar. In the setting of ORN, especially in the presence of infection and for through-and-through defects, reconstruction with soft tissue flaps may have fewer postoperative complications and quicker recovery.

Common bone flaps for posterior defects are the fibular flap and the iliac crest flap. The iliac crest flap may be a good option for posterior defects because of its natural shape, thus no need for osteotomies. Our preferred soft tissue flap is the anterolateral thigh flap while the rectus abdominis flap is a good alternative.

Perforator patterns of the fibular flap skin paddle

Harvesting the fibular bone flap is relatively straightforward. The difficulty is to

make the skin paddle reliable. A reliable skin paddle is crucial to simultaneously reconstruct the floor of mouth or external skin defect during mandibular reconstruction or other areas of reconstruction. Although several studies have tried to map the perforators to the fibular skin paddle, the exact locations of cutaneous perforators remain unclear. We have recently studied this in great detail and the perforator patterns are presented herein.

Perforator Anatomy

Eighty consecutive patients undergoing free fibula flap reconstruction were included in this prospectively designed study. The location, size, and type of perforators were recorded intraoperatively and mapped on the line connecting the fibular head and lateral malleolus (FHM line).

There were 46 male and 34 female patients with a total of 202 perforators. The average FHM line length was 36.1 ± 3.4 cm (male: 38.2 ± 2.2 cm and female: 34.1 ± 2.7 cm). Two discrete groups of perforators could be identified. The proximal perforator was consistently found one-third the length and 1.5

cm posterior to the FHM line. The majority of these perforators (84%) were musculocutaneous. The more clinically useful perforators to support a skin paddle are the distal ones over the third quarter of the fibula. One to three distal perforators were consistently present, grouped as perforator A, B, and C at points 0.51, 0.62, and 0.73 along the FHM line, respectively. Perforators were approximately 3.5 cm apart and 2 cm posterior to the FHLM line, and the majority (96%) were septocutaneous. If the fibula bone is divided into four segments, the distal perforators are generally located over the third quarter of the fibula. On the x-axis, the perforators are always located posterior to the FHM line. Thirty-nine patients (49%) had a single distal perforator, 29 patients (36%) had two distal perforators, and 12 patients (15%) had three perforators.

In conclusion, utilizing common anatomic landmarks, a reliable skin paddle can be designed with simplicity and confidence over the third quarter of the fibula. The proximal perforator can be useful as a second skin paddle for through-and-through reconstruction.

Contralateral C7 Transfer in Total Brachial Plexus Palsy

29

Dragos Zamfirescu, Alexandru Stoian, Andreea Bularda

Zetta Clinic Bucharest, Romania

Traumatic brachial plexus injuries are devastating, inducing paralysis and loss of sensibility in the affected limb, especially in cases of total root avulsion. This became a daily issue with fast development of high-velocity traffic.

A large proportion of brachial plexus injuries in the literature (60%) interest all five roots, causing full arm. Within the mentioned group young men are most likely to sustain these disabling injuries. Surgical reconstruction might be challenging when di-

rect nervous repair is not possible, in avulsion injuries and in prolonged denervation time which lead to irreversible atrophy of the muscle fibers, mainly in hand muscles. When proximal donor nerves are not available for repair, nerve transfers are suggested. Although debated, transferring myelinated nerve fibers from contralateral C7 nerve root to affected limb still remain a suitable surgical choice [1, 2, 3].

It has been passed more than 25 years since the world's first case of contralateral

C7 nerve transfer achieved by Gu et al. Ever since different variation of initially technique developed: C7 nerve can be used as common trunk or as individual divisions anterior/posterior (the anterior division contains more sensitive axons, while posterior one more motor axons), different recipients sites (median nerve, musculocutaneous nerve, radial nerve), different ways of bridging the gap between donor and recipient site (nerve grafts, vascularized nerve grafts) [1, 3, 4].

In case of contralateral C7 transfer, we prefer to use vascularized ulnar graft from the affected limb for filling the gap. The nerve is harvested by cutting it at the wrist level and then it is freed proximally to the upper arm. An important technical step is to spare the superior ulnar collateral vessels to preserve an important vascularization source for the upper segment of ulnar nerve. After the initial surgery the patient has to wear a head-shoulder spica for 4 weeks for preventing nerve suture rupture. In the second stage, when the regenerated nerve from the contralateral C7 reached the axilla of affected limb (clinical – positive Tinel sign, electrophysiological studies), we can now pay attention to upper limb reanimation [3]. Our preferred method is free functional muscle transfers (gracilis muscle) due to chronic patients without locally resources.

Regarding the postoperative complications of the donor site level, after transection of contralateral C7, one systematic review identified that the majority of patients (74%) suffered sensory abnormalities and 98% of them recovered within 3 months. Compared with sensory disturbances, the motor functional morbidity was experienced less frequently (20%) and a big percent of patients (91%) succeeded to recover the motor deficit within 6 months [5].

Next we will present a case of complete brachial plexus paralysis and the way we managed it.

Our patient is a 33 years old male who suffer a motorcycle accident in 2012. As a result of this high velocity trauma, on admission the patient level of consciousness was 3 on Glasgow coma scale (severe brain injury), he had bilateral costal fractures, hemopneumothorax. The surgical team performed a splenectomy, reconstructed the left subclavian artery using and synthetic graft and stabilize the humeral fracture with an external fixator. Furthermore he developed mediastinitis. As it can be seen, we are talking about a critical ill patient.

9 months after the acute trauma, the plastic surgery team realized a nerve transfer (three intercostal nerves to musculocutaneous nerve) but it proved to be unsuccessful due to a left femur osteitis which stopped the patient rehabilitation program.

4 years after the initial accident we have the same patient with a complete brachial plexus paralysis and our objective was to restore the patient elbow flexion. Firstly we harvested the ipsilateral vascularized ulnar nerve (*Figure a*), performed a subcutaneous tunnel up to contralateral C7, then behind the scalenic muscles we carefully dissected the nervous roots of C5-C7. After the surgical team transected the anterior division of the middle trunk (*Figure b*) it was performed the nervous coaptation. 6 months later when the Tinel sign reached the ipsilateral axilla, we performed a free functional muscle transfer (gracilis muscle). Motor innervation of the flap was assured by direct epineural neurorrhaphy between reversed vascularized ulnar nerve and anterior branch of obturator nerve. At the moment our patient is enrolled in a specific rehabilitation program, where

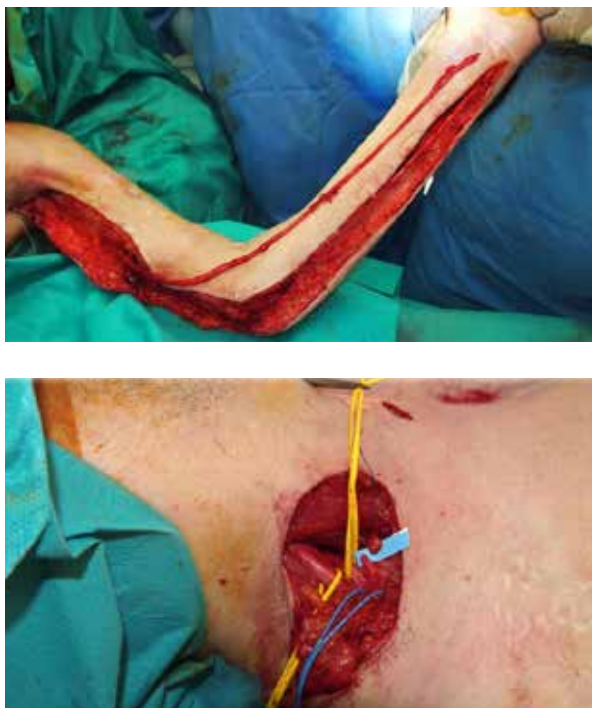


Figure 1: a) ipsilateral vascularized ulnar nerve dissected and prepared for transfer; b) red arrow – reversed vascularized ulnar nerve, green arrow – anterior division of the middle trunk

positive signs as slightly contraction of the transferred muscle were observed.

In comparison with adult brachial plexus

injury, there is in literature a lack of reports regarding the use of contralateral C7 transfer in infants with obstetrical brachial plexus avulsion. Two studies showed that the previous technique has reliably good outcomes [6].

We performed a nervous transfer between contralateral C7 and median nerve from the affected limb using a sural nerve graft, to recover 13 month old infant sensibility, wrist and fingers flexion. Previously (5 months before), our patient suffered a series of nervous transpositions and transfers targeting the musculocutaneous nerve.

As conclusion, the contralateral C7 nerve transfer is considered a controversial option with potential issues as: It can be done? It works well enough to justify the risk? Independent function can be relearned in adults? Regarding the large clinical experience of Asian surgeons during last decades and our personal cases, we recommend this technique as safety and efficient in treatment of brachial plexus palsy.

REFERENCES

1. Yang G, Chang KW-C, Chung KC. A Systematic Review of Outcomes of Contralateral C7 for the Treatment of Traumatic Brachial Plexus Injury: Part 1-Overall outcomes of contralateral C7 transfer for traumatic brachial plexus injury. *Plast Reconstr Surg*. 2015 Oct;136(4):794–809.
2. Songcharoen P, Wongtrakul S, Mahaisavariya B, Spinner RJ. Hemi-contralateral C7 transfer to median nerve in the treatment of root avulsion brachial plexus injury. *J Hand Surg Am*. 2001 Nov;26(6):1058–64.
3. Zhang C-G, Gu Y-D. Contralateral C7 nerve transfer - Our experiences over past 25 years. *J Brachial Plex Peripher Nerve Inj*. 2011 Nov 23;6:10.
4. Wang S, Yiu H-W, Li P, Li Y, Wang H, Pan Y. Contralateral C7 nerve root transfer to neurotize the upper trunk via a modified prespinal route in repair of brachial plexus avulsion injury. *Microsurgery*. 2012 Mar;32(3):183–8.
5. Yang G, Chang KW-C, Chung KC. A Systematic Review of Outcomes of Contralateral C7 for the Treatment of Traumatic Brachial Plexus Injury: Part 2-Donor-site morbidity of contralateral C7 transfer for traumatic brachial plexus injury. *Plast Reconstr Surg*. 2015 Oct;136(4):480e–489e.
6. Lin H, Hou C, Chen D. Contralateral C7 transfer for the treatment of upper obstetrical brachial plexus palsy. *Pediatr Surg Int*. 2011 Sep 1;27(9):997–1001.

Dragos Zamfirescu, Alexandru Stoian, Andreea Bularda

Zetta Clinic Bucharest, Romania

The fingertip is anatomically defined as the part of the finger distal to flexor and extensor tendons insertion into the distal phalanx [1]. Fingertip amputations were described by Tamay, Hirase, Allen and so on. However, Tamai classification is used more frequently. The zone I extends from the base of the nail to the distal tip, and zone II from the distal interphalangeal joint to base of the nail [1, 2].

When referring to evaluation and treatment of fingertip amputation, an intimate

understanding of fingertip anatomy is mandatory. The overlying skin is anchored to the periosteum of distal phalanx through fibrous septa, giving the rise to the pulp. The blood vessels have an intimate anatomic relationship to the fibrous septa and at this level Grayson and Cleland ligaments do not surround the neurovascular bundles. The two palmar digital arteries often join at the midline, forming the pulp arcade at the level of lunula, the site where terminal branches come from and lie in a deep plane adjacent

to the periosteum [3]. Moreover, a recently published study by Nam et al. focus on different types of arterial vascularization in Tamai zone I [2]. The veins are found in volar and dorsal locations and reside in the subcutaneous tissue just beneath the dermal layer [3].

Regarding the nature of the injury can be identified three major mechanisms: clean-cut due to a sharp object with no loss of the tissue and minimal crushing, crush-cut resulting from a blunt object with some loss of tissue and crush-avulsion as a result of severe crushing and avulsion [4].

Although technically difficult, Komatsu and Tamai reported the first successful replantation in 1968. In the past hand surgeons avoided replantation of the fingertip due to technical challenges and because of doubts regarding the final results. Reconstructive methods as local or island flaps, secondary healing, thenar pocketing have led to problems such as cold intolerance, joint stiffness, hyper/hyposensitivity. However, advances in the field of microsurgery instruments and techniques allowed assuring a success rate of replantation between 80-90% in hands of an experienced microsurgeon [2].

Moving forward, we want to share my expertise regarding distal phalanx replantation, some "how I do it" advices.

In all cases, the surgery was performed under digital block and a tourniquet to the base of the phalanx was used to create a bloodless field. Firstly, we made the bone fixation and then the anastomosis of the artery was accomplished using 11/0 or 12/0 Prolene simple interrupted sutures (*Figure a,b,c*). In contrast to the veins, arteries have a thicker wall and do not collapse so easily.

The tourniquet was released to observe venous return, however, in most cases a vein for anastomosis was not seen instantly, so

we choose to take a break between 30 and 60 minutes. In the cases where the amputation was proximally to the base of the nail (Tamai zone II), while waiting for the venous filling, we performed nervous coaptation. Otherwise, the digital nerve do not need to be forcibly sutured in zone I, due to the spontaneous recovery that can be expected.

After 30 minutes of delay the venous diameter increased by up to 1 mm or more, making it much easier to locate the vein. Delayed venous repair was described by Koshima in 2005 and involved two surgeries and a waiting time of 18 to 24 hours.

Despite standing by only 30 minutes, we were able to achieve the same results.

Venous anastomose was initiated by finding the lateral veins, next put the smallest vascular clamp on the distal expanded vein. All the treated fingers were drained by direct venous anastomoses or using vein grafts harvested from proximal stump, within a small longitudinal incision (3 to 5 mm). Five or six stitches were used for each vein anastomosis. Although it was difficult to achieve a proper matching between distal and proximal veins, we obliquely interposed in some cases vein grafts for having a proper drainage from the amputated part (*Figure d*).

Finally the skin was closed using two or three simple Prolene 5/0 interrupted stitches, without pressure on the repaired vessels.

At the fingertip level arterial anastomosis can be done by an experienced microsurgeon, but the most frequent cause of replantation failure is venous congestion due to technical difficult veins anastomosis. Repetitive venesection, external bleeding through fish-mouth incisions, nail bed removal and medical leeches, all can become frustrating for the patient. A plausible and simple solution for previous problems is delayed venous

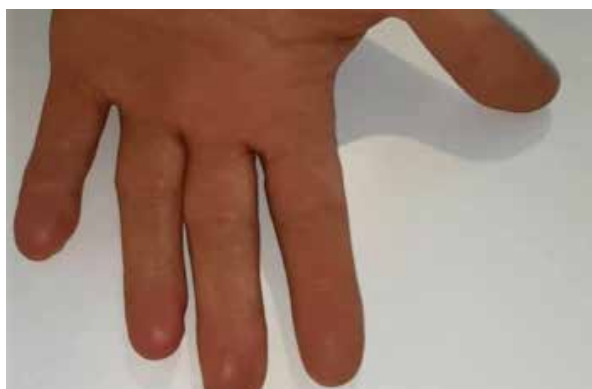
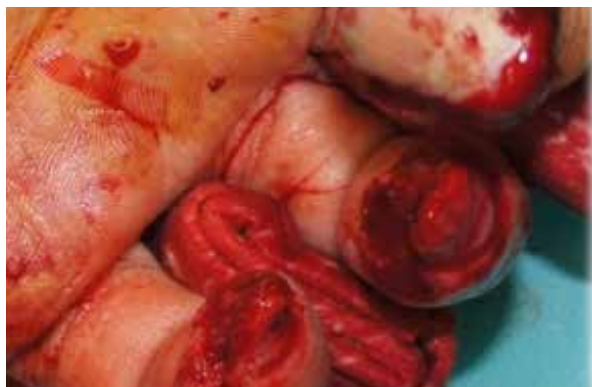
Figure 1: a) Case 3 - fingertip amputations
Figure b) Case 3 - postop result 3th, 4th and 5th digit preop aspect

repair (30-60 minutes), which enhances the subdermal veins diameter and makes the suturing technique feasible (*Figure a, b*) [5].

As final remarks we want to bring in attention a systematic review by Sebastin et al., who pointed some facts about outcomes in distal digital replantation:

- the overall survival rate of distal digital amputation (86%) is similar to more proximal replantations (80-90%)
- it is a big difference in outcome between clean-cut amputations and crush-avulsion, however no difference between crush-cut and crush-avulsion ones
- vein repair significantly improved the survival rate in both zone I and II replantations
- nerve repair is therefore not essential in distal replantations
- almost 70% of distal replantations cited were reported from centers in the Orient (Confucian moral values, maintaining body integrity?) [4].

REFERENCES

1. Venkatramani H, Sabapathy SR. Fingertip replantation: Technical considerations and outcome analysis of 24 consecutive fingertip replantations. *Indian J Plast Surg.* 2011;44(2):237-45.
2. Nam YS, Jun YJ, Kim I-B, Cho SH, Han HH. Anatomical Study of the Fingertip Artery in Tamai Zone I: Clinical Significance in Fingertip Replantation. *J Reconstr Microsurg.* 2017 Jan;33(1):45-8.
3. Kim J-S, Yang J-W, Lee D-C, Ki S-H, Roh S-Y. Challenges in Fingertip Replantation. *Semin Plast Surg.* 2013 Nov;27(4):165-73.
4. Sebastin SJ, Chung KC. A Systematic Review of the Outcomes of Replantation of Distal Digital Amputation. *Plast Reconstr Surg.* 2011 Sep;128(3):723-37.
5. Zamfirescu D, Salman M, Lascar I. Delayed venous repair for distal phalanx replantation. *J Reconstr Microsurg.* 2012 Nov;28(9):603-6.

Dragos Zamfirescu, Alexandru Stoian, Andreea Bularda

Zetta Clinic Bucharest, Romania

Large bone defects can be reconstructed using autogenous or homologous bone grafts [1]. Using this methods will result a prolong time for bone integration, atrophy after bone union leading eventually to fracture and implant failure. One potential explanation is the incomplete neovascularization of the graft, which leads to a mixture of necrotic and viable bone with lower strength. Vascularized bone graft could be a viable solution for previous listed problems, due to combination of viability of cancellous

with the stability brought by cortical graft. All this are sustained by an intact nutrient blood supply [2, 3].

Free vascularized fibular grafts (VFG) are a viable method of reconstruction of bone gaps larger than 6 cm in patients who associates soft-tissue defects (crushing injuries or tumor resection) [4]. Moreover autologous fibula grafting is not a target for immunoreactive mechanisms, which can negatively influence the integration of the bone graft [5, 6, 7].

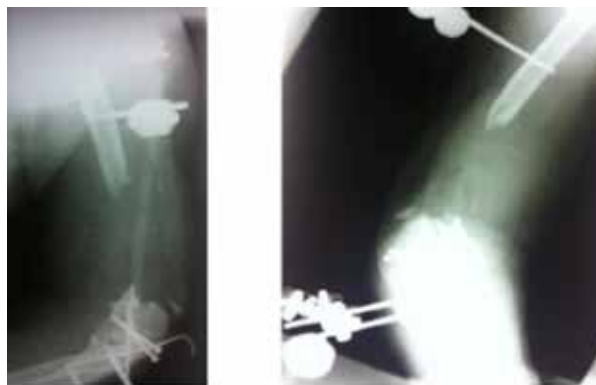

Figure 1a: Radiologic aspect of humeral fracture with massive bone loss and external fixation

VFG proved to be a solid choice of treatment in large bone defects, but it can bring a number of early and late postoperative complications. Among early complications are devascularisation of the donor leg due to fibular artery, sensitivity deficits, infections and late complications as nonunion, valgus ankle deformity, fibular fracture or osteomyelitis. Also, the donor site can suffer from transient palsy of the superficial fibular nerve and contracture of flexor hallucis longus muscle. Meticulous preoperative planning, choosing the proper vessel and type of fixation can prevent the mentioned complications [3, 8, 9].

Further, we will present two cases to highlight the versatility of VFG in reconstruction of large bone defects.

The first case is a 36 year old male patient who suffered a crushing trauma at the leg level. As result, he acquired a 6 cm bone defect at tibial diaphysis level. After healing the soft tissues, the surgical team chose VFG to fill the bone gap. Initially the peroneal artery was identified and then a composite autograft was harvested from contralateral leg, meaning a 10 x 4 cm cutaneous island along with an 11 cm of fibula (5 cm longer than the defect). After exposing the initially bone defect, anterior tibial artery and vein,

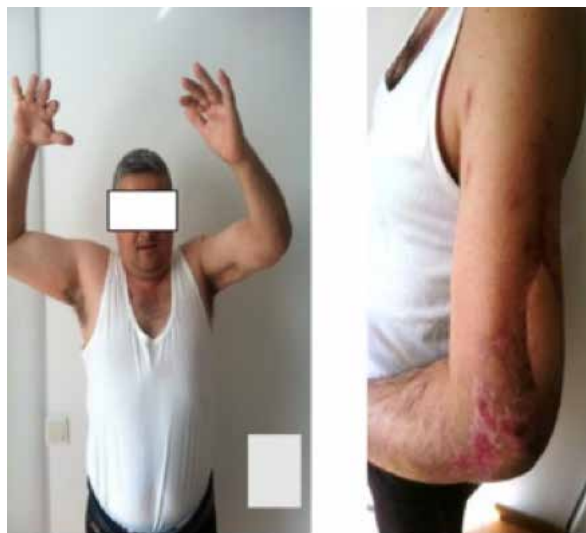

Figure 1b: b) 3 months after free fibular transfer

the orthopedic team performed the osteosynthesis with an external fixator and the plastic surgery team accomplished the vascular anastomoses. In the post operative period, the patient benefit from continuous heparin infusion with monitoring the APTT. The patency of vascular anastomoses was assessed by clinical examination and Doppler ultrasound. 18 months post operative the VFG is totally integrated and our patient is able to walk again.

The second case is a 50 years old male who suffered a crushing of the left arm resulting an open humeral fracture (III B type) with an important bone defect. Initially, the bone part was stabilized with an external fixator allowing the soft tissue time to heal (*Figure a*). Before reconstruction with VFG, the arteriography evidenced the patency of left brachial and peroneal artery. The free flap was harvested and transferred to the recipient site, the arterial anastomosis was performed in a termino-lateral fashion between peroneal and brachial arteries. 3 months postoperative the radiologic highlights the integration of fibular graft and the patient recovers

the upper arm mobility in proportion of 90% (*Figure b*).

As conclusion, patients with complex lesions, meaning bone and soft tissue defects, require an interdisciplinary approach (plas-

tic and orthopedic surgeons). In this kind of teamwork, vascularized fibular graft proved to be a highly efficient therapeutic tool, accelerating the patient discharge and integrating him to socio-professional faster.

REFERENCES

1. Malizos, K. N., Beris, A. E., Xenakis, T. A., Korobilias, A. B. & Soucacos, P. N. Free vascularized fibular graft: A versatile graft for reconstruction of large skeletal defects and revascularization of necrotic bone. *Microsurgery* 13, 182–187 (1992).
2. Hiroshi Yajima et.al. Vascularized fibular grafts for reconstruction of femur. *J Bone Surg [Br]* 1993; 75-B:123-8.
3. Tu, Y. K. et al. Reconstruction of posttraumatic long bone defect with free vascularized bone graft: good outcome in 48 patients with 6 years' follow-up. *Acta Orthop Scand* 72, 359–364 (2001).
4. Kalra, G. S., Goel, P. & Singh, P. K. Reconstruction of post-traumatic long bone defect with vascularised free fibula: A series of 28 cases. *Indian J Plast Surg* 46, 543–548 (2013).
5. Xenakis, T. H. et al. Vascularised bone grafts in the treatment of long bone defects. *Microsurgery* 15, 479–484 (1994).
6. Chen, C. M. et al. Reconstruction of extremity long bone defects after sarcoma resection with vascularized fibula flaps: a 10-year review. *Plast. Reconstr. Surg.* 119, 915–924–926 (2007).
7. Erni, D., De Kerviler, S., Hertel, R. & Slongo, T. Vascularised fibula grafts for early tibia reconstruction in infants with congenital pseudarthrosis. *J Plast Reconstr Aesthet Surg* 63, 1699–1704 (2010).
8. Minami, A., Kasashima, T., Iwasaki, N., Kato, H. & Kaneda, K. Vascularised fibular grafts. An experience of 102 patients. *J Bone Joint Surg Br* 82, 1022–1025 (2000).
9. Iamaguchi, R. B., Fucs, P. M. M. B., da Costa, A. C. & Chakkour, I. Vascularised fibular graft for the treatment of congenital pseudarthrosis of the tibia: long-term complications in the donor leg. *Int Orthop* 35, 1065–1070 (2011).

Improving the Results of Muscle Transplantation for Facial Reanimation

32

Ronald M. Zuker, MD, FRCSC, FACS

Plastic and Reconstructive Surgeon
The Hospital for Sick Children, Toronto, Canada
Professor of Surgery
The University of Toronto

The results of facial reanimation surgery have improved dramatically in recent years. This has in large measure been due to improved surgical techniques that focus on refinements in achieving better motor input and better muscle positioning and stability. In this brief document, I will outline how I think facial reanimation surgery and particularly muscle transplantation can be optimized.

In muscle transplant surgery, a segment of the gracilis muscle from the thigh is trans-

planted to the face. The gracilis is used as it facilitates a two team approach and has an excellent neurovascular set up. The transplanted muscle is carefully positioned in the face and then revascularized. Microvascular anastomoses to the facial artery and vein is usually done, although the superficial temporal vessels can be used. After revascularization, the muscle is reinnervated by coapt- ing the nerve to the gracilis to the selected donor motor nerve (in my practice this is usually a cross face nerve graft or the mo-

tor nerve to masseter). After the muscle is secured in position, the area is thoroughly irrigated, the cheek flap is replaced and a post auricular Penrose drain is positioned. Only light activity is permitted for the first 2 days, then gradual increased ambulation and discharge from hospital on day 4 or 5 post surgery. Rehabilitation exercises are initiated after the muscle begins to function (8 weeks if the motor nerve to masseter is used or 20 weeks if a cross face nerve graft is used). These exercises are meant to increase commissure excursion, achieve as symmetrical a smile as possible, and produce a degree of spontaneity when a nerve other than the facial nerve is utilized.

A fundamental requirement for successful muscle transplantation in facial reanimation surgery is an adequate motor nerve. This can be either a cross face nerve graft in the younger patient with minimal facial droop, or it can be the motor nerve to masseter in the older patient, or the patient with a significant facial droop. In order to augment the power of the cross face nerve graft to achieve adequate commissure excursion, I have found it critical to firstly use a substantial branch of the facial nerve on the normal side. This should be an appropriate branch that leads to contraction of the zygomaticus major and minor muscle, and there should also be an alternate branch for ongoing innervation of the normal side. In addition to selecting a substantial branch of the facial nerve on the normal side, back dissection of this branch into the parotid gland for even 5 to 6 mm leads to increased axon density and also better visualization of the facial nerve branch for easier microcoaptation. In the laboratory, it has been demonstrated that intraoperative stimulation can lead to improved muscle function. This has been con-

firmed in clinical studies in upper extremity surgery. Thus, currently we stimulate the facial nerve, either before or after coaptation of the selected branch to our sural nerve graft, for one hour at 20 Hertz. We also have learned in the laboratory that coaptation of the distal end of the cross face nerve graft to a small branch of a sensory nerve may maintain the activity of the Schwann cells and thus also improve muscle function. This is a fairly simple adaptation and may prove to be quite helpful. Lastly, we use a short graft which courses from the mid cheek region on the normal side to the upper buccal sulcus on the affected side. The proximal part of the sural nerve, that is to say the segment in the upper calf, is utilized as our graft, as this is thin and provides for increased axon density. This proximal segment is also an excellent size match to both the selected branch of the facial nerve at the time of cross face nerve grafting, and to the motor nerve to gracilis at the time of muscle transplantation. With these techniques, we feel that an increased innervation to the transplanted muscle can be achieved, resulting in greater excursion.

When the motor nerve to masseter is used, it does innately provide adequate innervation for excellent excursion. However, if taken too proximal it may lead to excessive excursion so it needs to be used as its site of trifurcation within the muscle itself. In this way we have to have as symmetrical a reconstruction as possible.

At the time of muscle transplantation, there are also several technical details that must be adhered to. Firstly, the muscle must be placed in the correct position. We assess the location of muscle insertion and vector of movement on the normal side and try to replicate this on the affected side. Not only must the muscle be positioned correctly, it

must be fixed securely. In order to accomplish this, we use a row of mattress sutures along the edge of the gracilis muscle that is to be inserted into the commissure and upper lip, and use this to lock the anchoring sutures in position (*Figure 1*). The placement

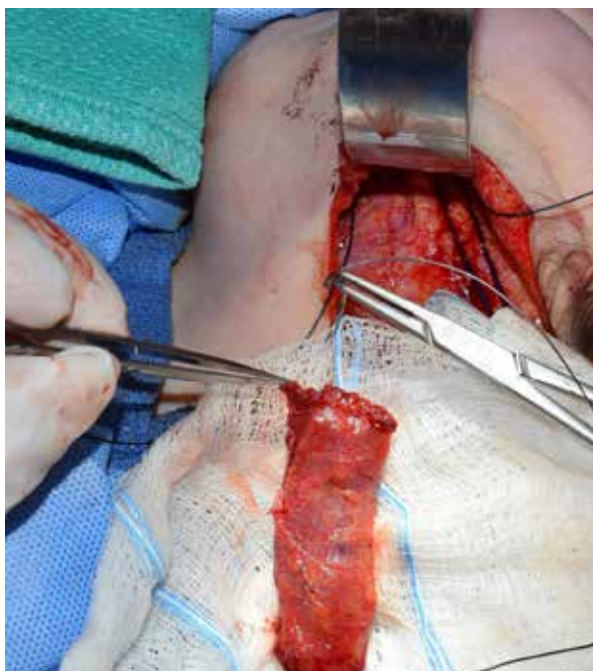


Figure 1: Technique used to anchor the muscle at the commissure and upper lip with secure fixation behind a row of mattress sutures

of the anchoring sutures at the oral commissure and upper lip is critical to have a natural appearing nasolabial crease. This is perhaps the most difficult part of the muscle transplant procedure and the most important to get exactly right. The muscle is secured as indicated and placed in the appropriate vector in the desired vector in the cheek. It is anchored proximally to the temporal fascia (not the zygomatic arch). In this way we can get a longer muscle, providing for longer muscle fiber length. We feel that this then translates into increased excursion of the commissure and a more natural smile. It is important to not have excessive bulk. For this reason, I use only about one third of the

circumference of the gracilis muscle (*Figure 2*) and also remove the buccal fat pad and some subcutaneous fat. Removal of the fat pad also facilitates the dissection of the facial vein and artery which we use preferentially to revascularize our gracilis muscle trans-

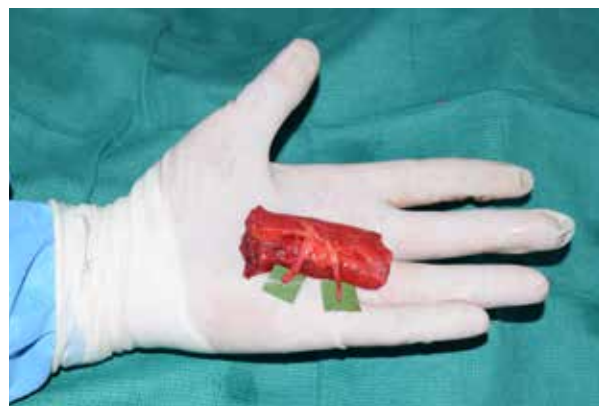

Figure 2: Selected segment of the gracilis for transplantation. One third of the circumference and the length of the commissure to the root of helix plus one centimeter on each end for suturing.

plant. As outlined earlier, using a strong motor nerve is important to achieve adequate commissure excursion. This can be either the cross face nerve graft with the technical augmentations discussed earlier or the motor nerve to masseter. Lastly, the muscle must be under the correct tension when anchored between the oral commissure and upper lip and the temporal fascia. The appropriate tension should place the commissure on the affected side even with the commissure on the normal side, and just barely move the corner of the mouth. These technical details are imperative to follow if one is to achieve adequate muscle excursion and a natural appearing smile.

Facial reanimation surgery continues to evolve. The technical tips outlined in this document have assisted me in improving the overall results and the overall satisfaction of our deserving patients.

TECHNICAL TIPS & TRICKS FOR RECONSTRUCTIVE MICROSURGERY
HOW I DO IT

Prvo izdanje, 2018. godina

Izdavač

ZAVOD ZA UDŽBENIKE
Beograd, Obilićev venac 5
www.zavod.co.rs

Likovni urednik

Aida Spasić

Grafički urednik

Boris Popović

Dizajn i priprema

Jelena Stevanović

Korektura

Autori

Obim: 71 štamparskih tabaka

Format: 20,5 × 28,5 cm

Rukopis predat u štampu 2017. godine.

Štampanje završeno 2017. godine.

Štampa